

UC Irvine

UC Irvine Previously Published Works

Title

Effects of anteroinferior capsulolabral incision and resection on glenohumeral joint reaction force.

Permalink

<https://escholarship.org/uc/item/8dw5s025>

Journal

Journal of rehabilitation research and development, 39(4)

ISSN

1938-1352

Authors

McMahon, Patrick J
Eberly, Vance C
Yang, Bruce Y
[et al.](#)

Publication Date

2014-11-21

Peer reviewed

Effects of anteroinferior capsulolabral incision and resection on glenohumeral joint reaction force

Patrick J. McMahon, MD; Vance C. Eberly, MD; Bruce Y. Yang, BS; Thay Q. Lee, PhD

Orthopaedic Biomechanics Laboratory, Long Beach Department of Veterans Affairs Medical Center, Long Beach, CA; Department of Orthopaedic Surgery, University of California, Irvine, CA; Department of Orthopaedic Surgery, University of Pittsburgh, PA

Abstract—Successful outcome of a Bankart procedure depends on knowledge of the effects of capsulolabral lesions on joint biomechanics. The joint reaction force, through “concavity compression,” is integral to glenohumeral stability. In this study, we applied loads to the tendons of the rotator cuff and deltoid (anterior and middle portions) of five cadaver upper limbs. The joint reaction force was measured with a 6° of freedom load cell for the intact condition and each of two test conditions: (1) incision and (2) partial resection of the anteroinferior capsulolabrum. We used analysis of variance to compare joint reaction forces resolved into that which is directed perpendicular (compression force), anterior, and superior to the glenoid. Compression force for the two different capsulolabral lesions of the glenohumeral joint was the same, $133 \text{ N} \pm 13 \text{ N}$, a small 12% decrease compared to the intact condition ($151 \text{ N} \pm 13 \text{ N}$). This difference was not statistically significant. Results were similar for the components of the joint reaction force directed anterior and superior. Joint reaction force was not meaningfully altered after anteroinferior capsulolabral lesions were simulated. Because glenohumeral joint stability involves complex interplay of static and dynamic restraints, additional shoulder injuries may be necessary for the joint reaction force to be abnormal.

Key words: *Bankart, cadaver, instability, joint reaction force, shoulder.*

INTRODUCTION

The goal in treating glenohumeral instability is not only to eliminate pain but is also to restore normal function. Today's knowledge of shoulder anatomy, biomechanics, and operative techniques has yielded low rates of recurrent instability after treatment [1–6]. Yet, return to normal function, gauged by the ability to return to the same level of sporting activities, remains inadequate [1,7]. Difficulty in treatment is complicated by an enormous range of shoulder mobility that necessitates less bony stability than at other diarthrodial joints.

Soft tissues, including the capsulolabral structures, are vital to guide and limit shoulder motion. The Bankart lesion that occurs after anterior glenohumeral dislocation is an injury of the anteroinferior capsulolabral structures [8,9]. It includes the glenoid insertion site of the anterior band of the inferior glenohumeral ligament (IGHL), important in preventing anterior joint dislocation [10]. Yet, simulation of a Bankart lesion in prior biomechanical studies demonstrated anterior glenohumeral subluxation but not dislocation [11,12]. Testing was done in the apprehension position of abduction, external rotation, and horizontal abduction because anterior dislocation occurs in this shoulder position. In these studies, a force

This material was based on work supported by the Department of Veterans Affairs, Rehabilitation Research and Development Service.

Address all correspondence and requests for reprints to Patrick J. McMahon, MD, Assistant Professor; University of Pittsburgh, 3500 Water Street, Pittsburgh, PA 15203; 412-432-3650; email: mcma-honp@msx.upmc.edu.

external to the glenohumeral joint was applied to the humeral head and translation of the humeral head was measured. However, only rarely does *in vivo* dislocation result from such an external force, as from the hand of another individual being applied to the posterior shoulder. Instead, it occurs for example, in the game of basketball when a shot is blocked and the upper limb is pushed back into the apprehension position, beyond the normal range of motion. This mechanism was prior simulated with a dynamic shoulder apparatus that included simulation of active shoulder muscles [13]. The glenohumeral joint was placed in the apprehension position, with no force external to the joint being applied to the humeral head. However, this also failed to yield joint dislocation when the Bankart lesion was simulated. Division of the entire joint capsule, including both the anterior and the posterior aspects yielded dislocation but in only two of the nine joints studied [13].

We hypothesized that active shoulder muscles would result in an abnormal joint reaction force after simulated capsulolabral lesions. In addition, with the joint in the apprehension position, this would be a sensitive finding of instability, being abnormal regardless of the position of the humeral head on the glenoid. Thus, the purpose of this study was to compare change in the joint reaction force between the intact condition and after simulated capsulolabral lesions.

MATERIALS AND METHODS

We used five fresh frozen entire upper limbs from human cadavers without evidence of a rotator cuff tear or other joint disease (mean age 77.5 ± 6.4 years). A longitudinal incision was made in the skin from the anterolateral corner of the acromion to the insertion of the deltoid. The muscles of the anterior and middle portions of the deltoid were resected and the tendons were preserved. The rotator cuff muscles were also resected from the scapula to expose their tendons. Other glenohumeral joint soft tissue was carefully preserved, and those with evidence of arthritis or rotator cuff tearing were excluded. All joints distal to the glenohumeral were then rigidly fixed. The wrist and each of the digits were fixed in extension and the elbow was fixed in 90° of flexion with stainless steel threaded pins.

The scapula was positioned with the glenoid surface parallel to the medial border of a custom box and fixed

with plaster of Paris. We then mounted it onto a custom joint loading frame that enabled individual control of simulated muscles as well as the measurement of joint reaction force (resolved into three forces along the three orthogonal axes) (**Figure 1**). The upper limbs were kept moist by irrigation with saline during preparation and testing. Next, we clamped the tendons of the rotator cuff (subscapularis, supraspinatus and, infraspinatus and teres minor muscles) and the deltoid (anterior and middle portions) and used a pulley and cable system to simulate the action of these muscles as prior studies have shown each to be important in glenohumeral abduction [14–18]. The infraspinatus and teres minor muscles were combined because they have similar direction and function. The direction of each rotator cuff muscle force vector was defined as the line from the tendon insertion to the centroid of the muscle [19]. This resulted in an anatomic force vector for each muscle. The anterior portion of the deltoid was defined as that anterior to the anterolateral corner of the acromion, and the middle portion was defined as that between the anterolateral and the posterolateral corners of the acromion. The direction of the anterior portion of the deltoid force was defined as the line from the anterior lateral corner of the acromion to the anterior third of the deltoid tendon insertion on the

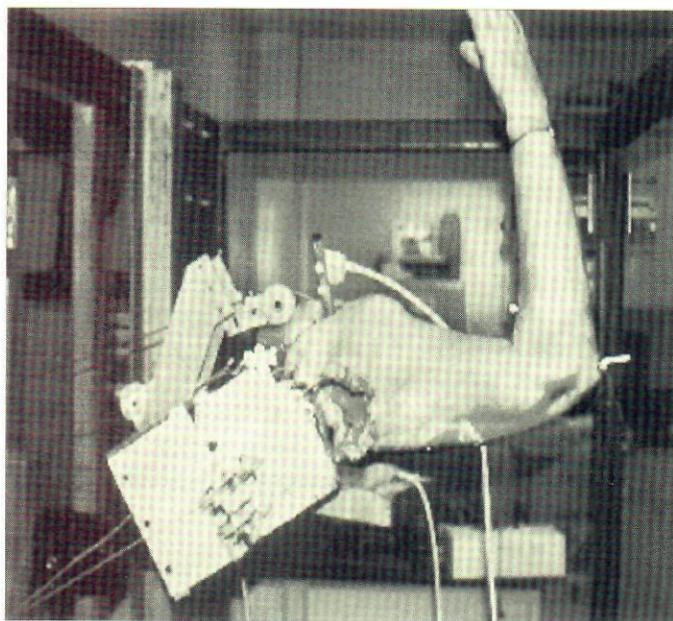

Figure 1.

Upper limb attached to custom joint loading frame in apprehension position, resulting from application of muscle forces with use of a cable and pulley system.

humerus. The direction of the middle portion of the deltoid force was defined as the line from the point midway between the anterolateral and posterolateral corners of the acromion to the middle third of the deltoid tendon insertion.

We applied equal load to each of the subscapularis and the infraspinatus-teres minor tendons to balance the anterior-posterior force couple. Then we applied the same load to the supraspinatus tendon. The ratio of load applied to the supraspinatus and the deltoid may vary and still result in full glenohumeral abduction [18]. For simplicity, we applied a load equal to that applied to each rotator cuff tendon and to each of the anterior and middle portions of the deltoid. This ratio of muscle loads was similar to that of prior studies [17,18].

In the intact condition, we abducted the scapula 30° and then simultaneously applied loads to the tendons of the simulated muscles to achieve 60° of glenohumeral abduction in the plane of the scapula. A prior study detailed the loads that were necessary to achieve this 90° position of shoulder abduction [18]. As in this study, these loads varied slightly because of differences in the weight and length of the upper limbs. Once the upper limb was stable in this position, we applied a continuous minimal load of 100 g to the wrist. This gently placed the glenohumeral joint in both external rotation and horizontal abduction and simulated gentle positioning of the shoulder into apprehension (**Figure 2**). The humeral head was free to move with 6° of freedom during testing. After the joint was cycled into this position 10 times to minimize viscoelastic effects, we recorded the position of the humerus with an electromagnetic tracking device (model 6DFOB, Ascension technology, Colchester, Vermont). We fixed one sensor rigidly to the proximal humerus on the medial margin of the bicipital groove and attached a second to the acromion to ensure the scapula did not move. The transmitter was positioned anterolateral to the joint (**Figure 3**). Metal from the jig was positioned at least 20 cm from the sensor and the transmitter. In our testing environment, the accuracy of the electromagnetic tracking device was 0.2 mm and 0.2° . External rotation and horizontal abduction followed glenohumeral abduction to simulate the same gentle apprehension positioning that was measured with the electromagnetic tracking device, as in the intact condition for each of the simulated capsulolabral lesions. We then measured the joint reaction force using a 6° of freedom load cell (model Theta, Assurance Technologies, Garner, North Carolina) that

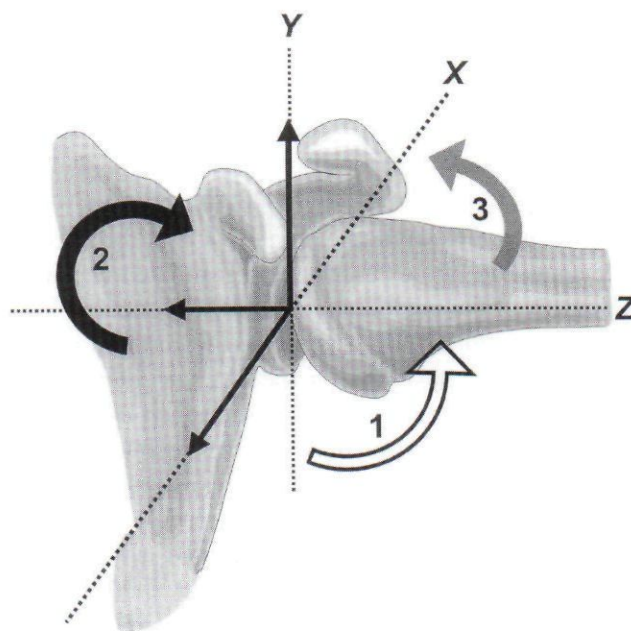


Figure 2. Schematic of shoulder motions described in this study: 1. abduction, 2. external rotation, and 3. horizontal abduction.

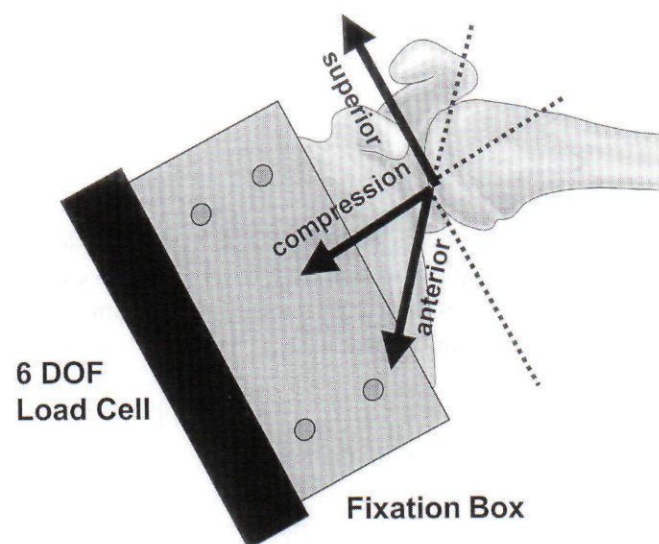


Figure 3. Schematic of glenohumeral joint on custom joint loading frame simulating apprehension position. Joint reaction force was measured with a 6° of freedom load cell. Joint position was monitored with an electromagnetic tracking device, with one sensor rigidly attached to humerus and other to scapula. DOF = degrees of freedom.

could measure up to 1,500 N and 240 N•m. In our testing environment, accuracy of this cell was 5 N and 1 N•m. The glenohumeral joint reaction force was resolved into three orthogonal components: (1) force perpendicular to the glenoid (compression force), (2) force-directed anterior to the glenoid (anterior-directed force), and (3) force-directed superior to the glenoid (superior directed force).

Once we measured the joint reaction force in the intact condition, we examined two simulated capsulolabral lesions of the glenohumeral joint sequentially. In the first, the glenoid labrum was incised from the 3 o'clock to the 6 o'clock positions on the anterior glenoid bone (incised capsulolabrum). This also detached the adjacent capsuloligamentous structures. In the second, a 5-mm portion of the labrum and adjacent capsuloligamentous structures were additionally resected (resected capsulolabrum). For each of the two simulated capsulolabral lesions, external rotation and horizontal abduction followed glenohumeral abduction. This was kept within 3° of the same gentle apprehension position as the intact condition as measured with the electromagnetic tracking device. We performed analysis of variance to compare the joint reaction force (of the three orthogonal axes) of each of the three conditions. We also compared joint loading between the three conditions to assess consistency in testing. A *p* value of 0.05 was used as the level of significance.

RESULTS

Joint Loading

We applied a mean load of 93 N ± 9 N to the deltoid (anterior and middle portions) and 47 N ± 3 N to each of the tendons of the rotator cuff muscles. It was similar for each of the three conditions.

Joint Forces

In the intact condition, the magnitude of the compression force was 151 N ± 13 N. For each of the simulated capsulolabral lesions, the compression force was the same, 133 N ± 13 N, and only 12 percent decreased compared to the intact condition (**Figure 4(a)**). This difference was not statistically significant. In addition, no statistically significant difference was found between the three conditions for either the anterior- or superior-directed forces. Specifically, in the intact condition, the magnitude of the anterior-directed force was 28 N ± 12 N,

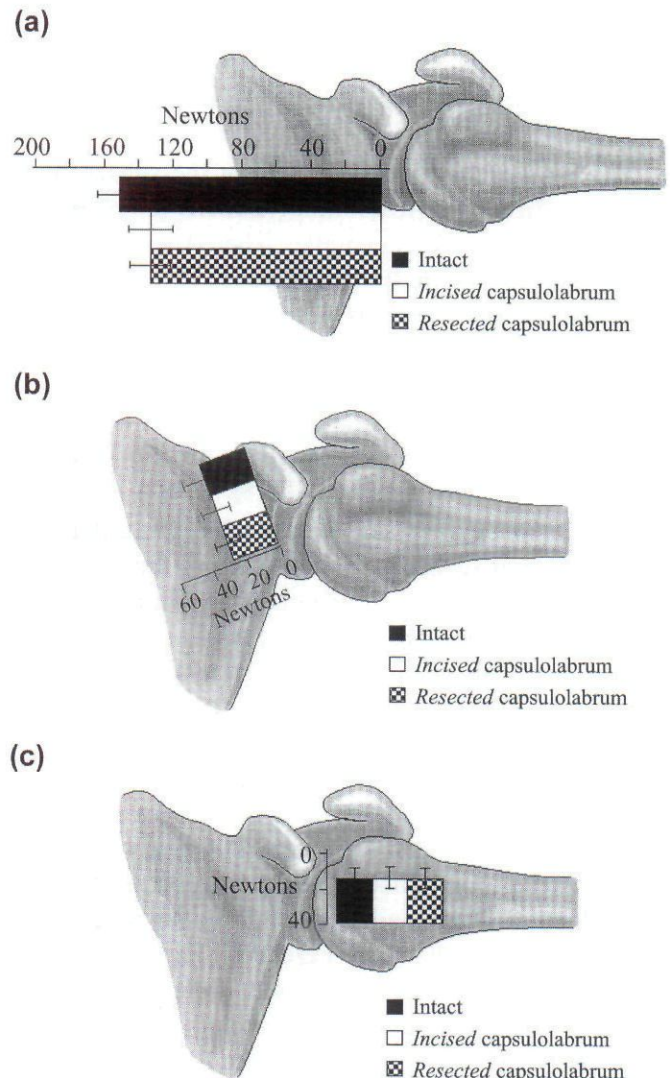


Figure 4. (a) Compression, (b) anterior-directed, and (c) superior-directed forces for intact, incised capsulolabrum, and resected capsulolabrum conditions.

the incised capsulolabrum was 27 N ± 8 N, and the resected capsulolabrum was 26 N ± 8 N (**Figure 4(b)**). In the intact condition, the magnitude of the superior-directed force was 25 N ± 5 N, the incised capsulolabrum was 26 N ± 6 N, and the resected capsulolabrum was 26 N ± 6 N (**Figure 4(c)**). Additional glenohumeral joints were not tested because post hoc power analysis indicated that a minimum of 20 glenohumeral joints would be required to demonstrate differences in the compression force in comparison of the intact condition and either of the two simulated capsulolabral lesion conditions. Over a

thousand glenohumeral joints would be required to demonstrate differences in the anterior- or superior-directed forces.

DISCUSSION

We found no change in the joint reaction force after incision or resection of the anteroinferior capsulolabrum from the glenoid. This was the case even with the joint in the vulnerable apprehension position when the anterior band of the IGHL had its most meaningful stabilizing function [10]. The reasons that this occurred were not studied, but they include the powerful stabilizing effect of the shoulder muscles, pathoanatomy that is more complex after dislocation than simulated by incision or resection of the anteroinferior capsulolabrum, and finally, inadequate modeling of glenohumeral instability.

Because of their orientation to the glenohumeral joint, muscles that move the shoulder contribute to anterior joint stability through "concavity compression." Coined by Lippett and coworkers, this term refers to the component of the joint reaction force that acts perpendicular to the glenoid fossa, compressing the humeral head [20]. Concavity compression was prior reported as being important in maintaining anterior joint stability at the mid-range of shoulder motion when the static restraints are lax [20,21]. While it is unclear if the static or dynamic restraints of a combination are responsible for stability in the apprehension position, concavity compression may also be important at end ranges of motion [22]. In this position, the muscle forces that maintained the joint in abduction were large, so concavity compression was also large [18]. Prior biomechanical studies of simulated shoulder muscle weakness demonstrated the force to dislocate the joint was diminished [23,24]. Also, there was interplay between the active posterior rotator cuff muscles and the anteroinferior static restraints [25]. This supports rehabilitation that includes rotator cuff and deltoid muscle strengthening in treatment of glenohumeral instability.

This study further demonstrated that the precise joint pathoanatomy after anterior dislocation remains unknown. Although capsulolabral lesions are common after anterior joint instability and techniques including their repair are frequently successful in eliminating anterior joint dislocation, injury to the static restraints is more complex than that simulated by incision or resection of the anteroinferior capsulolabrum [6,26,27]. Prior biomechanical studies

demonstrated only a small increase in anterior joint translation, consistent with subluxation, after incision of the anteroinferior capsulolabrum [11,12]. Proponents of the "circle theory" have argued posterior capsulolabral injury occurs with dislocation. Additionally, because the humeral head translates inferior in addition to anterior with anterior joint dislocation, there may be injury as well to the anterosuperior structures, restraints to inferior translation [28]. The anteroinferior capsulolabrum may also stretch in addition to its avulsion from the glenoid [11,29,30]. While stretching was not evaluated in this study, absence of anteroinferior capsulolabral structures from the glenoid to the humerus would be the extreme of stretching for biomechanical study. A pilot study after such resection did not result in anterior dislocation.

Other injuries may often occur to the shoulder in addition to capsulolabral lesions after glenohumeral dislocation *in vivo*. An osseous defect of the glenoid rim sometimes occurs [31]. When an anteroinferior glenoid bone defect was evaluated in a biomechanical study with a cadaver model, the humeral head translated with significantly less force in the 10 glenohumeral joints in which the width of the osseous defect was at least 21 percent of the glenoid length (average width, 6.8 mm) [32]. A large Hill-Sachs lesion of the humeral head is also known to contribute to instability [6]. Lesions of the shoulder muscles, specifically the rotator cuff, also may be factors in instability [5,33–35]. In this biomechanical study with a cadaver model, simulation of these other injuries may have resulted in an abnormal joint reaction force.

While cadaver models have been effective in study of simulated joint injuries, such models fail to recreate the synergy of joint stabilizing systems that are present *in vivo*. Joint proprioception contributes to stability, mediated by joint mechanoreceptors by initiating muscle activity [37]. This feedback coordinates the shoulder muscles [38,39]. If there is a capsulolabral lesion, the afferent pathway of the neuromuscular control remains intact, but it may fail in initiating the muscles [40,41]. Concavity compression is then diminished, and this is important even in the apprehension position as demonstrated in this study. Cadaver models also simplify complex muscle behavior as a single line of action from the centroid of the muscle to the tendon insertion and fail to include many shoulder muscles (such as those that have origin on the thorax) that may contribute to stability [17,18]. Finally, this cadaver model used a mechanism of gentle joint placement in the apprehension position. This

placement simulated the apprehension test used in clinical evaluation and would be expected to yield less alteration in both joint reaction force and joint translation than if a force external to the shoulder had been applied to the humeral head to push it out of the glenoid fossa [42]. Prior biomechanical studies that used the latter method demonstrated only a small increase in anterior joint translation, consistent with subluxation, after simulated capsulolabral injury [11,12,43]. While increased anterior joint translation was not expected with gentle positioning in apprehension, forcible placement of the joint in the apprehension position may have demonstrated abnormality in the joint reaction force.

In this biomechanical study, simulated injury of the anteroinferior capsulolabrum, independent of other injuries to the shoulder, did not yield abnormality in the joint reaction force. Combined injury of the dynamic and static restraints should be evaluated in future biomechanical studies with cadaver models. Surgical treatment of anterior joint dislocation should restore the interactions between the dynamic and static restraints and give greater attention to shoulder injuries other than capsulolabral lesions.

REFERENCES

- Bigliani LU, Kurzweil PR, Schwartzbach CC, Wolfe IN, Flatow EL. Inferior capsular shift procedure for anterior-inferior shoulder instability in athletes. *Am J Sports Med* 1994;22(5):578-84.
- Jobe FW, Giangarra CE, Kvitne RS, Glousman RE. Anterior capsulolabral reconstruction of the shoulder in athletes in overhand sports. *Am J Sports Med* 1991; 19(5):428-34.
- Neer CS, Foster CR. Inferior capsular shift for involuntary inferior and multidirectional instability of the shoulder. A preliminary report. *J Bone Joint Surg Am* 1980; 62(6):897-908.
- Rowe CR, Patel D, Southmayd WW. The Bankart procedure: a long-term end-result study. *J Bone Joint Surg Am* 1978;60(1):1-16.
- Rowe CR, Zarins B, Ciullo JV. Recurrent anterior dislocation of the shoulder after surgical repair. Apparent causes of failure and treatment. *J Bone Joint Surg Am* 1984;66(2):159-68.
- Matsen FA, Thomas SC, Rockwood CA, Wirth MA. Glenohumeral instability. In: Rockwood CA, Matsen FA, Wirth MA, Harryman DT, editors. *The Shoulder*. 2nd ed. Philadelphia: WB Saunders Co.; 1999. p. 611-755.
- Montgomery WH, Jobe FW. Functional outcomes in athletes after modified anterior capsulolabral reconstruction. *Am J Sports Med* 1994;22(3):352-58.
- Bankart ASB. Recurrent or habitual dislocation of the shoulder joint. *Br Med J* 1923;2:1132-33.
- Perthes G. Operationen bei habitueller schulterluxation. *Deutsch Ztschr Chir* 1906;85:199-227.
- Turkel SJ, Panio MW, Marshall JL, Girgis FG. Stabilizing mechanisms preventing anterior dislocation of the glenohumeral joint. *J Bone Joint Surg Am* 1981;63(8):1208-17.
- Speer KP, Deng X, Borrero S, Torzilli PA, Altchek DA, Warren RF. Biomechanical evaluation of a simulated Bankart lesion. *J Bone Joint Surg Am* 1994;76(12):1819-26.
- Black KP, Schneider DJ, Yu JR, Jacobs CR. Biomechanics of the Bankart repair: The relationship between glenohumeral translation and labral fixation site. *Am J Sports Med* 1999;27(3):339-44.
- Apreleva M, Hasselman CT, Debski RE, Fu FH, Woo SL-Y, Warner JJP. A dynamic analysis of glenohumeral motion after simulated capsulolabral injury. *J Bone Joint Surg* 1998;80A(4):474-80.
- Alpert SW, Pink MM, Jobe FW, McMahon PJ, Mathiyakom W. Electromyographic analysis of deltoid and rotator cuff function under varying loads and speeds. *J Shoulder Elbow Surg* 2000;9(1):47-58.
- Basmajian J. *The upper limb*. In: *Muscles Alive*. 4th ed. Baltimore: Williams and Wilkins; 1974. p. 189-212.
- Colachis S, Strohm B, Brechner V. Effects of axillary nerve block on muscle force in the upper extremity. *Arch Phys Med Rehabil* 1969 Nov;50:647-54.
- Debski RE, McMahon PJ, Thompson WO, Woo SL, Warner JJ, Fu FH. A new dynamic testing apparatus to study glenohumeral joint motion. *J Biomech* 1995; 28(7): 869-74.
- McMahon P, Debski D, Thompson W, Warner J, Woo S-Y, Fu F. Shoulder muscle forces and tendon excursions during scapular plane abduction. *J Shoulder Elbow Surg* 1995; 4(3):199-208.
- Klein A, McKernan D, Harner C, Davis P, Fu F. A study of rotator cuff force vectors across the glenohumeral joint using magnetic resonance imaging. *Trans Orthop Res Soc* 1989;14:230.
- Lippett S, Vanderhooft J, Harris S, Sidles J, Harryman D, Matsen F. Glenohumeral stability from concavity-compression: A quantitative analysis. *J Shoulder Elbow Surg* 1993;2(1 Pt 1):27-34.
- Warner JJP, Caborn DNM, Berger R, Fu FH, Seel M. Dynamic capsuloligamentous anatomy of the glenohumeral joint. *J Shoulder Elbow Surg* 1993;2(3):115-33.
- Lee S-B, Kim K-J, O'Driscoll SW, Morrey BF, An K-N. Dynamic glenohumeral stability provided by the rotator

- cuff muscles in the mid-range and end-range of motion: A study in cadavera. *J Bone Joint Surg* 2000;82A(6):849–58.
23. Blasler R, Guldberg R, Rothman E. Anterior shoulder stability: Contributions of rotator cuff forces and the capsular ligaments in a cadaver model. *J Shoulder Elbow Surg* 1992;1(3):140–50.
 24. Itoi E, Kuechle DK, Newman SR, Morrey BF, An KN. Stabilising function of the biceps in stable and unstable shoulders [published erratum appears in *J Bone Joint Surg Br* 1994 Jan;76(1):170]. *J Bone Joint Surg Br* 1993;75(4):546–50.
 25. Cain PR, Mutschler TA, Fu FH, Lee SK. Anterior stability of the glenohumeral joint. A dynamic model. *Am J Sports Med* 1987;15(2):144–48.
 26. Arciero RA, Wheeler JH, Ryan JB, McBride JT. Arthroscopic Bankart repair versus nonoperative treatment for acute, initial anterior shoulder dislocations. *Am J Sports Med* 1994;22(5):589–94.
 27. Arciero RA, St. Pierre P. Acute shoulder dislocation. Indications and techniques for operative management. *Clin Sports Med* 1995;14(4):937–53.
 28. Warner JJP, Deng X-H, Warren RF, Torzilli PA, O'Brien SJ. Superior-inferior translation in the intact and vented glenohumeral joint. *J Shoulder Elbow Surg* 1993;2(2):99–105.
 29. Bigliani LU, Pollock RG, Soslowky LJ, Flatow EL, Pawluk RJ, Mow VC. Tensile properties of the inferior glenohumeral ligament. *J Orthop Res* 1992;10(2):187–97.
 30. Ticker JB, Bigliani LU, Soslowky LJ, Pawluk RJ, Flatow EL, Mow VC. Inferior glenohumeral ligament: Geometric and strain-rate dependent properties. *J Shoulder Elbow Surg* 1996;5(4):269–79.
 31. Aston JW, Gregory CF. Dislocation of the shoulder with significant fracture of the glenoid. *J Bone Joint Surg* 1973;55A:1531–33.
 32. Itoi E, Lee S-B, Berglund LJ, Berge L, An K-N. The effect of a glenoid defect on anteroinferior stability of the shoulder after Bankart repair: A cadaveric study. *J Bone Joint Surg* 2000;82A:35–46.
 33. Symeonides P. The significance of the subscapularis muscle in the pathogenesis of recurrent anterior dislocation of the shoulder. *J Bone Joint Surg* 1972 Aug;54-B(3):476–82.
 34. Sonnabend DH. Treatment of primary anterior shoulder dislocation in patients older than 40 years of age. Conservative versus operative. *Clin Orthop Rel Res* 1994(304):74–77.
 35. Neviaser RJ, Neviaser TJ, Neviaser JS. Concurrent rupture of the rotator cuff and anterior dislocation of the shoulder in the older patient. *J Bone Joint Surg* 1988;70(A):1308–11.
 36. Neviaser RJ, Neviaser TJ, Neviaser JS. Anterior dislocation of the shoulder and rotator cuff rupture. *Clin Orthop* 1993;291:103–6.
 37. Vangness CT, Ennis M, Taylor JG, Atkinson R. Neural anatomy of the glenohumeral ligaments, labrum, and subacromial bursa. *J Arthrosc Rel Res* 1995;11(2):180–84.
 38. Lephart SM, Pincivero DM, Giraldo JL, Fu FH. The role of proprioception in the management and rehabilitation of athletic injuries. *Am J Sports Med* 1997;24:130–37.
 39. Warner JP, Lephart S, Fu FH. Role of proprioception in pathoetiology of shoulder instability. *Clin Orthop* 1996;330:35–39.
 40. Tibone JE, Fechter J, Kao JT. Evaluation of a proprioception pathway in patients with stable and unstable shoulders with somatosensory cortical evoked potentials. *J Shoulder Elbow Surg* 1997;6(5):440–43.
 41. Lephart SM, Warner JP, Borsa PA, Fu FH. Proprioception of the shoulder in normal, unstable and surgical individuals. *J Shoulder Elbow Surg* 1994;3:371–81.
 42. Jobe FW, Tibone JE, Jobe CM, Kvitne RS. The shoulder in sports. In: Matsen FA, Rockwood CA, editors. *The Shoulder*. Philadelphia: WB Saunders Co.; 1991. p. 961–90.
 43. O'Brien SJ, Schwartz RS, Warren RF, Torzilli PA. Capsular restraints to anterior-posterior motion of the abducted shoulder: A biomechanical study. *J Shoulder Elbow Surg* 1995;4(4):298–308.

Submitted for publication December 18, 2000. Accepted in revised form August 29, 2001.