

UC Davis

Dermatology Online Journal

Title

Purple patches in an immunocompromised patient: a report of secondary disseminated cutaneous mucormycosis in a man with chronic lymphocytic leukemia

Permalink

<https://escholarship.org/uc/item/8cm6m764>

Journal

Dermatology Online Journal, 23(3)

Authors

Iyengar, Sanjana
Chambers, Cindy J
Millsop, Jillian W
[et al.](#)

Publication Date

2017

DOI

10.5070/D3233034288

Copyright Information

Copyright 2017 by the author(s). This work is made available under the terms of a Creative Commons Attribution-NonCommercial-NoDerivatives License, available at <https://creativecommons.org/licenses/by-nc-nd/4.0/>

Peer reviewed

Purple patches in an immunocompromised patient: a report of secondary disseminated cutaneous mucormycosis in a man with chronic lymphocytic leukemia

Sanjana Iyengar¹, Cindy J Chambers¹, Jillian W Millsop¹, Maxwell A Fung^{1,2}, and Victoria R Sharon³

Affiliations:¹Department of Dermatology, University of California, Davis, Sacramento, California ²Department of Pathology, University of California, Davis, Sacramento, California ³ Department of Dermatology, Hofstra Northwell School of Medicine, New Hyde Park, New York

Corresponding Author: Victoria Sharon, MD, DTMH, Assistant Professor of Dermatology, Director of Dermatologic Surgery and Dermato-Oncology, Department of Dermatology Northwell Health, Hofstra School of Medicine, 1991 Marcus Ave, Suite 300, New Hyde Park, NY 11040, Tel: 516-719-3376

Abstract

A 60-year-old man with chronic lymphocytic leukemia developed a deeply violaceous annular patch with a halo of erythema on the right thigh during hospitalization for neutropenic fever. Associated symptoms included chronic cough and fatigue. Bilateral lung opacities with hilar lymphadenopathy were noted on chest computed tomography scan. Punch biopsy and tissue culture confirmed a diagnosis of secondary disseminated cutaneous mucormycosis. Although rare, physicians should include mucormycosis in the differential diagnosis of purpuric patches in immunosuppressed patients. Prompt skin biopsy and tissue culture may optimize the success of treatment.

Keywords: disseminated mucormycosis, primary cutaneous mucormycosis, secondary cutaneous mucormycosis

Introduction

Cutaneous manifestations of hematogenously disseminated mucormycosis, by fungi of the Mucorales order, predominantly affect immunocompromised patients. Diabetes mellitus, hematologic malignancies, and hematopoietic stem cell transplants are often linked with disseminated disease with a prevalence of 36%, 17%, and 5%, respectively [1]. Invasive fungal infections predominantly affect the pulmonary (60%) and integumentary (12%) systems [2].

Zygomycetes are found in decaying vegetation and soil and release a large number of spores [3]. Sources of infection include inhalation (most commonly), percutaneous inoculation, and ingestion of spores. Unlike other filamentous fungi, which more frequently disseminate hematogenously from other organs to skin, it is rare for systemic mucormycosis to spread to the skin [4]. According to a review by Roden et al., out of 220 patients with hematogenously disseminated infection, only 6 (3%) demonstrated secondary cutaneous involvement. Conversely, primary cutaneous infection had a 20% incidence of dissemination from skin to other organs. Additionally, mortality rates differ between localized cutaneous and disseminated infection at rates of 10% and 94%, respectively [4]. In an analysis of 25 patients seen at an institution, primary cutaneous mucormycosis had a much more favorable prognosis compared to disseminated disease from a non-cutaneous source of infection [5]. Herein, we present a patient with

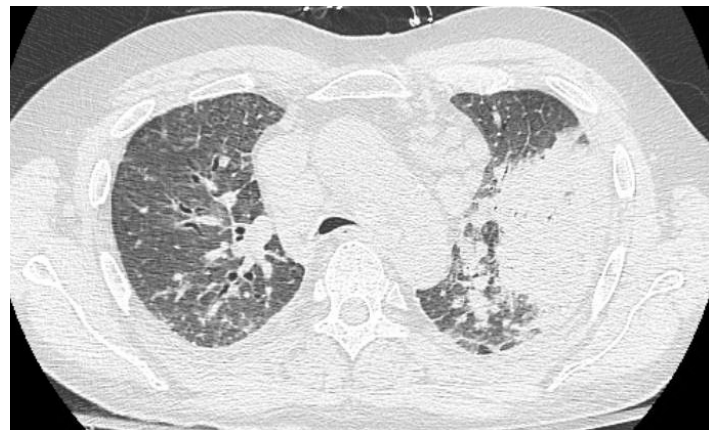

Figure 1. Bilateral lung opacities with associated lymphadenopathy seen on chest CT

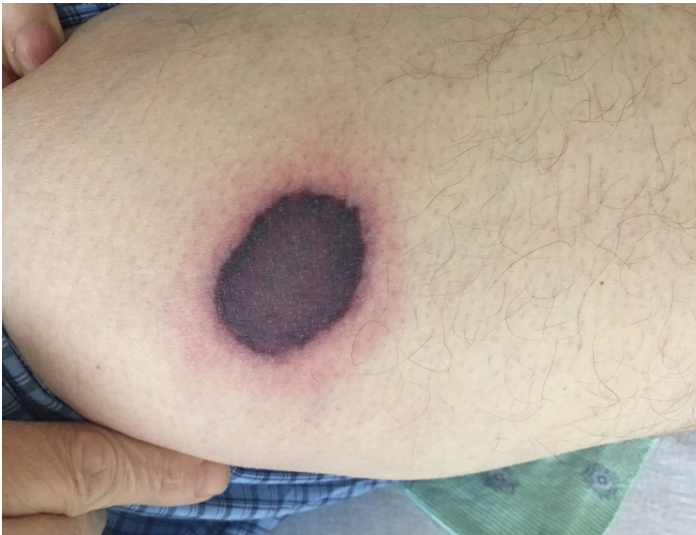

Figure 2. *Violaceous circular patch with a halo of erythema on the right thigh.*

secondary cutaneous hematogenously disseminated mucormycosis from a primary pulmonary source.

Case Synopsis

A 60-year-old man with chronic lymphocytic leukemia complicated by neutropenia presented to the hospital with a chronic cough and one week of fever and fatigue. Bilateral lung opacities with associated hilar lymphadenopathy were seen on chest computed tomography scan (**Figure 1**). On admission, broad-spectrum antibiotics and voriconazole were initiated for coverage of presumptive pneumonia related to bacteria or aspergillus infection in the setting of neutropenia, respectively. On examination, the patient was well-appearing with a deeply violaceous

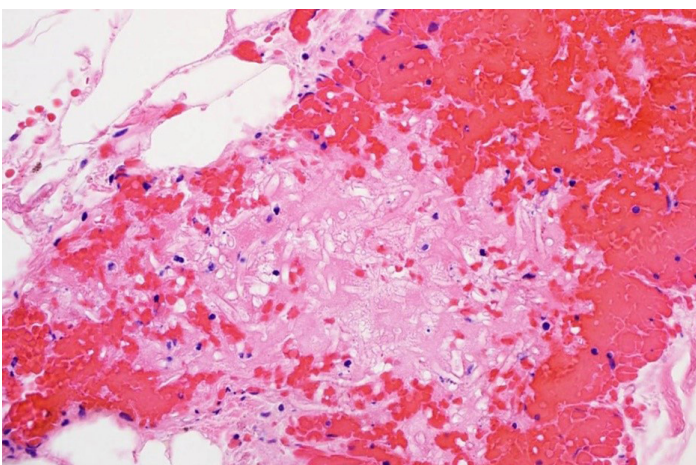


Figure 4. *Punch biopsy of the thigh revealing thrombosed dermal and subcutaneous vessels and plump non-septate hyphae with right angle branching. H&E 400x.*

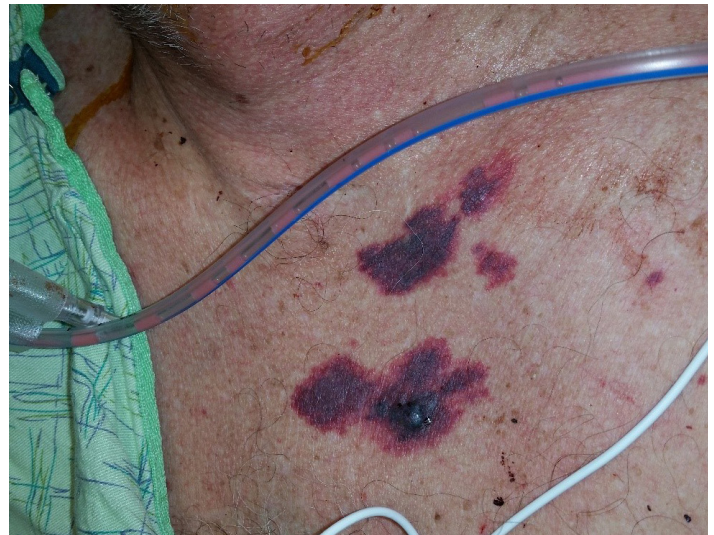

Figure 3. *Purpuric patches with an erythematous halo on the chest with one patch demonstrating bulla formation due to necrosis.*

circular patch with a halo of erythema on the right thigh (**Figure 2**).

Past medical history revealed pulmonary emboli from deep venous thromboses for which he was taking warfarin. Two days after admission, the patient developed additional purpuric patches on the chest (**Figure 3**).

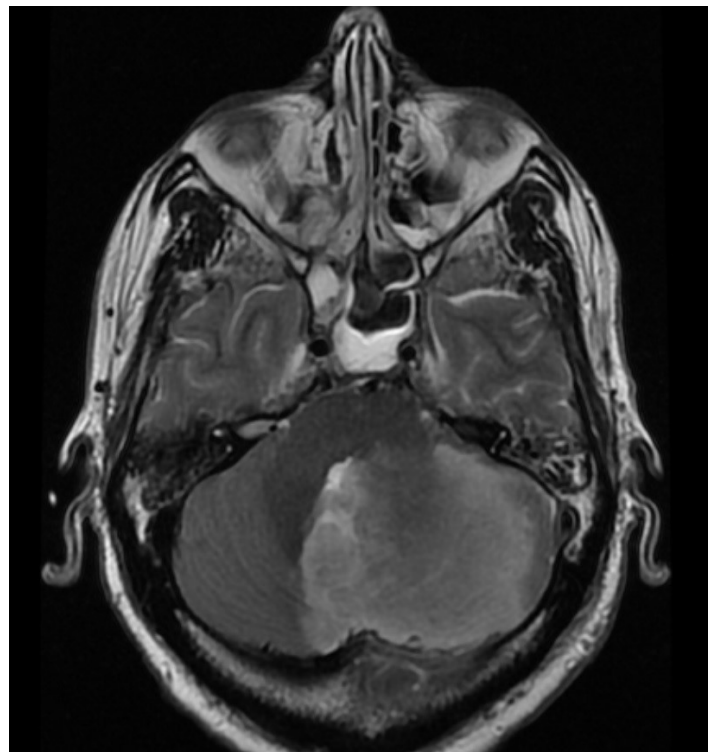


Figure 5. *Left cerebellar infarct due to fungal emboli seen on MRI.*

Table 1: Summary of Reported Cases of Secondary Cutaneous Mucormycosis

| Case No. | Age/ Gender | Immunocompromised | Cutaneous Location | Organism | Treatment | Clinical Course | First Author |
|----------|----------------|---|---|-------------------------------|---|--------------------|--------------------------------|
| 1 | 16/F | Yes; T-cell ALL | Left elbow | <i>Mycoclados corymbifera</i> | Liposomal Amphotericin B 15 mg/kg, Posaconazole 200 mg every 6 hours | Death | Schofield, et al. ⁷ |
| 2 | 20/F | Yes; Acute Lymphoblastic Leukemia | Abdomen | <i>Mucor pusillus</i> | None due to rapid progression and death | Death | Kramer, et al. ¹⁰ |
| 3 | 54/F | Yes; Acute Myelogenous Leukemia | Trunk, Thigh, Abdominal Flank, Palm, Finger, Nose | <i>Mucoral</i> , unknown type | Amphotericin B, unknown dosage | Death | Peñas, et al. ¹¹ |
| 4 | 45/M | Yes; AML, neutropenia | Abdomen | <i>Rhizomucor</i> sp. | Liposomal Amphotericin B unknown dosage, G-CSF | Death | Hocker, et al. ⁶ |
| 5 | 58/M | Yes; Acute Granulocytic Leukemia | Heel, Chest | <i>Mucor pusillus</i> | Rifampin (900 mg/day), Isoniazid (300 mg/day), Carbenicillin Disodium 5 g every 4 hours IV, Oxacillin (1.5 gm) every 6 hours, Gentamicin (40 mg) every 6 hours (for presumed <i>Pseudomonas</i> infection; no antifungal therapy due to post-mortem diagnosis of <i>Mucor</i>) | Death | Meyer, et al. ⁹ |
| 6 | 60/M | Yes; CLL | Thigh, Chest | <i>Rhizopus</i> spp | Liposomal Amphotericin B 2 doses of 3 mg/kg/day followed by 500 mg IV daily | Death | Current Case |
| 7 | 65/M | Yes; Acute Respiratory Distress Syndrome with High-Dose Steroid Therapy | Lower Extremity | <i>Absidia corymbifera</i> | Methylprednisolone 2mg/kg/day; Piperacillin/Tazobactam 4.5g every 8 hrs | Death | Geisen M, et al. ⁸ |

Abbreviations: ALL- acute lymphoblastic leukemia, AML- acute myeloid leukemia, CLL- chronic lymphocytic leukemia

A skin biopsy for histology and culture was performed. Histopathology of a punch biopsy from the thigh revealed thrombosed dermal and subcutaneous vessels filled with erythrocytes and plump non-septate hyphae with right-angle branching suggesting a diagnosis of mucormycosis (**Figure 4**). Skin tissue culture confirmed *Rhizopus* spp.

Liposomal amphotericin B and micafungin were initiated. However, the patient expired three days later in the setting of an acute left cerebellar infarct related to fungal emboli and acute respiratory failure (**Figure 5**).

Case Discussion

Reports indicate the incidence of mucormycosis has increased in recent decades [4]. It is the third most common invasive mycosis after candidiasis and aspergillosis in patients with hematologic malignancy [1]. A summary of reported patients with secondary cutaneous mucormycosis associated with disseminated disease is reported in **Table 1**. Clinical signs include targetoid plaques, patches, or bullae with purpuric centers. Diagnosis is challenging as these cutaneous lesions have a broad differential diagnosis. The differential diagnosis of purpuric patches in an immunosuppressed patient includes aspergillosis, ecthyma, ecthyma gangrenosum, fusariosis, mucormycosis, nocardiosis, and warfarin necrosis.

Mucormycosis is an invasive and potentially life-threatening infection [4]. The Mucorales most commonly involved are *Rhizopus*, *Lichtheimia*, and *Mucor* species with *Rhizomucor*, *Saksenaea*, *Cunninghamella*, and *Apophysomyces* being less common [1]. Although many types of infections exist, such as rhinocerebral, pulmonary, cutaneous, gastrointestinal, and disseminated, sinus infections are the most common at 39% [4]. Of patients with mucormycosis, diabetes is the most commonly associated underlying condition (36%) compared to malignancy (17%). However, mortality rates in patients with mucormycosis are lower among those with associated diabetes (44%) versus underlying malignancy (66%). Nineteen percent of patients with mucormycosis had no underlying medical problems but had a mortality rate of 35%.

Cutaneous mucormycosis can be subdivided into primary and secondary types [6]. Primary cutaneous mucormycosis results from direct inoculation, often related to trauma, in exposed individuals. Secondary cutaneous mucormycosis results from hematogenous dissemination from elsewhere in the body. The lung, as seen in the present patient, is the most common organ associated with dissemination [1]. In terms of treatment, surgical debridement or systemic antifungal therapy is recommended. Amphotericin B is considered the gold standard with the liposomal form being more favorable owing to its limited renal toxicity [3]. Patients treated with amphotericin B deoxycholate have an overall survival of 62%, whereas those treated with surgery had a survival rate of 57%. Combination treatment with both surgery and antifungal therapy had an increased survival rate of 70% [4]. First generation azoles, such as voriconazole, are reported to be less effective against *Zygomycetes* [6]. Second generation azoles, such as posaconazole, are superior to their first generation counterparts and are potentially as effective as liposomal amphotericin B.

Conclusion

Our patient presented with purpuric patches with erythematous halos on the thigh and chest. A diagnosis of warfarin necrosis was initially considered owing to the patient's recent history of warfarin use. However, punch biopsy and tissue culture revealed a diagnosis of secondary cutaneous mucormycosis from a primary pulmonary source, possibly from inhalation of fungal sporangiospores.

Secondary cutaneous mucormycosis is a rare condition with a high mortality rate. Skin lesions, such as purpuric patches or plaques, in an immunocompromised patient are an important clue in the early diagnosis of mucormycosis [1]. Although cutaneous dissemination is rare, a high index of suspicion and prompt skin biopsy and tissue culture are imperative to expedite appropriate therapy and reduce morbidity and mortality.

References

1. Petrikos G, Skiada A, Lortholary O, et al. Epidemiology and Clinical Manifestations of Mucormycosis. *Clin Infect Dis*. 2012 Feb;54 Suppl 1:S23-34. [PMID: 22247442]
2. Xu S, Nambudiri V, Tahan S, Seo S. Violaceous necrotic plaques on the leg of an immunosuppressed patient. *Cutaneous mucormycosis*.

- JAMA Dermatol. 2014 Jan; 150(1):79-81. [PMID: 24196118]
3. Uckay I, Chalandon Y, Sartoretti P, Rohner P, Berney T, Hadaya K, van Delden C. Invasive Zygomycosis in transplant recipients. *Clin Transplant*. 2007 Jul-Aug;21(4):577-82. [PMID: 17654724]
 4. Roden MM1, Zaoutis TE, Buchanan WL, Knudsen TA, Sarkisova TA, Schaufele RL, Sein M, Sein T, Chiou CC, Chu JH, Kontoyiannis DP, Walsh TJ. Epidemiology and outcome of zygomycosis: a review of 929 reported cases. *Clin Infect Dis*. 2005 Sep 1;41(5):634-53. [PMID: 16080086]
 5. Adam RD, Hunter G, DiTomasso J, Comerci G Jr. Mucormycosis: emerging prominence of cutaneous infections. *Clin Infect Dis*. 1994 Jul;19(1):67-76. [PMID: 7948560]
 6. Hocker TL, Wada DA, Bridges A, et al. Disseminated zygomycosis heralded by a subtle cutaneous finding. *Dermatol Online J*. 2010 Sep 15;16(9):3. [PMID: 20875324]
 7. Schofield C, Stern A, Jevtie A. Disseminated zygomycosis due to *Myocladus corymbifera* with cutaneous and cerebral involvement. *Australas J Dermatol*. 2013 Feb; 54(1):e8-11. [PMID: 23373895]
 8. Geisen M, Fodor P, Eich G, et al. Disseminated cutaneous mucormycosis in a patient on high-dose steroid therapy for severe ARDS. *Intensive Care Med*. 2011 Nov;37(11):1895-6. [PMID:21858519]
 9. Meyer RD, Kaplan MH, Ong M, Armstrong D. Cutaneous lesions in disseminated mucormycosis. *JAMA*. 1973 Aug 13;225(7):737-8. [PMID: 4515739].
 10. Kramer BS, Hernandez AD, Reddick RL, Levine AS. Cutaneous infarction. Manifestation of disseminated mucormycosis. *Arch Dermatol*. 1977 Aug;113(8):1075-6. [PMID: 268159].
 11. Peñas PF, Rios L, de la Cámara R, Fraga J, Daudén E. Cutaneous lesions as the first sign of disseminated mucormycosis. *Acta Derm Venereol*. 1995 Mar;75(2):166-7. [PMID: 7604658].