

UC Irvine

Clinical Practice and Cases in Emergency Medicine

Title

Orbital Trapdoor Fracture: An Open-and-shut Case?

Permalink

<https://escholarship.org/uc/item/8bp9q00t>

Journal

Clinical Practice and Cases in Emergency Medicine, 1(1)

Authors

Summers, Shane M

Wood, Richard M

Costello, Justin E

et al.

Publication Date

2017

DOI

10.5811/cpcem.2016.11.32397

Copyright Information

Copyright 2017 by the author(s). This work is made available under the terms of a Creative Commons Attribution License, available at <https://creativecommons.org/licenses/by/4.0/>

Peer reviewed

Orbital Trapdoor Fracture: An Open-and-shut Case?

Shane M. Summers, MD
 Richard M. Wood, DO
 Justin E. Costello, DO
 Christian L. Carlson, MD

San Antonio Military Medical Center, Department of Emergency Medicine, JBSA Fort
 Sam Houston, Texas

Section Editor: Rick A. McPheeters, DO

Submission history: Submitted September 8, 2016; Revision received November 17, 2016; Accepted November 18, 2016

Electronically published January 17, 2017

Full text available through open access at http://escholarship.org/uc/uciem_cpem

DOI: 10.5811/cpcem.2016.11.32397

[Clin Pract Cases Emerg Med. 2017;1(1):67–68.]

INTRODUCTION

A trapdoor fracture is a rare condition defined as a minimally displaced fracture of the orbital floor that has spontaneously reduced to its original position incarcerating an extraocular muscle.¹ Clinicians have described the trapdoor fracture as a “white-eyed blowout” because of a paucity of physical examination abnormalities.² Further complicating diagnosis, the injury may be radiographically occult on orbital computed tomography (CT).³ Trapdoor fractures are important for the emergency physician to identify because urgent surgical repair is recommended to reduce morbidity.

CASE REPORT

A 26-year-old man presented with binocular vertical diplopia after an assault. He denied loss of consciousness, headache, or vomiting. Physical examination revealed a Glasgow Coma Scale of 15, normal visual acuity and pupils, mild periorbital ecchymosis, and restricted right ocular motion in temporal downward gaze. There was no injection of the sclera, bony step-off, enophthalmos, or proptosis. Head and orbital CT were reported as negative for injury. A maxillary mucosal retention cyst was incidentally noted on CT (Images 1 and 2).

Ophthalmology was consulted and performed forced duction testing, which confirmed gaze restriction. The patient was taken to the operating room where a trapdoor fracture with entrapment of the inferior rectus muscle was diagnosed and surgically repaired. Retrospective review of the CT revealed that the soft tissue density misdiagnosed as a maxillary sinus cyst displayed radiodensity characteristics consistent with herniation of orbital fat and entrapped muscle fibers (Images 3 and 4).

DISCUSSION

Because of their relative bony elasticity, trapdoor fractures are reported much more frequently in children, whereas adults tend to present with readily apparent comminuted fracture patterns.⁴ However, more recent literature suggests this injury is not exclusive to pediatric patients and can occur in young adults.⁵⁻⁷ Trapdoor fractures may be missed unless extraocular

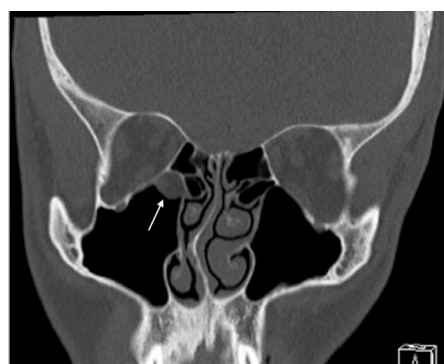


Image 1. Coronal non-enhanced computed tomography in bone window: Soft tissue density noted in the maxillary antrum and no definite fracture. Lesion initially called a mucosal retention cyst (arrow).

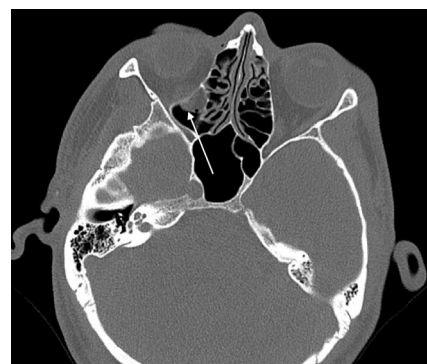


Image 2. Axial non-enhanced CT in bone window: Soft tissue density again noted in the maxillary antrum (arrow). No definite fracture.

muscles are tested through the full range of motion and close attention is paid to the location of the orbital soft tissues on CT.³ The emergency physician must consider this diagnosis in younger patients with orbital trauma and abnormal ocular motility, even with a non-diagnostic CT, because operative intervention within

24 hours is associated with improved outcomes.⁸ Reported complications of delayed surgical repair include residual gaze restriction and diplopia secondary to ischemia of the extraocular muscle.⁹

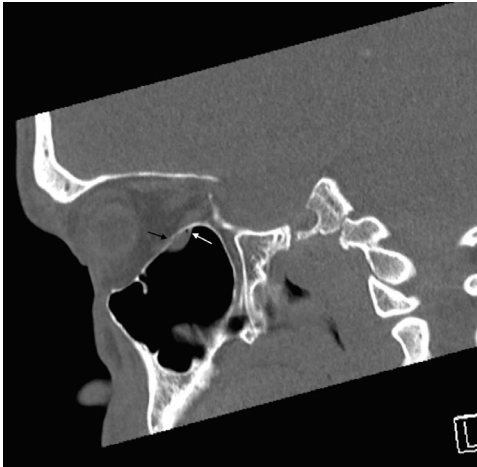


Image 3. Sagittal non-enhanced CT in bone window: Subtle defect in orbital floor (black arrow) with small focus of air adjacent to soft tissue density (white arrow).

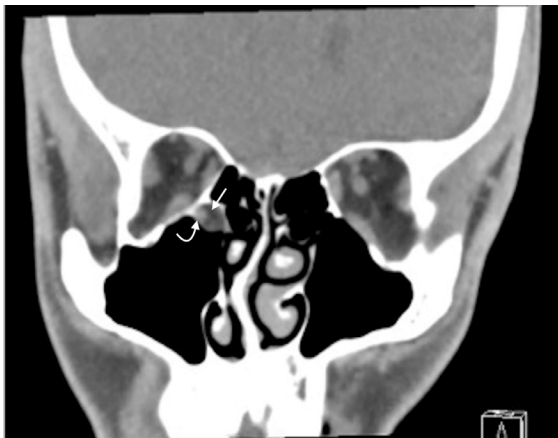

Image 4. Coronal non-enhanced CT in soft tissue window: Inferior rectus muscle (curved arrow) and orbital fat (straight arrow) in the extra-orbital maxillary antrum.

Address for Correspondence: Shane M. Summers, MD, San Antonio Military Medical Center, 3551 Roger Brooke Dr., JBSA Fort Sam Houston, TX 78234. Email: shanesummers@mac.com.

Conflicts of Interest: By the *CPC-EM* article submission agreement, all authors are required to disclose all affiliations, funding sources and financial or management relationships that could be perceived as potential sources of bias. The opinions or assertions contained herein are the private views of the authors and are not to be construed as official or as reflecting the views of the Department of the Army or the Department of Defense.

Copyright: © 2017 Summers et al. This is an open access article distributed in accordance with the terms of the Creative Commons Attribution ([CC BY 4.0](http://creativecommons.org/licenses/by/4.0/)) License. See: <http://creativecommons.org/licenses/by/4.0/>

REFERENCES

1. Phan LT, Piluek W, McCulley TJ. Orbital trapdoor fractures. *Saudi J Ophthalmol.* 2012;26(3):277-82.
2. Yew CC, Shaari R, Rahman SA, et al. White-eyed blowout fracture: diagnostic pitfalls and review of literature. *Injury.* 2015;46(9):1856-9.
3. Hopper RA, Salemy S, Sze R. Diagnosis of midface fractures with CT: what the surgeon needs to know. *Radiographics.* 2006;26:783-93.
4. Kwon JH, Moon JH, Kwon MS, et al. The differences of blowout fracture of the inferior orbital wall between children and adults. *Arch Otolaryngol Head Neck Surg.* 2005;131(8):723-7.
5. Ethunandan M, Evans BT. Linear trapdoor or "white-eye" blowout fracture of the orbit: not restricted to children. *Br J Oral Maxillofac Surg.* 2011;49(2):142-7.
6. Kum C, McCulley TJ, Yoon MK, et al. Adult orbital trapdoor fracture. *Ophthal Plast Reconstr Surg.* 2009;25(6):486-7.
7. Zavattero E, Roccia F, Benech R, et al. Orbital trapdoor fracture: can it also occur in adults? *J Craniofac Surg.* 2015;26(1):e6-8.
8. Gerbino G, Roccia F, Bianchi FA, et al. Surgical management of orbital trapdoor fracture in a pediatric population. *J Oral Maxillofac Surg.* 2010;68(6):1310-6.
9. Gerber B, Kiwanuka P, Dhariwal D. Orbital fractures in children: a review of outcomes. *Br J Oral Maxillofac Surg.* 2013;51(8):789-93.