

# UC Irvine

## UC Irvine Previously Published Works

### Title

Ontogenic study of lithium-pilocarpine-induced status epilepticus in rats

### Permalink

<https://escholarship.org/uc/item/8bj010w3>

### Journal

Brain Research, 583(1-2)

### ISSN

1385-299X

### Authors

Hirsch, E  
Baram, TZ  
Snead, OC

### Publication Date

1992-06-01

### DOI

10.1016/s0006-8993(10)80015-0

### Copyright Information

This work is made available under the terms of a Creative Commons Attribution License, available at <https://creativecommons.org/licenses/by/4.0/>

Peer reviewed

BRES 17866

## Ontogenic study of lithium–pilocarpine-induced status epilepticus in rats

E. Hirsch<sup>a,b</sup>, T.Z. Baram<sup>a</sup> and O.C. Snead III<sup>a</sup>

<sup>a</sup> Department of Neurology, University of Southern California, Division of Neurology, Childrens Hospital of Los Angeles, Los Angeles, CA 90027 (USA) and <sup>b</sup> UPR 419 Centre de Neurochimie, Strasbourg (France)

(Accepted 4 February 1992)

**Key words:** Epilepsy; Ontogeny; Pilocarpine; Lithium; Cholinergic; Seizure

Lithium is known to potentiate the ability of pilocarpine to induce status epilepticus in rats. The goal of this study was to determine whether lithium could potentiate pilocarpine-induced seizures in developing animals. Behavioral, electroencephalographic (EEG), and histopathological changes induced by systemic administration of lithium (3 meq/kg) followed 20 h later by pilocarpine (3, 10, 30, 60 mg/kg) were studied in 3–30-day-old rats. Lithium followed by pilocarpine (30 and 60 mg/kg) induced hyperactivity, tremor, loss of postural control and scratching but no electrographic seizures in 3–8-day-old rats. In the 7–10-day-old animals pretreatment with lithium and pilocarpine 60 mg/kg induced status epilepticus with sustained myoclonus and continuous bilateral synchronous spike and sharp wave, but doses of pilocarpine lower than 60 mg/kg had no effect. The susceptibility to lithium–pilocarpine-induced status epilepticus increased markedly during the third postnatal week of life. During this time period, rats treated with lithium (3 meq/kg) plus pilocarpine 10 mg/kg exhibited behavioral and EEG manifestations of status epilepticus. The same combination of lithium and pilocarpine failed to induce status epilepticus either before or after the third week of life. Histopathological analysis of the brains of the animals used in these studies failed to demonstrate the widespread damage reported in adult rats that have undergone lithium–pilocarpine-induced status epilepticus.

### INTRODUCTION

High-dose treatment with pilocarpine, a cholinergic agonist, results in sustained seizures and status epilepticus accompanied by widespread brain damage in adult rats<sup>20,21</sup>. The susceptibility of rats to pilocarpine-induced seizures and status epilepticus is age-dependent<sup>6</sup> with an adult pattern of behavioral and electrographic seizures encountered in 15–21-day-old rats, while younger animals do not exhibit overt motor seizures. Both lethality and potency of pilocarpine are increased during the third week of life relative to older and younger animals<sup>6</sup>.

In adult rats the epileptogenic effect of pilocarpine and other muscarinic cholinergic agonist is markedly potentiated by lithium<sup>8,10,11,14</sup>. Pretreatment with lithium (3 meq/kg) 24 h before pilocarpine (30 mg/kg) results in EEG and behavioral changes similar to those seen with high dose pilocarpine. We studied the

epileptogenic effect of lithium–pilocarpine during ontogenesis in rats in an attempt to determine whether lithium potentiates low doses of pilocarpine in developing animals. In addition we sought to ascertain whether younger animals were more susceptible to lithium–pilocarpine-induced status epilepticus.

### MATERIALS AND METHODS

#### *Animals*

Six timed-pregnancy Sprague–Dawley rats were obtained from Zivic-Miller, (Zelionple, PA) at the 17th or 18th gestational day. The pregnant animals were housed under a 12-h light/dark cycle, and fed ad libitum. Delivery times were monitored and were accurate to within 12 h. The day of birth was considered day zero. The pups were kept with the mothers, and litters were culled to 12 pups. The groups of animals used in these studies were mixed such that each group contained pups from several litters. The age groups studied included animals of 3–6, 7–10, 11–14, 15–21 and 22–30 postnatal days of age. These age ranges were chosen to reflect the stages of development examined in other studies of the ontogeny of experi-

mental seizures in rats<sup>3,6,18,22,23</sup>. Each pup was drug naive and subjected to lithium-pilocarpine only once.

#### Drugs

Pilocarpine hydrochloride and lithium chloride were purchased from Sigma (St. Louis, MO, USA). On the day of the experiments the drugs were freshly dissolved in saline (pilocarpine) or water (lithium chloride). Lithium (3 meq/kg) was administered intraperitoneally (i.p.) 20 h before pilocarpine which was given subcutaneously (s.c.). The volume of injection for both lithium and pilocarpine was 0.1 ml/10 g body weight. Pilocarpine was administered in doses of 3, 10, 30 or 60 mg/kg in order to determine the minimal dose required to induce continuous electrographic and behavioral seizures. There were six animals in each age group for each dose of pilocarpine used.

#### Surgery and recordings

Animals were anesthetized with halothane and placed in a neonatal rat stereotaxic frame<sup>18</sup>. Two frontal and two posteroparietal tungsten electrodes were implanted. Depth recordings were obtained from bipolar twist concentric enamel stainless steel electrodes (tip diameter 100  $\mu$ m, vertical interelectrode distance 0.5 mm) placed in the dorsal hippocampus and the nucleus accumbens. The stereotaxic coordinates for these structures were derived for each age group from the atlas of Sherwood and Timiras<sup>17</sup>. The technique allows for EEG recording from freely moving animals, via long, flexible wires<sup>18</sup>.

The surgery was well tolerated. All animals recovered with a normal righting and placing reflex within 2 h of cessation of halothane. 2 h after recovery the pups were treated with lithium chloride, observed for 1 h and returned to the mothers. 20 h later the pups were removed from the litters, baseline EEG recordings made for 30 min, and pilocarpine administered. EEG recordings were made continuously with the animals unrestrained and behavior ob-

served for periods ranging from 4 to 6 h following the s.c. administration of pilocarpine.

#### Histopathological analysis

Animals who survived seizures induced by the lithium-pilocarpine combination were sacrificed by decapitation 3 days after the administration of pilocarpine. This was chosen as an arbitrary time period to allow full recovery from the seizures. The brains were processed for pathological examination by light microscopy. 20  $\mu$ m coronal frozen sections were stained with hematoxylin and eosin and examined microscopically to ascertain the presence of brain lesions related to the seizures.

## RESULTS

### EEG

The results of these experiments are summarized in Table I. In all groups of animals treated with lithium, the baseline EEG was normal for age (Figs. 1–5).

*3–6 days* ( $n = 12$ ; Fig 1). Pilocarpine, 30 and 60 mg/kg, failed to induce seizure discharges on EEG. There were no EEG changes that correlated with the behavioral abnormalities noted above in this age group.

*7–10 days* ( $n = 12$ ; Fig 2). Pilocarpine, 30 mg/kg ( $n = 6$ ) failed to induce cortical or subcortical seizures; 60 mg/kg ( $n = 4$ ) induced simultaneous cortical and subcortical seizures in all animals with a mean latency

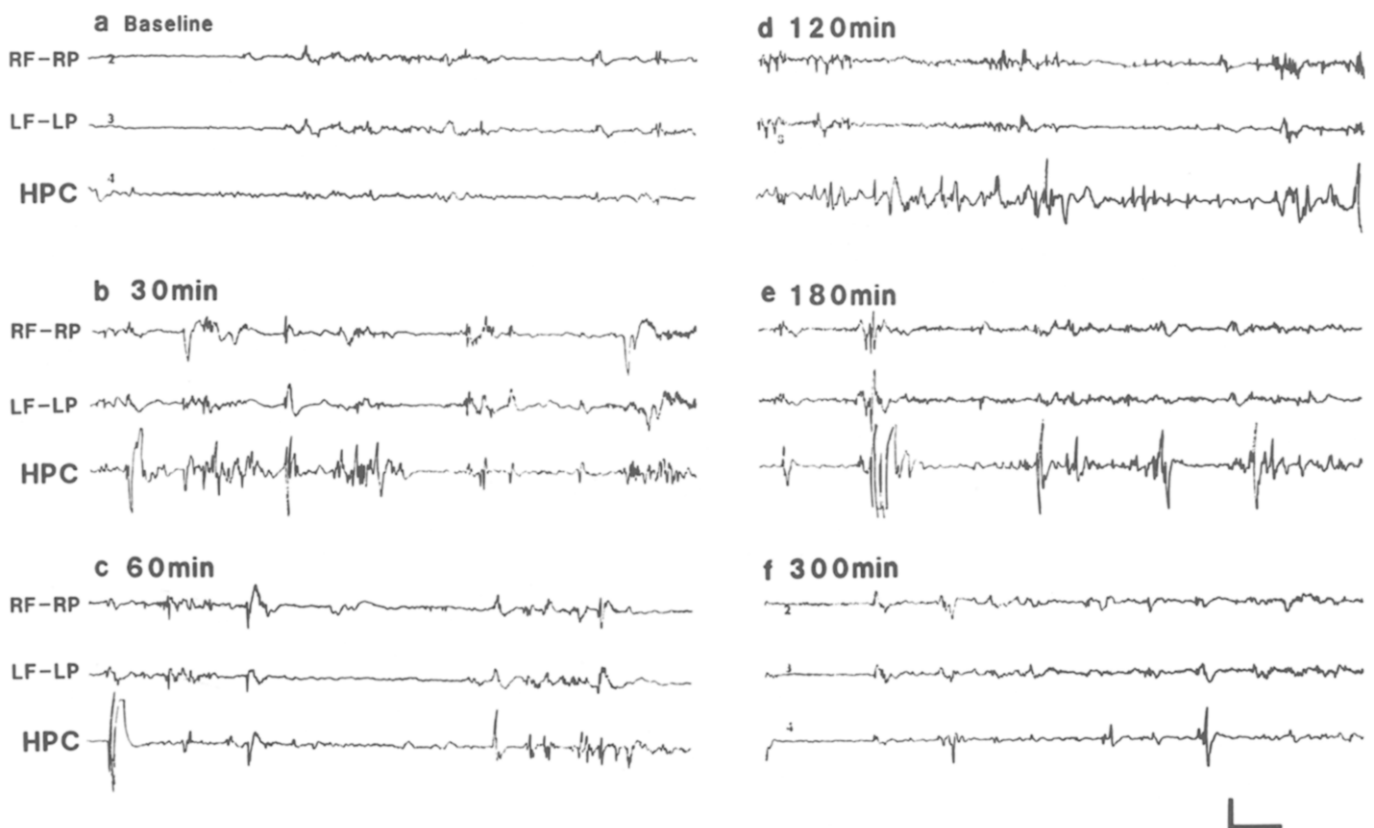


Fig. 1. Serial EEG recordings from a 3 day-old rat which received 60 mg/kg pilocarpine 20 h after lithium 3 meq/kg. a: baseline recording 20 h following lithium, but prior to pilocarpine administration. b–f: EEG recorded from cortical and hippocampal electrodes 30–300 min after pilocarpine 60 mg/kg. The recordings show predominant movement artifact, a few isolated spikes and no electrographic seizure activity. R, right; L, left; F, frontal; P, parietal; HPC, hippocampus. Horizontal scale 2 s, vertical 100  $\mu$ V.

of  $53.9 \pm 11.6$  min. Status epilepticus was observed in 3 animals at a dose of 60 mg/kg with a mean latency of  $73.2 \pm 12.3$  min. Pilocarpine-induced seizures in this age group were characterized electrographically by the occurrence of generalized synchronous polyspikes for 5–10 s associated with scratching and tonic extension of hind limbs and tail. Status epilepticus was characterized by the occurrence of continuous generalized synchronous polyspikes and sharp waves associated with forelimb clonus and loss of postural control. After 2–3 h the EEG returned to baseline.

*11–14 days* ( $n = 18$ ; Fig. 3). Pilocarpine, 10 mg/kg ( $n = 6$ ) failed to induce cortical or subcortical seizures; 30 mg/kg dose induced electrographic seizures and status epilepticus in all animals with a mean latency of  $20.1 \pm 2.5$  min to seizure and  $44.1 \pm 14.0$  min to status epilepticus; 60 mg/kg induced electrical seizure activity recorded on EEG and status epilepticus in all animals with a mean latency of  $10.6 \pm 2.7$  min to seizure and  $24.1 \pm 5.1$  to status epilepticus. EEG changes and status epilepticus were similar to those exhibited in the 7–10-day-old group of animals. The EEG was abnormal 6 h after cessation of the lithium–pilocarpine-

duced status epilepticus and showed bilateral synchronous generalized spikes and sharp waves which were of larger amplitude than those seen after seizure in the 7–10-day-old group.

*15–21 days* ( $n = 24$ ; Fig. 4). Pilocarpine, 3 mg/kg ( $n = 6$ ) failed to induce cortical or subcortical seizures; 10 mg/kg ( $n = 6$ ) induced seizures and status epilepticus in four animals with a mean latency of  $40.8 \pm 27.3$  min to seizure and  $44.8 \pm 31.0$  min to status epilepticus. The EEG was abnormal 5 h after pilocarpine injection, showing generalized synchronous spike and wave at a frequency of 1 Hz. Both 30 and 60 mg/kg resulted in status epilepticus and death in all animals tested ( $n = 12$ ).

*22–30 days* ( $n = 18$ ; Fig. 5). Pilocarpine, 10 mg/kg ( $n = 6$ ) failed to induce cortical or subcortical seizures; 30 mg/kg induced electrographic seizures and status epilepticus in all animals tested with a mean latency of  $32.5 \pm 11.9$  min to seizure and  $43.3 \pm 8.6$  min to onset of status epilepticus. Simultaneous cortical and subcortical recordings obtained in two animals showed that the pilocarpine-induced electrical seizure activity appeared to originate in the nucleus accumbens–ventral

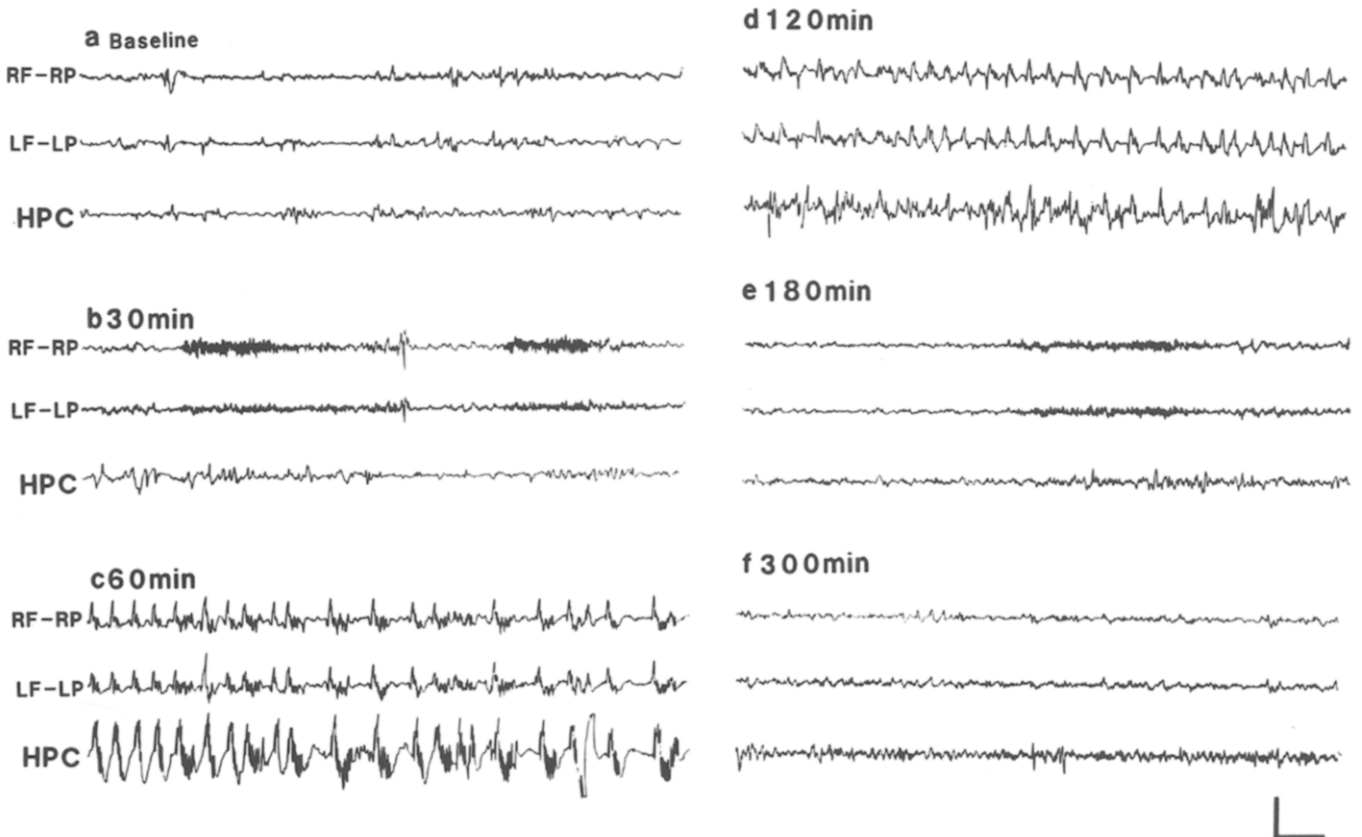


Fig. 2. Serial EEG recordings in a 9-day-old rat which received pilocarpine 60 mg/kg 20 h after lithium 3 meq/kg. a: baseline recording 20 h following lithium, but prior to pilocarpine administration. b: 30 min following 60 mg/kg pilocarpine; the EEG is unchanged from baseline. c: 60 min after pilocarpine injection; electrocorticographic and hippocampal recordings demonstrate bilateral polyspikes and sharp waves. Behaviorally these were accompanied by forelimb clonus and loss of postural control. d: 120 min after pilocarpine; the seizures described above continue. e–f: 180–300 min after pilocarpine administration; the seizures have ceased and the EEG returned to baseline. R, right; L, left; F, frontal; P, parietal; HPC, hippocampus. Horizontal scale 2 s, vertical 200  $\mu$ V.

TABLE I

Percentage of immature rats showing status epilepticus after lithium-pilocarpine

$n = 6$  for all age groups and all doses of pilocarpine. The dose of pilocarpine was administered s.c. 20 h following lithium chloride 3 meq/kg i.p.; (-) indicates that a study at this dose of pilocarpine was not done.

Pilocarpine dose (mg/kg)	Postnatal age (days)				
	3-6	7-10	11-14	15-21	22-30
3	-	-	0	0	-
10	-	0	0	67	0
30	0	0	100	100	100
60	0	67	100	100	100

pallidum with subsequent spread to the dorsal hippocampus and cortex. The one animal in this age group which survived the status epilepticus had an abnormal EEG 6 h after pilocarpine administration with bilateral

synchronous 1-2 Hz spike and wave and sharp wave discharges. All animals in the group who received 60 mg/kg pilocarpine developed status epilepticus and died ( $n = 6$ ).

#### Behavioral manifestation of seizures

Although these data were analyzed separately from the EEG data, no animal showed behavioral manifestations of seizures or status epilepticus without concomitant electrographic manifestations of seizure.

3-6 days. Pretreatment with lithium and pilocarpine in doses of 30 ( $n = 6$ ) and 60 mg/kg ( $n = 6$ ) induced hyperactivity, tremor and scratching movements. These behaviors appeared immediately following the administration of pilocarpine and lasted for 2-3 h. No behavioral response was seen to pilocarpine in doses of 3 or 10 mg/kg, nor did lithium alone produce any behavioral changes.

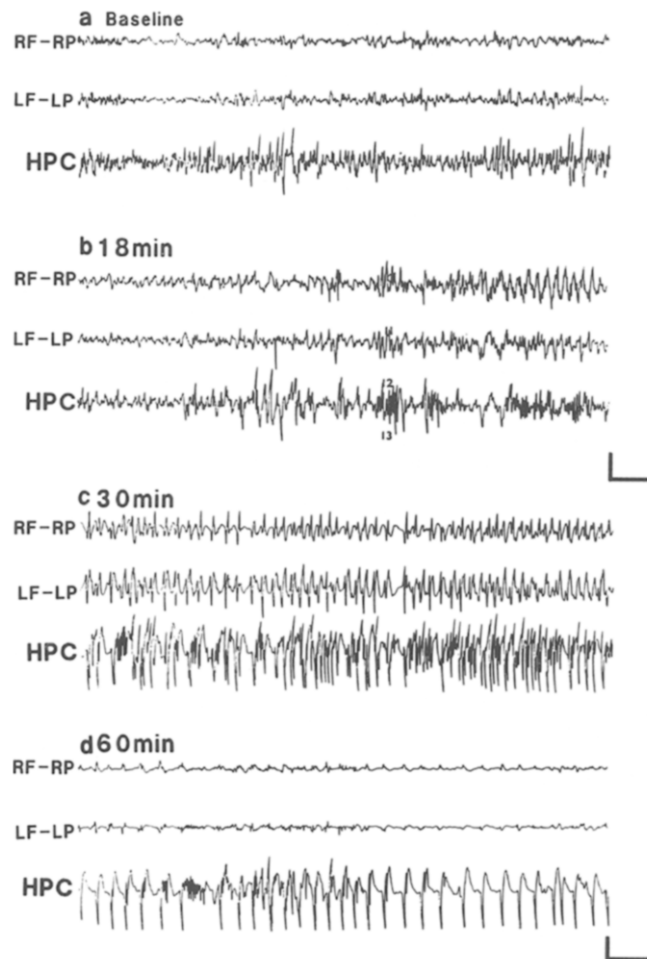


Fig. 3. Serial EEG recordings from an 11-day-old rat which received pilocarpine 60 mg/kg 20 h after lithium 3 meq/kg. a: baseline recording 20 h following lithium, but prior to pilocarpine administration. b: 18 min after pilocarpine administration; the electrographic seizure begins in hippocampus and cortex simultaneously. c: 30 min following pilocarpine administration; electrocorticographic and hippocampal recordings demonstrate bilateral polyspikes and sharp waves. Behaviorally these were accompanied by forelimb clonus and loss of postural control. d: 60 min following pilocarpine administration; there is marked attenuation of voltages in recordings from cortical electrodes but continuous spike wave discharges emanating from hippocampus. The animals showed hindlimb extensor tonus during this time. R, right; L, left; F, frontal; P, parietal; HPC, hippocampus. Top scale, horizontal 2 s, vertical 200  $\mu$ V. Bottom scale, horizontal 2 s, vertical 400  $\mu$ V.

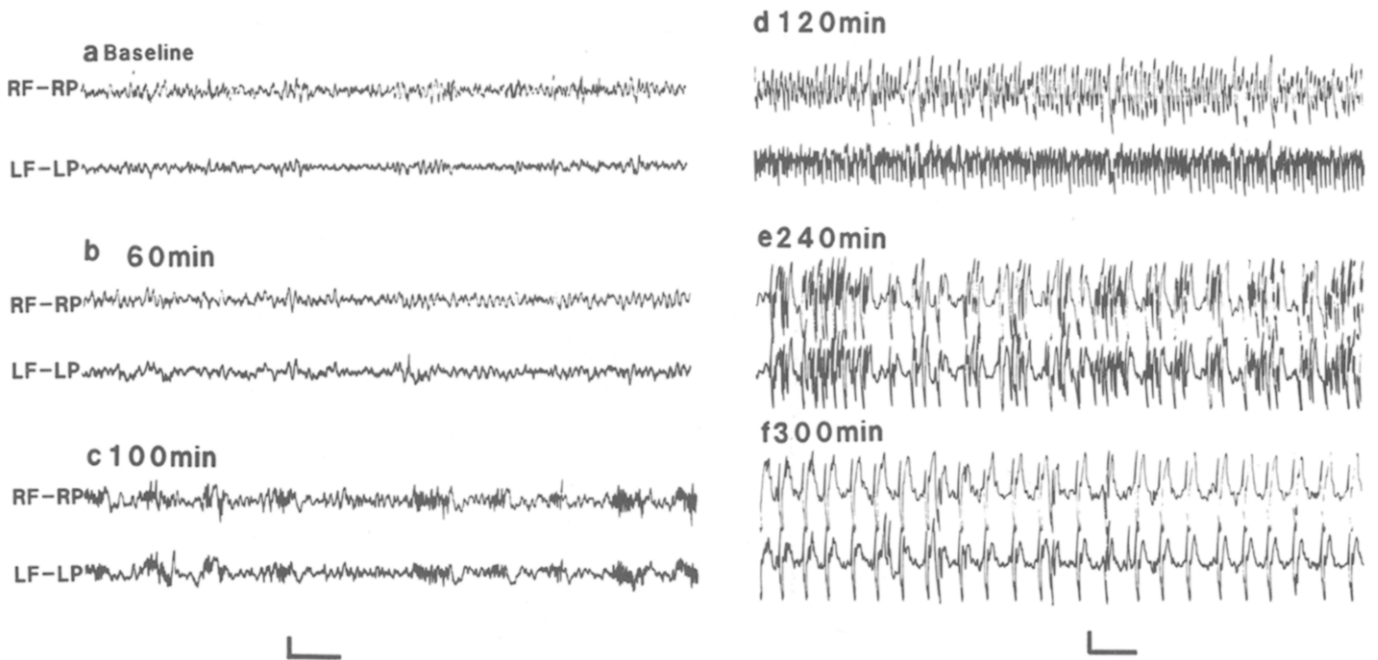


Fig. 4. Serial EEG recordings made from cortical electrodes in a 19-day-old rat which received pilocarpine 10 mg/kg 20 h after lithium 3 meq/kg. a: baseline recording 20 h following lithium, but prior to pilocarpine administration. b–c: 60 and 100 min following 10 mg/kg pilocarpine; the EEG is unchanged from baseline. d–f: 120–300 min after pilocarpine administration; bilateral polyspikes and sharp waves began and showed increasing amplitude over time. These were accompanied by forelimb clonus and loss of postural control. R, right; L, left; F, frontal; P, parietal. Left scale, horizontal 2 s, vertical 100  $\mu$ V. Right scale, horizontal 2 s, vertical 400  $\mu$ V.

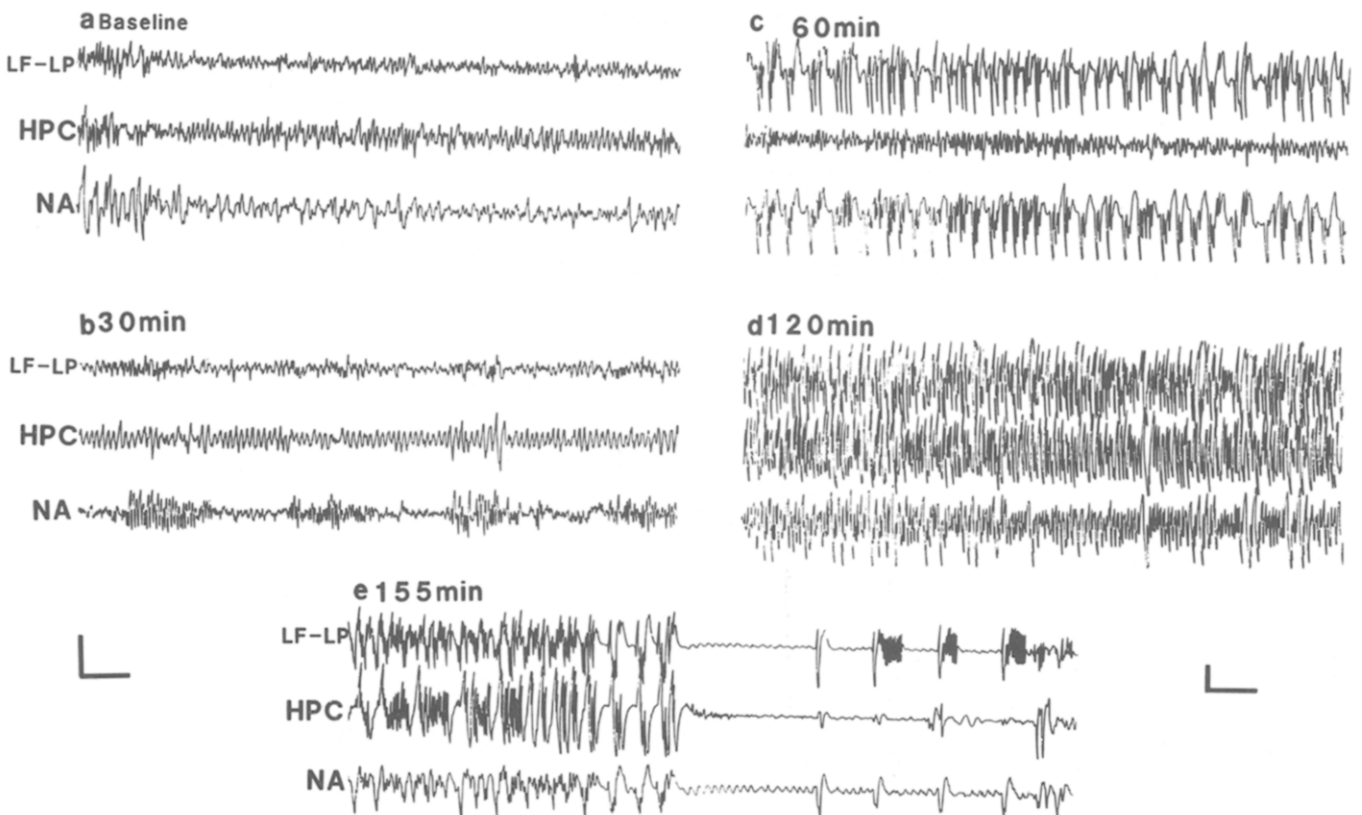


Fig. 5. Serial EEG recordings from a 27-day-old rat which received pilocarpine 30 mg/kg 20 h after lithium 3 meq/kg. This animal was implanted with bipolar electrodes in hippocampus and nucleus accumbens and monopolar electrodes in cortex. a: baseline recording 20 h following lithium, but prior to pilocarpine administration. b: 30 min after pilocarpine administration; initial polyspikes were recorded from bipolar electrodes in the nucleus accumbens. c: 60 min after pilocarpine administration; electrographic seizures were recorded from both cortex and nucleus accumbens, but no seizures were observed at this time in the hippocampus. d–e: 120 and 155 min following pilocarpine administration; seizures now involve cortex, nucleus accumbens and hippocampus. L, left; F, frontal; P, parietal; HPC, hippocampus; NA, nucleus accumbens. Left scale, horizontal 2 s, vertical 200  $\mu$ V. Right scale, horizontal 2 s, vertical 400  $\mu$ V.

7–10 days. Pilocarpine 30 mg/kg ( $n = 6$ ) induced defecation, continuous scratching and body tremor, but no behavioral seizures; 60 mg/kg resulted in tonic extension of hind limbs and tail, sustained clonic movements of the forelimbs and loss of postural control in four of the six animals tested. All animals who experienced these seizures survived.

11–14 days. Pilocarpine 10 mg/kg ( $n = 6$ ), induced defecation, salivation, body tremor and scratching in all animals, but no behavioral seizure activity; 30 mg/kg induced seizures and status epilepticus in all animals ( $n = 6$ ). Status epilepticus was defined as sustained orofacial automatisms, salivation, forelimb clonus, and rearing and falling in all animals. All animals survived the status epilepticus induced by 30 mg/kg. Status epilepticus was observed in all animals at 60 mg/kg ( $n = 6$ ), but 4 animals died at this higher dose of pilocarpine 2 h after administration of the drug.

15–21 days. Pilocarpine, 3 mg/kg ( $n = 6$ ) induced no behavioral abnormalities; 10 mg/kg ( $n = 6$ ) induced seizures and status epilepticus in 4 animals similar to that seen in 11–14-day-old animals treated with 30 mg/kg of pilocarpine, with all animals surviving. The 30 mg/kg dose of pilocarpine induced status epilepticus in all 15–21-day-old animals tested ( $n = 6$ ). Two of these animals died 1 h following administration of pilocarpine; 60 mg/kg pilocarpine resulted in status epilepticus and death within 1 h of drug administration in all animals ( $n = 6$ ).

22–30 days. Pilocarpine 10 mg/kg ( $n = 6$ ) induced defecation, salivation and tremor but no seizures; 30 mg/kg induced status epilepticus in all animals. Three animals died within 2 h following the injection of the drug; 60 mg/kg resulted in status epilepticus in all animals with death in 5/6 animals within 2 h.

### Pathology

Histopathologic examination was done on 24 animals ranging in age from 7 to 30 days. These animals were those described above who experienced lithium–pilocarpine seizures and survived. Light microscopic examination of brain sections taken from these animals failed to reveal any morphological alterations.

### DISCUSSION

This study demonstrates that systemic injection of low doses of pilocarpine can induce status epilepticus in developing rats pretreated with lithium.

The cholinergic neuronal network is functional by the end of the second week of life in rats. The concen-

tration of acetylcholine rises to 29% of adult levels by birth and attains adult levels by 4 weeks postpartum<sup>8</sup>. From 7 to 28 postnatal days of age the specific activity of whole brain choline acetyltransferase increases from 8 to 83% of that found in adult brain<sup>8</sup>. [<sup>3</sup>H]Quinclidinyl benzylate, a specific muscarinic agonist, reaches adult levels in the hippocampus at an age of 12–14 days of life<sup>4</sup>.

Experimental epileptogenic phenomena mediated by cholinergic mechanisms also appear to be demonstrable by the end of the second week of life. Focal spike discharges induced by intracortical administration of acetylcholine have been reported in 12-day-old rats<sup>19</sup>. In addition, pilocarpine alone in a dose of 380 mg/kg induces behavioral and EEG manifestations of status epilepticus in rats during the second week of life<sup>6</sup>. The current study is in agreement with these published data since it suggests that the mechanisms by which lithium potentiates pilocarpine are also in place by the second week of life. There was over a 12-fold potentiation of the epileptogenic effects of pilocarpine by lithium demonstrated in the developing animals which is similar to that published for adults rats<sup>11</sup>.

The proconvulsant effect of lithium is specifically limited to muscarinic cholinergic agonists<sup>15</sup>. However, the way in which lithium exerts this effect remains to be identified. Possible mechanisms include stimulation of acetylcholine synthesis and release<sup>11</sup> or inhibition of phosphoinositide hydrolysis<sup>5,9</sup> and/or cyclic AMP production in rat brain<sup>13</sup>.

The susceptibility to lithium–pilocarpine-induced status epilepticus is increased during the third week of life since 15–21-day-old animals treated with pilocarpine 10 mg/kg exhibited status epilepticus while the same dose of pilocarpine failed to induce status epilepticus during the first two weeks of life or in animals older than 21 days. An increased susceptibility to pilocarpine<sup>2,6</sup> and other proconvulsant drugs<sup>1,3,6</sup> during a similar time period has been reported previously although some authors have not observed this developmental window of increased susceptibility to seizure<sup>23</sup>. One possible explanation for this phenomenon could be related to the precocious development of the excitatory systems within limbic structures and the delayed appearance of inhibitory mechanisms at this age<sup>16</sup>. An alternative explanation for the differential susceptibility of developing animals to pilocarpine after lithium pretreatment may relate to changes in the blood-brain barrier with development. This could be reflected by age-dependent changes in the pharmacokinetics of pilocarpine and/or lithium following systemic administration. Hence the developmental changes observed could reflect differing brain concentrations of lithium

and/or pilocarpine achieved in animals of different ages.

Adults rats who survive lithium-pilocarpine-induced status epilepticus have been reported to show widespread brain lesions in the ventral forebrain area<sup>7</sup>. However, we failed to demonstrate any brain lesions in developing animals that experienced lithium-pilocarpine-induced status epilepticus. The literature suggests that immature rats are more resistant to the development of seizure-induced brain damage than adult animals. For example, in the kainic acid model of limbic seizures and status epilepticus no lesions are described until 33–37 days of life<sup>1</sup>. Pilocarpine alone in rat pups is reported to induce an attenuated pattern of damage compared to that seen in adults. The damage in immature animals treated with high dose pilocarpine is limited to shrinkage of cells and loss of neurons in hippocampus, amygdala, olfactory cortex, neocortex and certain thalamic nuclei<sup>6</sup>. In a model of status epilepticus induced by systemic injection of bicuculline in three species of young animals, Wasterlain et al.<sup>22</sup> showed that severe status epilepticus produced no ischemic cell necrosis in the immature animals.

In conclusion, we have delineated an electrographic and behavioral model of status epilepticus during the first weeks of postnatal life in rats. This paradigm promises to be a useful model for further investigation of the genesis and propagation of seizures in developing brain.

*Acknowledgements.* This work was supported in part by Grant NS17117 from the NINDS.

## REFERENCES

- Albala, B.J., Moshe, S.L. and Okada, R., Kainic acid-induced seizures: a developmental study, *Dev. Brain Res.*, 13 (1984) 139–148.
- Baez, L.A., Eskridge, N.K. and Schein, R., Postnatal development of dopaminergic and cholinergic catalepsy in the rat, *Eur. J. Pharmacol.*, 36 (1976) 155–162.
- Baram, T.Z. and Snead III, O.C., Bicuculline induced seizures in infant rats: ontogeny of behavioral and electrocortical phenomena, *Dev. Brain Res.*, 57 (1990) 291–295.
- Ben-Barak, J. and Dudai, Y., Cholinergic binding sites in rat hippocampal formation: properties and ontogenesis, *Brain Res.*, 166 (1979) 245–257.
- Casebolt, T.L. and Jope, R.S., Long term lithium treatment selectively reduces receptor-coupled inositol phospholipid hydrolysis in rat brain, *Biol. Psychiat.*, 25 (1989) 329–340.
- Cavalheiro, E.A., Delrio, F.S., Turski, W.A., Calderazzo-Filho, L.S., Bortolotto, Z.A. and Turski, L., The susceptibility of rats to pilocarpine-induced seizures is age-dependant, *Dev. Brain Res.*, 37 (1987) 43–58.
- Clifford, D.B., Olney, J.W., Maniotis, A., Collins, C. and Zorumsky, F., The functional anatomy and pathology of lithium-pilocarpine and high-dose pilocarpine seizures. *Neuroscience*, 23 (1987) 953–958.
- Coyle, J.T. and Yamamura, H.I., Neurochemical aspects of the ontogenesis of cholinergic neurons in the rat brain, *Brain Res.*, 118 (1976) 429–440.
- Godfrey, P.P., McClue, S.J., White, A.M., Wood, A.J. and Grahame-Smith, D.G., Subacute and chronic in vivo lithium treatment inhibits agonist- and sodium fluoride-stimulated inositol phosphate production in rat cortex, *J. Neurochem.*, 52 (1989) 498–506.
- Honchar, M.P., Olney, J.W. and Sherman, W.R., Systemic cholinergic agents induce seizures and brain damage in lithium-treated rats, *Science*, 220 (1983) 323–325.
- Jope, R.S., Morrisett, R. and Snead, O.C., Characterization of lithium potentiation of pilocarpine-induced status epilepticus in rats, *Exp. Neurol.*, 91 (1986) 471–480.
- Jope, R.S., Effects of lithium treatment in vitro and in vivo on acetylcholine metabolism in rat brain, *J. Neurochem.*, 33 (1979) 487–495.
- Mork, A. and Geisler, A., Effects of GTP on hormone-stimulated adenylyl cyclase activity in cerebral cortex, striatum and hippocampus from rats treated chronically with lithium, *Biol. Psychiat.*, 26 (1989) 279–288.
- Persinger, M.A., Makarec, K. and Bradley, J.C., Characteristics of limbic seizures evoked by peripheral injections of lithium and pilocarpine, *Physiol. Behav.*, 44 (1988) 27–37.
- Post, R.M., Weiss, S.R.B. and Pert, A., Differential effects of carbamazepine and lithium on sensitization and kindling, *Biol. Psychiat.*, 8 (1984) 425–434.
- Ricci, G.F., Mecarelli, O. and de Feo, M.R., Ontogenesis of GABAergic and glutamergic receptors in the developing brain. In C.G. Wasterlain and P. Vert (Eds.), *Neonatal Seizures*, Raven, New York, 1990, pp. 209–220.
- Sherwood, N.M. and Timiras, P.S., *A Stereotaxic Atlas of the Developing Rat Brain*, University of California Press, London, 1970.
- Snead III, O.C. and Stephens, H.I., Ontogeny of cortical and subcortical electroencephalographic events in unrestrained neonatal and infant rats, *Exp. Neurol.*, 82 (1983) 249–269.
- Staudacherova, D., Mares, P., Kozakova, H. and Camutaliova, M., Ontogenic development of acetylcholine and atropine epileptogenic cortical foci in rats, *Neuroscience* 3 (1978) 749–753.
- Turski, L., Ikonomidou, C., Turski, W., Bortolotto, Z.A. and Cavalheiro, E.A., Cholinergic mechanisms and epileptogenesis: the seizures induced by pilocarpine: a novel experimental model of intractable epilepsy, *Synapse*, 3 (1989) 154–171.
- Turski, W.A., Cavalheiro, E.A., Schwarz, M., Schwarz, M., Czuczwar, S.J., Kleirok, Z. and Turski, L., Limbic seizures produced by pilocarpine in rats: behavioral, electroencephalographic and neuropathological study, *Behav. Brain Res.*, 9 (1983) 315–336.
- Wasterlain, C.G., Brain metabolism during prolonged seizures in neonates. In A.V. Delgado-Escueta, D.M. Treiman and R.G. Porter (Eds.), *Advances in Neurology*, Vol. 42, Raven, New York, 1983, pp. 241–275.
- Zouhar, A., Mares, P., Liskova-Bernasdova, K. and Mudrochova, M., Motor and electrocorticographic epileptic activity induced by bicuculline in developing rats, *Epilepsia*, 30 (1989) 501–510.