

**UCLA**

**Proceedings of UCLA Health**

**Title**

Subacute Combined Degeneration due to Recreational Nitrous Oxide Inhalation

**Permalink**

<https://escholarship.org/uc/item/8b2317v6>

**Journal**

Proceedings of UCLA Health, 24(1)

**Authors**

Niknam, Daniel

Kayano, Junya

**Publication Date**

2021-02-03

## CLINICAL VIGNETTE

# Subacute Combined Degeneration due to Recreational Nitrous Oxide Inhalation

Daniel Niknam, DO and Junya Kayano, MD

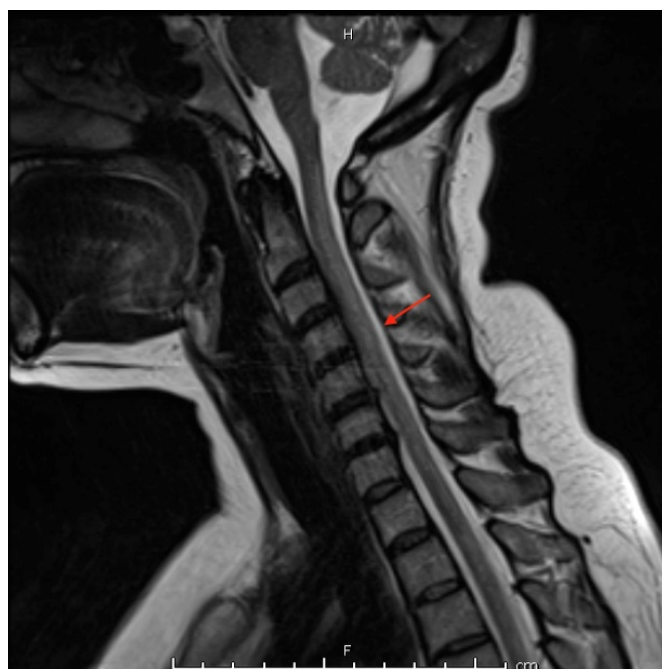
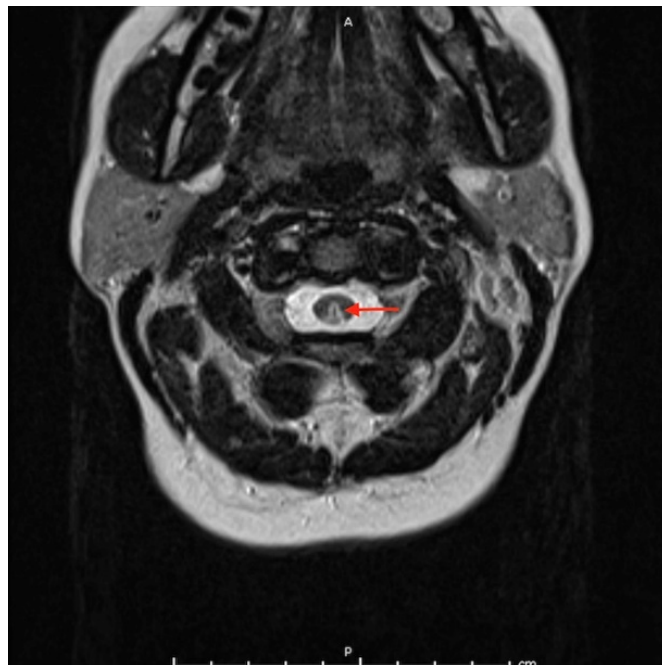
### Introduction

Subacute combined degeneration (SCD) is characterized by degeneration of the posterior and lateral columns of the spinal cord due to vitamin B12 deficiency. SCD is more commonly seen in states of vitamin B12 malabsorption (e.g. pernicious anemia, gastrectomy, tropical sprue, ileal disease), pancreatic insufficiency, and inadequate intake such as in vegetarianism or veganism.<sup>1</sup> However, SCD can also less commonly be seen in nitrous oxide (N<sub>2</sub>O) toxicity, which impairs vitamin B12 metabolism. We present a case that highlights the importance of considering nitrous oxide induced subacute combined degeneration in a patient with multidrug use and neurological symptoms.

### Case Presentation

This was a 40-year-old female with a history of anxiety, depression, psychosis, multidrug use presented with gait imbalance and bilateral lower extremity numbness over the last three months. She reported inhaling nitrous oxide via balloons for the past four months, up to 100 balloons per day, with each balloon providing. She reported lower extremity weakness and difficulty walking as if her legs were falling asleep. She also experienced intermittent numbness in her lower extremities, abdomen, and lower back. She has a history of chronic urinary incontinence, but stated that her incontinence was due to not making it to the bathroom in time from her gait imbalance. Her exam was notable for an anxious appearing female with delusional thoughts. Neurological exam revealed poor memory recall. She had mild ataxia, spastic tone throughout her extremities, bilateral positive Hoffman test, and bilateral hyperreflexia. She had diminished vibration sense and absent proprioception in the halluces, clearly positive Romberg test, and abnormal finger to nose bilaterally. Her posture was stiff and wide based, gait was wide based with poorly spaced steps. She was unable to perform tandem gait.

Labs were significant for vitamin B12 level 174 (pg/ml), methylmalonic acid 1007 (nmol/L), and homocysteine 27.9 (umol/L). TSH and HbA1c were within normal limits and HIV and RPR were negative. Hemoglobin was 11.6 (g/dL) with MCV 99.2 (fL). MRI with contrast of the cervical and thoracic spine revealed increased T2 and STIR signal involving the posterior columns (Figure 1).



Neurology was consulted and determined that her clinical presentation was consistent with subacute combined degeneration due to vitamin B12 deficiency from N<sub>2</sub>O inhalation. Cessation of N<sub>2</sub>O inhalation was advised, and she was started on vitamin B12 1000mcg IV daily while hospitalized with modest improvement in symptoms. She was discharged on vitamin B12 1000mcg IM daily for 1 week, then 1000mcg IM weekly for 4 weeks, then 1000mcg PO daily thereafter. She was scheduled for outpatient neurology follow up for monitoring.

### Discussion

We present a case of a patient with heavy N<sub>2</sub>O use with signs of severe myelopathy, ataxia, impaired proprioception, and mental status changes. These findings, taken together with a low vitamin B12 level and MRI imaging findings demonstrating demyelination of the posterior spinal column, indicated a diagnosis of SCD.

N<sub>2</sub>O exerts its myelotoxicity by oxidizing the cobalt ion of vitamin B12, rendering it inactive. This results in inhibition of B12 as a cofactor of methionine synthase in the production of methionine and tetrahydrofolate, which are required for myelin sheath protein and DNA synthesis, respectively.<sup>2</sup> The resultant demyelination of the nervous system involves the spinal cord, particularly the posterior and lateral columns. Thus, N<sub>2</sub>O inactivation of vitamin B12 leads to subacute combined degeneration. Patients commonly present with subacute paraparesis and impaired proprioception and sensation. In addition to these common symptoms, our patient also had delusional thoughts and poor memory recall which can also be attributed to B12 deficiency. However, this association proved difficult to establish given her underlying history of psychosis in the setting of methamphetamine use. Regular outpatient follow-up with complete neurologic and mental status examinations will be necessary to determine if these symptoms resolve with B12 supplementation.

The diagnosis of SCD should be confirmed with low vitamin B12 levels and MRI findings. It appears that the myelotoxic changes are more often seen in the posterior rather than in the lateral columns.<sup>3</sup> Additionally, patients may not always present with low vitamin B12 levels, and in these cases high methylmalonic acid levels can be used to support the diagnosis.<sup>4</sup> Cessation of N<sub>2</sub>O inhalation and high dose vitamin B12 replacement are the mainstays of treatment. There are mixed reports of the efficacy of therapy, but recovery is usually slow and incomplete and is dependent on the degree of initial damage to the spinal cord.<sup>5</sup> It will be interesting to see the degree of recovery in our patient at her follow up appointment.

### Conclusion

Nitrous oxide is commonly used as an anesthetic agent ("laughing gas") and there have been reports of iatrogenic SCD from N<sub>2</sub>O anesthesia, especially in those with baseline low to low-normal B12 levels.<sup>6</sup> N<sub>2</sub>O is also used in the automotive racing industry, and as an aerosol propellant such as in whipped

creams. However, more recently it has been estimated that approximately 800,000 adults abuse inhalants every year<sup>7</sup> and there has been an increased prevalence of N<sub>2</sub>O use as a recreational inhalant drug especially in the dance and festival scenes.<sup>8</sup> Given the increased prevalence of N<sub>2</sub>O use, it is even more important for clinicians to recognize N<sub>2</sub>O use as an uncommon cause of SCD. Nitrous oxide is readily available to the public in the form of "whippits", which are aerosol chargers used in canisters of whipped cream. The nitrous oxide is discharged into a balloon and then inhaled, as was the case in our patient. Providers should have sufficient clinical knowledge of toxidromes associated with recreational drug use and understand the physiologic consequences of these drugs in order to effectively manage these patients.

Recreational use of nitrous oxide inhalation is an increasing cause of subacute combined degeneration that should be recognized by all providers. By understanding the physiologic manifestations associated with nitrous oxide toxicity, providers can be prepared to recognize, manage, and counsel their patients on the harms of nitrous oxide use.

### REFERENCES

1. **Reynolds E.** Vitamin B12, folic acid, and the nervous system. *Lancet Neurol.* 2006 Nov;5(11):949-60. doi: 10.1016/S1474-4422(06)70598-1. PMID: 17052662.
2. **Shulman RM, Geraghty TJ, Tadros M.** A case of unusual substance abuse causing myeloneuropathy. *Spinal Cord.* 2007 Apr;45(4):314-7. doi: 10.1038/sj.sc.3101962. Epub 2006 Aug 8. PMID: 16896338.
3. **Ilniczky S, Jelencsik I, Kenéz J, Szirmai I.** MR findings in subacute combined degeneration of the spinal cord caused by nitrous oxide anaesthesia--two cases. *Eur J Neurol.* 2002 Jan;9(1):101-4. doi: 10.1046/j.1468-1331.2002.00336.x. PMID: 11784385.
4. **Stockton L, Simonsen C, Seago S.** Nitrous oxide-induced vitamin B12 deficiency. *Proc (Bayl Univ Med Cent).* 2017 Apr;30(2):171-172. doi: 10.1080/08998280.2017.11929571. PMID: 28405070; PMCID: PMC5349816.
5. **Vasconcelos OM, Poehm EH, McCarter RJ, Campbell WW, Quezado ZM.** Potential outcome factors in subacute combined degeneration: review of observational studies. *J Gen Intern Med.* 2006 Oct;21(10):1063-8. doi: 10.1111/j.1525-1497.2006.00525.x. PMID: 16970556; PMCID: PMC1831618.
6. **Renard D, Dutray A, Remy A, Castelnovo G, Labauge P.** Subacute combined degeneration of the spinal cord caused by nitrous oxide anaesthesia. *Neurol Sci.* 2009 Feb;30(1):75-6. doi: 10.1007/s10072-009-0013-2. Epub 2009 Jan 24. PMID: 19169627.
7. Results from the 2007 National Survey on Drug Use and Health: National Findings (DHHS Publication No. SMA 08-4343) Rockville, MD: Substance Abuse and Mental Health Services Administration, 2008; Substance Abuse and Mental Health Services Administration Office of Applied Studies.

8. **van Amsterdam J, Nabben T, van den Brink W.** Recreational nitrous oxide use: Prevalence and risks. *Regul Toxicol Pharmacol.* 2015 Dec;73(3):790-6. doi: 10.1016/j.yrtph.2015.10.017. Epub 2015 Oct 22. PMID: 26496821.