

UC Davis

Dermatology Online Journal

Title

Apocrine hidrocystoma on the nipple: the first report in this unusual location

Permalink

<https://escholarship.org/uc/item/89n4f0sf>

Journal

Dermatology Online Journal, 25(10)

Authors

Magdaleno-Tapial, Jorge
Valenzuela-Oñate, Cristian
Martínez-Doménech, Álvaro
et al.

Publication Date

2019

DOI

10.5070/D32510045825

Copyright Information

Copyright 2019 by the author(s). This work is made available under the terms of a Creative Commons Attribution-NonCommercial-NoDerivatives License, available at <https://creativecommons.org/licenses/by-nc-nd/4.0/>

Peer reviewed

Apocrine hidrocystoma on the nipple: the first report in this unusual location

Jorge Magdaleno-Tapia MD, Cristian Valenzuela-Oñate MD, Álvaro Martínez-Doménech MD, Marta García-Legaz-Martínez MD, Antonio Martínez-Aparicio PhD, Víctor Alegre-de Miquel PhD, Amparo Pérez-Ferriols PhD

Affiliations: Department of Dermatology, Consorcio Hospital General Universitario de Valencia, Spain

Corresponding Author: Jorge Magdaleno-Tapia, Avenida Tres Creus, 2, 46014, Valencia, Spain, Email: jormagta@gmail.com

Abstract

Apocrine hidrocystoma is a rare, benign, cystic tumor of the apocrine sweat glands. They are most commonly located around the eyes and may also be found on the scalp and neck. However, despite the fact that the nipple and areola contain numerous apocrine sweat glands, apocrine hidrocystomas have not been described previously in this area to the best of our knowledge. We report the first case of this cyst in this unusual location.

Keywords: *apocrine hidrocystoma, nipple*

Introduction

Apocrine hidrocystoma is a rare, benign, cystic tumor of the apocrine sweat glands. It most commonly presents as a solitary, asymptomatic papule or nodule and is most often located on the head and neck [1]. Apocrine hidrocystoma has also been reported in other sites, including the chest, shoulder, axilla, umbilicus, foreskin, penile shaft, vulva, and fingers. This is probably because apocrine glands are frequent in these locations [2]. However, the nipple and areola are also rich in apocrine glands and there are no reports of apocrine hidrocystoma at these locations. We present a rare case of an apocrine hidrocystoma of the nipple.

Case Synopsis

A 43-year-old woman presented with a two-month history of an asymptomatic nodule on her left nipple. She denied previous drainage of fluid from the

lesion. Physical examination revealed a translucent nodule, 10mm in diameter, not adhered to underlying tissue (**Figure 1**). The patient was not taking any medications and denied the use of drugs. She had no previous pregnancies and was not pregnant at the time. There was no history of preceding trauma. The patient reported no personal or familial history of skin or soft tissue malignancies. A recent mammography revealed no abnormal findings. The ultrasound image showed an oval, well-defined hypoechoic nodule in the left retroareolar area, with no attachment to adjacent structures (**Figure 2**). A shave biopsy was performed.

Histopathologic examination revealed a cystic space in the subcutaneous layer with papillary projections into the cyst lumen. The epithelial lining of the cyst was composed of columnar cells that showed decapitation secretion, indicating the presence of apocrine secretion. These findings were consistent with apocrine hidrocystoma (**Figure 3**).

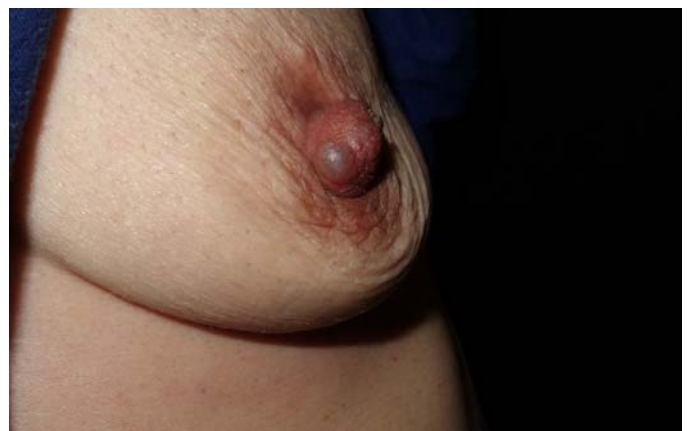

Figure 1. Smooth-surfaced, dome-shaped, translucent nodule on the left nipple.

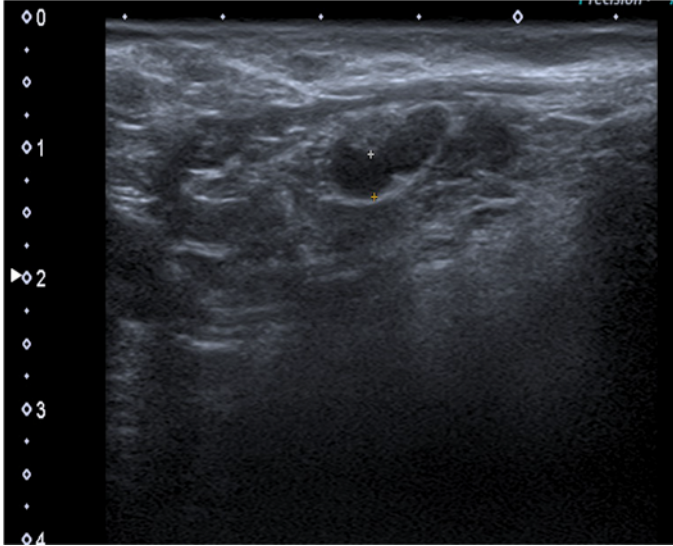


Figure 2. The ultrasound imagen showed an oval, well-defined hypoechoic nodule sin dermis.

Case Discussion

Hidrocystomas are rare, benign skin adnexal cystic tumors that arise from the apocrine secretory coli. They occur as asymptomatic, intradermal, translucent nodules with a smooth dome-shaped surface and color ranging from flesh-colored to blue-black. Apocrine hidrocystomas typically develop in adults between 30 and 75 years of age, although pediatric cases have been described [3]. Compared to their eccrine counterparts, apocrine hidrocystomas more commonly present as solitary lesions (Smith type), with a diameter of 3 to 15mm. Multiple hidrocystomas (Robinson type) may be associated with specific ectodermal dysplasia syndromes, including Schöpf-Schulz-Passarge syndrome or Goltz-Gorlin syndrome [2].

The most frequent locations of apocrine hidrocystomas are the face (61.1%), scalp (12.6%), trunk (13.7%), and extremities (12.0%), [1]. Although the nipple and areola contain numerous apocrine sweat glands [4], apocrine hidrocystomas have not been previously described in this area. Andersen WK et al. described an unusual superficial cyst on the nipple named hybrid epidermoid and apocrine cyst, whose epithelial lining was composed of apocrine cells immediately adjacent to keratinizing squamous epithelium with an intact granular layer [5]. This lesion can mimic other tumors that more frequently

present at this site, such as ductal papillomas, nipple adenomas [4], or epidermoid cysts [6]. It is necessary to perform imaging and a biopsy when there is suspicion of malignancy.

Histologically, apocrine hidrocystomas are large unilocular or multilocular dermal cysts typically lined by a double layer of epithelial cells. The outer layer consists of myoepithelial cells and the inner layer is composed of tall columnar cells. Decapitation secretion is usually present as the hallmark of apocrine glands [7]. Immunohistochemically, these are positive for human milk fat globules, gross cystic disease fluid protein-15, cytokeratin 7, and cytokeratin 18 in the inner layer of epithelium; they are, also positive for alpha-smooth muscle actin in the outer myoepithelial cells [2].

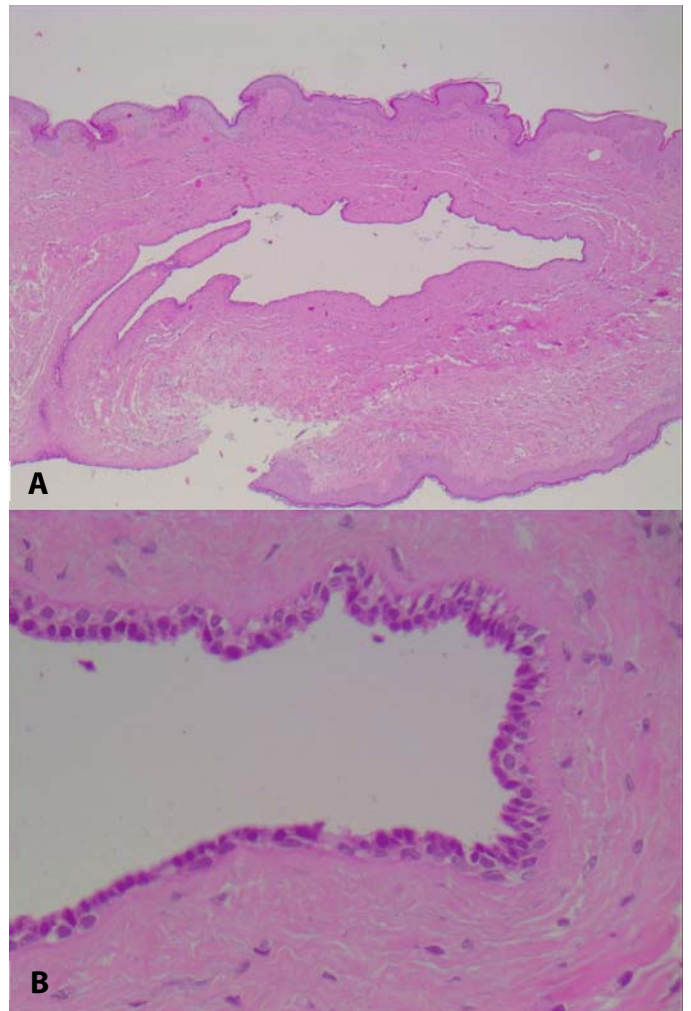


Figure 3. A) Apocrine hidrocystoma consisting of large cystic space in the dermis without contact with the epidermis. H&E, 10x. **B)** The epithelial lining of the cyst was composed of columnar cells that showed a decapitation secretion. H&E, 40x.

Although this tumor is benign, treatment is often pursued for aesthetic reasons and typically involves simple excision, electrodesiccation, or CO₂ laser therapy. Flattening after botulinum toxin A injections has been reported [8].

Conclusion

In conclusion, we an unusual case of apocrine

hidrocystoma developing on the nipple. This entity can mimic other tumors that more frequently present at this site. Imaging and skin biopsy are required for its diagnosis and when malignancy is suspected.

Potential conflicts of interest

The authors declare no conflicts of interests.

References

1. Lee MJ, Yang HJ, Kim JH, Yim HW, Lim JM, Lee HK. Apocrine hidrocystoma of the cheek. *Arch Plast Surg*. 2012;39:86-8. [PMID: 22783504].
2. Kikuchi K, Fukunaga S, Inoue H, Miyazaki Y, Ide F, Kusama K. Apocrine hidrocystoma of the lower lip: a case report and literature review. *Head Neck Pathol*. 2014;8:117-21. [PMID: 23740163].
3. Hafsi W, Badri T. Apocrine Hidrocystoma. *StatPearls Publishing*. 2019 May 2. [PMID: 28846245].
4. Stone K, Wheeler A. A Review of Anatomy, Physiology, and Benign Pathology of the Nipple. *Ann Surg Oncol*. 2015;22(10):3236-40. [PMID: 26242366].
5. Andersen WK, Rao BK, Bhawan J. The hybrid epidermoid and apocrine cyst. A combination of apocrine hidrocystoma and epidermal inclusion cyst. *Am J Dermatopathol*. 1996;18:364-6. [PMID: 8879299].
6. Dilek N, Dilek AR, Saral Y, Şehitoğlu I. Epidermoid cyst on the nipple: a rare location. *Breast J*. 2014;20:203-4. [PMID: 24405334].
7. May C, Chang O, Compton N. A giant apocrine hidrocystoma of the trunk. *Dermatol Online J*. 2017;23(9). [PMID: 29469730].
8. Bordelon JR, Tang N, Elston D, Niedt G, Lazic Strugar T. Multiple apocrine hidrocystomas successfully treated with botulinum toxin A. *Br J Dermatol*. 2017;176:488-490. [PMID: 27233901].