

# **UCLA**

## **Proceedings of UCLA Health**

### **Title**

Don't Breathe Easy Yet: Post-Extubation Pneumothorax Related to the Use of Noninvasive Ventilation

### **Permalink**

<https://escholarship.org/uc/item/8997m526>

### **Journal**

Proceedings of UCLA Health, 22(1)

### **Authors**

Lanks, Charles W.

Can, Argun

### **Publication Date**

2017-12-18

## CLINICAL VIGNETTE

---

# Don't Breathe Easy Yet: Post-Extubation Pneumothorax Related to the Use of Noninvasive Ventilation

---

Charles W. Lanks, MD and Argun Can, MD

### *Introduction*

Discontinuation of mechanical ventilation is the goal for patients intubated in the Intensive Care Unit (ICU). Mechanically ventilated patients are exposed to a myriad of potential complications including tracheal injury, ventilator associated infections, over-sedation and pneumothorax.<sup>1</sup> Therefore, shortening time on mechanical ventilation is a priority. Aggressively weaning from the ventilator, however, can occasionally lead to early extubation which may culminate in recurrent intubation. Importantly, reintubation has been linked to increased mortality rates in the ICU.<sup>2</sup>

Extubating some mechanically ventilated patients to non-invasive positive pressure ventilation (NIPPV) reduces reintubation rates.<sup>3</sup> In select populations, NIPPV is routinely employed due to its ability to offload work of breathing, promote alveolar recruitment and augment minute ventilation to enhance CO<sub>2</sub> elimination in the spontaneously breathing patient. Increased intrathoracic pressure has the added benefit of reducing both preload and afterload in patients with congestive heart failure. However, when patients are in post-extubation respiratory distress, the combination of increased negative pleural pressure generated by the patient added to increased alveolar pressure from NIPPV can substantially increase transpulmonary pressure (the difference between alveolar pressure and pleural pressure). High transpulmonary pressure is the driving force behind barotrauma in the lung. While pneumothorax is a known potential complication of NIPPV,<sup>4</sup> there are few published reporting its incidence and mechanism in patients extubated to NIPPV.

### *Case Report*

A 30-year-old woman with a history of poorly controlled hyperthyroidism and methamphetamine abuse presented in a hyperthyroid state complicated by new onset atrial fibrillation and hypoxic respiratory failure due to flash pulmonary edema. Her temperature upon admission to the ICU was 38.5 °C, blood pressure was 134/84 mmHg, heart rate was 165 beats/minute and irregular, respiratory rate was 33 breaths/minute, and oxygen saturation by pulse oximetry was 91-96% on room air. She decompensated rapidly and required emergent endotracheal intubation. Her initial laboratory evaluation was notable for a low TSH of 0.02 uIU/mL, high free T4 of 3.88 ng/dL and high total T3 of 412 ng/dL. Admission urine

toxicology was positive for amphetamines. Her chest radiograph demonstrated pulmonary edema and her brain natriuretic peptide (BNP) was elevated at 3,402 pg/mL.

Her respiratory status stabilized with diuresis and improved control of her hyperthyroidism. Her subsequent ICU course was heavily influenced by generalized weakness and profound malnutrition that made weaning from the ventilator difficult. After six days, she was extubated, but quickly experienced dyspnea and an increased work of breathing. This occurred without significant gas exchange abnormalities to necessitate immediate reintubation. In the setting of new echocardiographic evidence of dilated cardiomyopathy, she was placed on NIPPV with an IPAP of 8 cmH<sub>2</sub>O and EPAP of 5 cmH<sub>2</sub>O which somewhat alleviated her symptoms. Her tidal volumes increased during this time.

Within 24 hours, she became acutely more dyspneic and a chest radiograph revealed bilateral pneumothoraces (Figure 1) prompting reintubation and bilateral tube thoracostomies. Over the subsequent two weeks, she could not be weaned from mechanical ventilation and ultimately received a dilational percutaneous tracheostomy. Her nutrition status, mobility and overall clinical condition gradually improved after the tracheostomy, and she was transferred to a rehabilitation center upon discharge from the hospital.

### *Discussion*

Non-invasive positive pressure ventilation delivers pressure to the lungs via a face mask or nasal apparatus in order to augment tidal volume, enhance minute ventilation and offset work of breathing. NIPPV is commonly used following extubation to decrease reintubation rates. Where is effective, it is applied early and titrated off gradually over the course of several hours. NIPPV mimics MV in its delivery of positive pressure to the lungs, but does not carry with it many of the risks associated with an endotracheal tube such as tracheal stenosis, ventilator associated pneumonia, and over-sedation. Pneumothorax occurs in approximately 10% of all endotracheally intubated patients, but in a series of patients with cystic fibrosis, only 1% of pneumothoraces were associated with NIPPV. The incidence of pneumothorax related to NIPPV is not well defined in more general populations, but presents a real clinical challenge when

it does occur. Pneumothorax is most common in the endotracheally intubated patient. However, in our patient, elevated transpulmonary pressure ( $P_{alveolar} - P_{pleural}$ ) actually increased after extubation. This occurred through a combination of two factors: 1) discontinuation of continuous chemical sedation and 2) increased negative pleural pressure generated by the patient. One goal of mechanical ventilation is to rest the muscles of respiration; sedation is often applied to achieve this end. Once mechanical ventilation is discontinued, sedation is stopped and this goal is deprioritized. When this happens, the transpulmonary pressure, or pressure across the visceral pleura of the lung, may increase.

Transpulmonary pressure is responsible for maintaining lung inflation at the end of exhalation and causing expansion of the lungs during inhalation (Figure 2A). While on a ventilator and in the absence of significant respiratory effort, pleural pressures are typically positive at the end of inspiration. This yields a transpulmonary pressure that is similar to, or only slightly higher than, that of the spontaneously breathing patient (Figure 2B). When the difference between alveolar and pleural pressure is high, the resultant force driving air into the alveoli and toward the pleural space becomes high as well. This leads to lung inflation, but can also be an impetus for barotrauma.

After stopping sedation, patients are expected to resume their usual respiratory efforts. This is not a problem in most cases, but can become one when patients become dyspneic. In those cases, pleural pressure during inspiration becomes extremely negative due to increased patient effort, as in post-extubation respiratory distress. It is in this very setting that NIPPV may be applied. Positive alveolar pressure is thus added to an already increased negative pleural pressure. Suddenly, transpulmonary pressure and tidal volumes are higher than they were when the patient was on the ventilator (Figure 2C). In our patient, this led to increasing tidal volumes post-extubation and bilateral pneumothoraces.

Compared to management of pneumothorax in other settings, the management of post-extubation pneumothorax can be slightly more complex. A prompt decision needs to be made regarding the timing of thoracotomy versus immediate re-intubation. Needle thoracotomy or chest tube placement should be prioritized if the respiratory failure is directly related to hemodynamic collapse. In most other circumstances, decompression of the pleural space and reintubation should, ideally, occur almost simultaneously. Re-intubation after a pneumothorax, but before thoracotomy could hasten the development of tension physiology as air is forced into the pleural space by the ventilator.

There are a number of well described risk factors for pneumothorax in mechanically ventilated patients. Increased risk in the setting of high alveolar pressures and tidal volumes has already been discussed. Furthermore, patients in whom the reduction of alveolar pressure and tidal volume cannot be achieved are more likely have more severe lung pathologies. The type of underlying lung disease also correlates with pneumothorax risk. Typical at-risk diseases include necrotizing pneumonia, obstructive lung disease and acute respiratory

distress syndrome. Because post-extubation pneumothorax is a relatively uncommon occurrence in the ICU, risk factors are not as well defined.

Our patient did not have a clear pulmonary diagnosis at the time of her admission, but may already have been at increased risk for pneumothorax due to extreme malnutrition. In patients with anorexia nervosa or other starvation states, lungs may be subject to developing structural abnormalities such as pulmonary emphysema.<sup>5</sup> Animal studies have also demonstrated that starvation states can alter the connective tissue components of the lung, with subsequent reduction in tissue elastic forces.<sup>6</sup> Stimulant use, but not thyrotoxicosis has been linked to pneumothorax as well. This phenomenon occurs exclusively in association with inhalation drug use where a forced Valsalva maneuver at the time of inhalation can precipitate lung injury.

### Figures

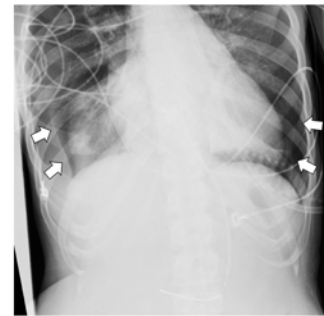


Figure 1 – Bilateral pneumothoraces after extubation while on noninvasive positive pressure ventilation. Upon recognition of this finding (radiograph performed for routine nasogastric tube placement confirmation) bilateral tube thoracostomies were performed.

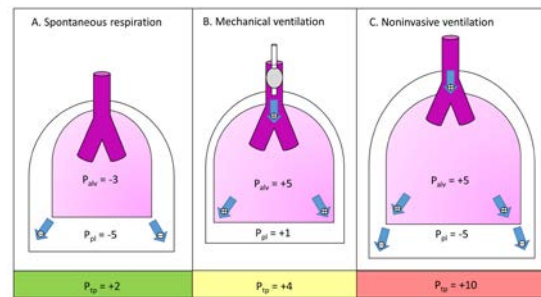


Figure 2 – (A) Transpulmonary pressure ( $P_{tp}$ ) in spontaneous respiration driven by negative pleural pressure ( $P_{pl}$ ). (B) Higher  $P_{tp}$  in mechanical ventilation driven primarily by positive alveolar pressure ( $P_{alv}$ ). (C) Potentially higher  $P_{tp}$  in noninvasive ventilation driven by **both** negative  $P_{pl}$  and positive  $P_{alv}$  leading to high tidal volumes and increased risk for lung injury.

### Conclusion

The occurrence of a pneumothorax in patient's extubated to NIPPV is an underappreciated and potentially devastating complication of respiratory failure. This mechanism of lung

injury is particularly easy to miss since it occurs during the process of recovery when invasive interventions are being withdrawn. Clinicians should carefully identify patients that might be at increased risk of this complication by monitoring for increasing tidal volumes, increasing work of breathing and escalating IPAP while on NIPPV.

## REFERENCES

1. **Brochard L, Slutsky A, Pesenti A.** Mechanical Ventilation to Minimize Progression of Lung Injury in Acute Respiratory Failure. *Am J Respir Crit Care Med.* 2017 Feb 15;195(4):438-442. doi: 10.1164/rccm.201605-1081CP. PubMed PMID:27626833.
2. **Frutos-Vivar F, Esteban A, Apezteguia C, González M, Arabi Y, Restrepo MI, Gordo F, Santos C, Alhashemi JA, Pérez F, Peñuelas O, Anzueto A.** Outcome of reintubated patients after scheduled extubation. *J Crit Care.* 2011 Oct;26(5):502-9. doi: 10.1016/j.jcrc.2010.1-2.015. Epub 2011 Mar 3. PubMed PMID: 21376523.
3. **Ferrer M, Valencia M, Nicolas JM, Bernadich O, Badia JR, Torres A.** Early noninvasive ventilation averts extubation failure in patients at risk: a randomized trial. *Am J Respir Crit Care Med.* 2006 Jan 15;173(2):164-70. Epub 2005 Oct 13. PubMed PMID: 16224108.
4. **Haworth CS, Dodd ME, Atkins M, Woodcock AA, Webb AK.** Pneumothorax in adults with cystic fibrosis dependent on nasal intermittent positive pressure ventilation (NIPPV): a management dilemma. *Thorax.* 2000 Jul;55(7):620-2. PubMed PMID: 10856325; PubMed Central PMCID: PMC1745802.
5. **Coxson HO, Chan IH, Mayo JR, Hlynsky J, Nakano Y, Birmingham CL.** Early emphysema in patients with anorexia nervosa. *Am J Respir Crit Care Med.* 2004 Oct 1;170(7):748-52. Epub 2004 Jul 15. PubMed PMID: 15256394.
6. **Sahebjami H, MacGee J.** Effects of starvation on lung mechanics and biochemistry in young and old rats. *J Appl Physiol.* 1985 Mar;58(3):778-84.

Submitted December 18, 2017