

# UCSF

## UC San Francisco Previously Published Works

### Title

An Abnormal Tibial Position Is Associated With Alterations in the Meniscal Matrix: A 3-Year Longitudinal Study After Anterior Cruciate Ligament Reconstruction

### Permalink

<https://escholarship.org/uc/item/88c7r6rt>

### Journal

Orthopaedic Journal of Sports Medicine, 7(1)

### ISSN

2325-9671

### Authors

Markes, Alexander R  
Knox, Joseph  
Zhong, Qunjie  
[et al.](#)

### Publication Date

2019

### DOI

10.1177/2325967118820057

Peer reviewed

# An Abnormal Tibial Position Is Associated With Alterations in the Meniscal Matrix

## A 3-Year Longitudinal Study After Anterior Cruciate Ligament Reconstruction

Alexander R. Markes,<sup>\*†</sup> Joseph Knox,<sup>†</sup> Qunjie Zhong,<sup>‡</sup> MD, Valentina Padoia,<sup>‡</sup> PhD, Xiaojuan Li,<sup>‡</sup> PhD, and C. Benjamin Ma,<sup>§</sup> MD

*Investigation performed at the Department of Radiology and Biomedical Imaging, and the Department of Orthopaedic Surgery, University of California, San Francisco, San Francisco, California, USA*

**Background:** An altered tibial position is still present despite anterior cruciate ligament (ACL) reconstruction. It has been demonstrated that an abnormal tibial position after an ACL injury may play a role in subsequent injuries to the meniscus, which can lead to early cartilage degeneration.

**Purpose:** To determine changes in both the tibial position and the meniscal matrix present before and after ACL reconstruction as well as to evaluate the association between these 2 variables in ACL-injured knees 3 years after reconstruction.

**Study Design:** Cohort study; Level of evidence, 2.

**Methods:** Bilateral knee magnetic resonance imaging (MRI) of 32 patients with unilateral ACL injuries was performed before reconstruction; 13 control participants also underwent MRI. Follow-up MRI was performed up to 3 years after surgery. Tibial position, internal tibial rotation, and T1 $\rho$  and T2 values of the menisci were calculated using an in-house MATLAB program. Student *t* tests and multiple linear regression were used to compare differences between injured, uninjured, and control knees as well as to assess correlations between the tibial position at 3 years and 3-year changes in quantitative MRI meniscal relaxation values.

**Results:** The tibial position of injured knees was more anterior than that of uninjured knees at baseline, 6 months, and 1, 2, and 3 years ( $P < .05$  for all). The T1 $\rho$  and T2 values of the menisci of injured knees were greater than those of uninjured and control knees in the posterior lateral and posterior medial horns up to 1 and 2 years after surgery, respectively ( $P < .05$  for all). The tibial position at 3 years was associated with increased T2 values from baseline to 3 years in the posterior medial horn ( $\beta = 0.397$ ;  $P = .031$ ) and anterior medial horn ( $\beta = 0.360$ ;  $P = .040$ ).

**Conclusion:** Results of the current study indicate that there is a persistently altered tibial position after ACL reconstruction. Initial preoperative meniscal abnormalities show prolonged but gradual improvement. Additionally, correlations between the tibial position and changes in the medial meniscal matrix suggest that the tibial position may play a role in the increased susceptibility to medial meniscal tears seen after reconstruction. The development of newer surgical techniques must address a persistently altered tibial position. Quantitative MRI is an effective instrument to evaluate meniscal matrix changes and can serve as an early radiological tool for meniscal injuries.

**Keywords:** ACL; knee; meniscus; imaging; magnetic resonance imaging

Although anterior cruciate ligament (ACL) reconstruction is a commonly performed procedure, the outcomes from long-term follow-ups of patients who have undergone this procedure are still concerning, with up to 50% of patients developing radiographic osteoarthritic changes.<sup>21,23</sup> The

current literature reports that the rate of meniscal tears after primary ACL reconstruction is 8.5% for medial meniscal tears and 1.3% for lateral meniscal tears.<sup>19,22</sup> In a cohort of 6576 patients, Dunn et al<sup>11</sup> demonstrated a 2 times higher rate of meniscal reoperations after an ACL tear for those treated nonoperatively versus operatively. However, a recent systematic review by Delincé and Ghafil<sup>10</sup> found that there was not enough evidence to recommend

The Orthopaedic Journal of Sports Medicine, 7(1), 2325967118820057

DOI: 10.1177/2325967118820057

© The Author(s) 2019

This open-access article is published and distributed under the Creative Commons Attribution - NonCommercial - No Derivatives License (<http://creativecommons.org/licenses/by-nc-nd/4.0/>), which permits the noncommercial use, distribution, and reproduction of the article in any medium, provided the original author and source are credited. You may not alter, transform, or build upon this article without the permission of the Author(s). For article reuse guidelines, please visit SAGE's website at <http://www.sagepub.com/journals-permissions>.

TABLE 1  
Demographic Information for the ACL and Control Groups<sup>a</sup>

	n	Age, Mean ± SD, y	BMI, Mean ± SD, kg/m <sup>2</sup>	Mean Time From Injury to Surgery, wk	Graft Type, n	
					Allograft	Autograft
ACL group						
Total	32	30.7 ± 7.2	24.1 ± 2.5	10.4	10	22
Male	18	31.8 ± 7.4	23.1 ± 2.1	11.1	3	15
Female	14	29.1 ± 7.0	24.8 ± 2.7	9.6	7	7
Control group						
Total	13	31.8 ± 4.7	23.5 ± 1.9	N/A	N/A	N/A
Male	8	31.6 ± 4.2	24.6 ± 1.0	N/A	N/A	N/A
Female	5	32.2 ± 5.9	21.7 ± 1.0	N/A	N/A	N/A

<sup>a</sup>ACL, anterior cruciate ligament; BMI, body mass index; N/A, not applicable.

systematic surgical reconstruction of all ACL-deficient patients to prevent further meniscal lesions and subsequent degeneration of the joint.

The exact mechanism of how ACL reconstruction affects the status of the meniscal matrix is still unclear. Despite success on certain clinical outcome measures, results from more objective measures such as motion analysis and magnetic resonance imaging (MRI) assert that there are persistent alterations in tibial position after ACL reconstruction, leading to altered mechanical loading of the knee.<sup>||</sup> Changes in the meniscal load distribution can increase the in situ forces in the meniscus.<sup>1</sup> Increases in meniscal shear forces are thought to play a role in the subsequent development of meniscal damage.<sup>24</sup> Meniscal damage has been associated with cartilage loss and joint degeneration.<sup>17,41</sup>

The meniscal fibrocartilage structure is a dense extracellular matrix composed primarily of water (72%), collagen (22%), and proteoglycans (<1%).<sup>12,36</sup> Meniscal damage has been previously linked to histological alterations in the collagen-proteoglycan matrix.<sup>25</sup> Recently, quantitative MRI (qMRI) comprising T1ρ and T2 protocols has been used to detect early signs of cartilage and meniscal degeneration.<sup>26,27,34,38,40</sup> In addition, a persistently altered tibial position after ACL reconstruction has been associated with elevated qMRI relaxation values of cartilage, suggesting that these changes may be indicative of future cartilage injuries.<sup>2,43</sup> To date, no longitudinal analysis has been performed on meniscal qMRI as it correlates to tibial position.

The objective of this study was to determine changes in both the tibial position and the meniscal matrix present

before and after ACL reconstruction as well as to evaluate the association between these 2 variables in ACL-injured knees 3 years after reconstruction.

## METHODS

### Participants

This longitudinal prospective study included 2 groups of patients. The ACL group was composed of 32 patients with a unilateral ACL injury who underwent “anatomic” single-bundle ACL reconstruction by 1 of 4 sports medicine fellowship-trained orthopaedic surgeons at a single institution. The control group was composed of 13 participants without a history of knee injuries, surgery, or clinical symptoms of osteoarthritis. The participant characteristics are detailed in Table 1. Exclusion criteria included previous injuries or surgery to either knee, history of inflammatory arthritic disease, injuries to other ligamentous structures needing a surgical intervention, concomitant meniscal repair, and concomitant cartilage resurfacing procedures performed at the time of surgery. ACL-injured patients had both injured (ipsilateral) and noninjured (contralateral) knees scanned at baseline before surgery and then again at 6 months, 1 year, 2 years, and 3 years after reconstruction. Patients in the control group had both knees scanned at baseline, 1 year, and 3 years. This study obtained institutional review board approval, and written informed consent was obtained from all enrolled participants.

<sup>||</sup>References 2-4, 15, 16, 32, 35, 38, 39, 42, 43.

\*Address correspondence to Alexander R. Markes, University of California, San Francisco, School of Medicine, 513 Parnassus Avenue, Suite S-245, San Francisco, CA 94243, USA (email: Alexander.Markes@ucsf.edu).

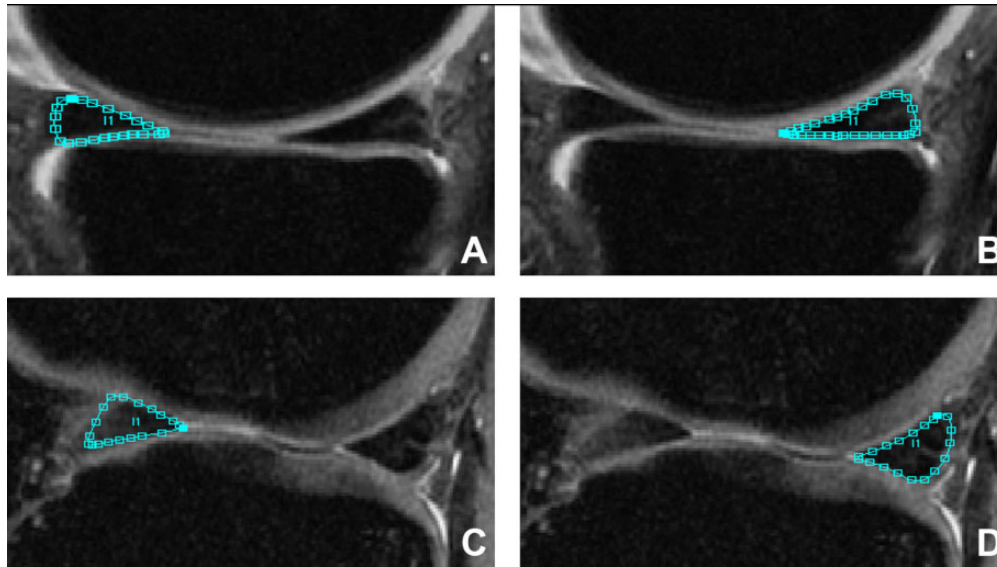
<sup>†</sup>University of California, San Francisco, School of Medicine, San Francisco, California, USA.

<sup>‡</sup>Department of Radiology and Biomedical Imaging, University of California, San Francisco, San Francisco, California, USA.

<sup>§</sup>Department of Orthopaedic Surgery, University of California, San Francisco, San Francisco, California, USA.

One or more of the authors has declared the following potential conflict of interest or source of funding: This study was supported by a grant from the National Institutes of Health/National Institute of Arthritis and Musculoskeletal and Skin Diseases (P50 AR606752) as well as the AOSSM/Genzyme (Cartilage Initiative Grant). X.L. receives research support from Ferring Pharmaceuticals and UCB. C.B.M. receives research support from Zimmer, Histogenics, and Moximed and is a paid consultant for Stryker, Zimmer, Conmed, Valeris, and Arthrex. AOSSM checks author disclosures against the Open Payments Database (OPD). AOSSM has not conducted an independent investigation on the OPD and disclaims any liability or responsibility relating thereto.

Ethical approval for this study was obtained from the University of California, San Francisco, Human Research Protection Program (No. 11-06734).



**Figure 1.** Segmentation images of meniscal horns: (A) anterior horn of the medial meniscus (AHMED), (B) posterior horn of the medial meniscus (PHMED), (C) anterior horn of the lateral meniscus (AHLAT), and (D) posterior horn of the lateral meniscus (PHLAT).

### Surgical Procedure

In the ACL group, single-bundle ACL reconstruction was performed using either a hamstring tendon autograft ( $n = 22$ ) or posterior tibial tendon allograft ( $n = 10$ ) with femoral tunnels drilled using anteromedial portal drilling. Additionally, 6 patients in the ACL group underwent concomitant partial meniscectomy: medial sided in 1 patient, lateral sided in 4 patients, and both medial and lateral in 1 patient. All patients underwent similar postoperative rehabilitation programs at the same institution's sports medicine clinic.

### MRI Protocol

Bilateral knees were scanned using a 3-T MRI scanner (GE Healthcare) with an 8-channel phased array knee coil (Invivo) at all time points. Patients were instructed to rest for 30 minutes before image acquisition in a seated, unloaded state. Imaging protocols included (1) high-resolution 3-dimensional (3D) fast spin echo (CUBE) (repetition time [TR]/echo time [TE] = 1500/25 milliseconds; field of view [FOV] = 16 cm; matrix =  $384 \times 384$ ; slice thickness = 1 mm; echo train length = 50; bandwidth = 50 kHz; number of excitations = 0.5), (2) sagittal 3D T1 $\rho$  and T2 quantification sequences (TR/TE = 9/3 milliseconds; FOV = 14 cm; matrix =  $256 \times 128$ ; slice thickness = 4 mm; views per segment = 64; time of recovery = 1.2 seconds; spin-lock frequency = 500 Hz; ARC [Autocalibrating Reconstruction for Cartesian imaging] phase acceleration factor = 2; time of spin lock [TSL] = 0/10/40/80 milliseconds for T1 $\rho$ ; preparation TE = 0/13.7/27.3/54.7 milliseconds for T2), and (3) sagittal T2-weighted 3D fast spin echo (TR/TE = 4000/49.3 milliseconds; slice thickness = 1.5 mm; spacing = 1.5 mm; FOV = 16 cm; matrix =  $512 \times$

512; echo train length = 9). The first 2 sequences were acquired with the knee unloaded; the third sequence was acquired with the knee extended and flexed ( $\sim 30^\circ$ ) with 25% body weight applied axially as previously explained.<sup>15</sup> This third sequence was used for tibial position and internal tibial rotation analysis. The combined time for acquisition of the T1 $\rho$  and T2 sequences was 9 minutes and 37 seconds, with the total time for 1 knee scan, including setup, being less than 1 hour.

### qMRI Meniscal Analysis

All image postprocessing was performed with a MATLAB program (MathWorks) developed in-house.<sup>5,8</sup> CUBE images were rigidly registered onto the first T1 $\rho$ -weighted image (TSL = 0) and subsequently used for meniscus segmentation at the baseline time point. Menisci were segmented by a single trained user on registered baseline CUBE images into 4 regions: anterior horn (AHLAT) and posterior horn (PHLAT) of the lateral meniscus and anterior horn (AHMED) and posterior horn (PHMED) of the medial meniscus (Figure 1). Three consecutive segmentations were used in each region. For all time points after baseline, a process of auto-segmentation was performed. For auto-segmentation, a longitudinal nonrigid registration was adopted to align the follow-up image on the baseline scan. The registration deformation field was computed in the T1 $\rho$ -weighted image with TSL = 0 characterized by a higher signal-to-noise ratio and then applied on all the later echoes. T1 $\rho$  and T2 maps were then computed voxel by voxel by fitting the monoexponential decay:

$$Signal_{TSL} \propto \exp\left(-\frac{TSL}{T1\rho}\right) Signal_{TE} \propto \exp\left(-\frac{TE}{T2}\right).$$

The menisci of patients who underwent partial meniscectomy were segmented at 6 months by a single trained user (A.R.M.), and for all the later time points, the same previously mentioned auto-segmentation process was adopted to align the follow-up image on the 6-month scan.

All auto-segmentations were quality checked by 2 trained users (A.R.M. and J.K.). Each auto-segmentation was evaluated and manually changed if it did not capture >80% of the meniscal area. Auto-segmentations alone correctly defined >90% of all segmentations used in this analysis. Intraclass correlation coefficients (ICCs) were calculated to determine the presence of interobserver bias between T1 $\rho$  and T2 relaxation times generated from auto-segmentations corrected by the 2 trained users. The ICCs of 0.961 (95% CI, 0.927-0.980) for T1 $\rho$  and 0.960 (95% CI, 0.924-0.979) for T2 relaxation times were comparable with results reported in the current literature on segmentation reproducibility.<sup>9,42</sup>

### qMRI Tibial Position and Internal Tibial Rotation Analysis

To determine the tibial position and internal tibial rotation, tibia and femur manual segmentations of the baseline contralateral knee were used to establish a coordinate system using an in-house MATLAB program previously described and demonstrated to have good reproducibility.<sup>7,8,20</sup> An iterative closest point registration technique was used to fit 3D cloud points obtained from segmentations.<sup>30</sup> The 3D nature of the registration allowed us to calculate the tibial position (the distance between the tibial and femoral coordinate systems) and internal tibial rotation (rotation of the tibia with respect to the femur), with a more positive tibial position corresponding to a more anterior position and a more positive internal tibial rotation corresponding to a more internally rotated knee.

### Statistical Analysis

Statistical analysis was performed using R version 3.4.0. Means and standard deviations of T1 $\rho$  and T2 values, tibial position, and internal tibial rotation were calculated at all time points for injured, contralateral, and control knees. To assess for variability of T1 $\rho$  and T2 values longitudinally in our comparison groups, 2-tailed Student *t* tests were used to compare T1 $\rho$  and T2 values of control and contralateral knees between time points within a given meniscal region. For cross-sectional analysis, 2-tailed Student *t* tests were used to compare T1 $\rho$  and T2 values, tibial position, and internal tibial rotation of ipsilateral knees with contralateral knees (paired *t* tests) and control knees (unpaired *t* tests).

Multiple linear regression was used to assess the correlations between the tibial position of ipsilateral knees at 3 years and 3-year changes in either T1 $\rho$  or T2 values of all 4 meniscal regions of ipsilateral knees. Valid regression models met the following criteria: (1) studentized residuals were normally distributed, (2) there was nonmulticollinearity of variables, (3) there was a significant *F* statistic ( $P < .05$ ), (4) there was

demonstrated independence of residuals, and (5) the data were nonheteroscedastic. Age, sex, and body mass index were not included in the models. Although some of these factors have been previously shown to affect T1 $\rho$  and T2 in cartilage, the same effect has not been documented in meniscal qMRI analysis.<sup>2</sup> Additionally, the decision to look at individual changes in T2 from baseline to 3 years acted as an internal control for any physiological differences in T1 $\rho$  or T2. Significance was defined as  $P < .05$  for both the Student *t* test and the regression analysis.

The multiple regression analysis evaluating associations between the tibial position at 3 years and 3-year changes in T1 $\rho$  values did not meet the validation parameters discussed above and thus was not included in this analysis.

## RESULTS

### Patient Demographics

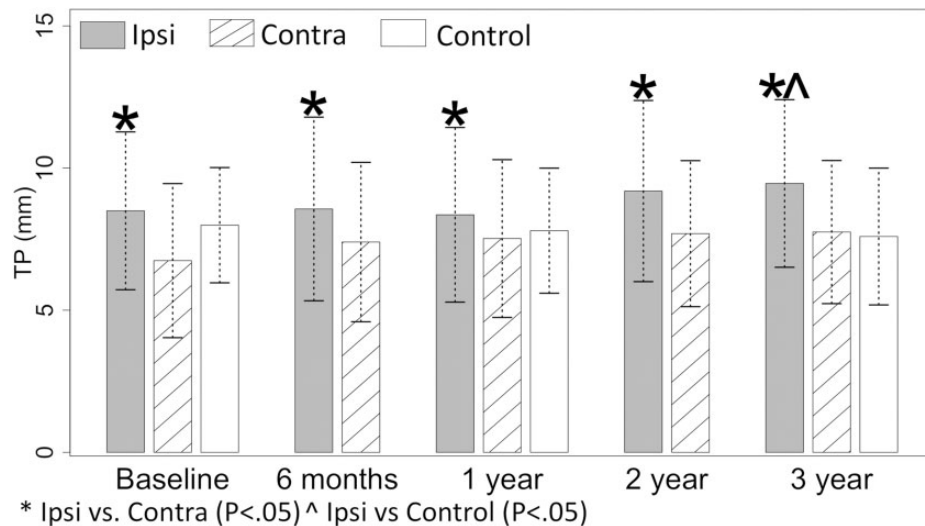
There were no significant baseline differences between the ACL group and control group with regard to age, sex ratio, body mass index, or Marx activity rating scale results.

### Tibial Position and Internal Tibial Rotation

The tibial position of ipsilateral, contralateral, and control knees at all time points are displayed in Figure 2. The mean tibial position of ipsilateral knees was more anterior than that of contralateral knees at all time points (baseline:  $P < .001$ ; 6 months:  $P = .002$ ; 1 year:  $P = .013$ ; 2 years:  $P < .001$ ; 3 years:  $P = .015$ ). Additionally, the mean tibial position of ipsilateral knees was more anterior than that of control knees at 3 years ( $P = .010$ ). The mean internal tibial rotation of ipsilateral knees was more internally rotated than that of contralateral knees at baseline only ( $P = .034$ ). There were no significant differences found between the mean internal tibial rotation of ipsilateral knees and that of control knees at any time point. Additionally, in the ACL group, there was no significant difference in the tibial position or internal tibial rotation between those who underwent partial meniscectomy and those who did not or between those who received an allograft and those who received an autograft at any time point.

### T1 $\rho$ and T2 Meniscal Relaxation Times of Injured Versus Noninjured Knees

The T1 $\rho$  and T2 relaxation times of the PHLAT and PHMED in ipsilateral, contralateral, and control knees at all time points are displayed in Figure 3. The mean T1 $\rho$  and T2 meniscal relaxation times of ipsilateral knees were higher than those of contralateral knees in the PHLAT at baseline, 6 months, and 1 year (baseline T1 $\rho$ :  $P = .001$ ; baseline T2:  $P = .003$ ; 6-month T1 $\rho$ :  $P = .030$ ; 6-month T2:  $P = .047$ ; 1-year T1 $\rho$ :  $P = .002$ ; 1-year T2:  $P = .020$ ) and in the PHMED at 6 months and 1 year (6-month T1 $\rho$ :  $P = .003$ ; 6-month T2:  $P = .003$ ; 1-year T1 $\rho$ :  $P = .008$ ; 1-year T2:  $P = .005$ ). Additionally, the mean T2 of ipsilateral knees was higher than that of contralateral knees in the AHLAT at baseline ( $P = .010$ ) and



**Figure 2.** Mean tibial position (TP) of ipsilateral (Ipsi), contralateral (Contra), and control knees at all time points. Ipsilateral knees were significantly ( $P < .05$ ) more anterior than contralateral knees at all time points and control knees at 3 years only. Error bars =  $\pm 1$  SD.

in the PHMED at baseline and 2 years (baseline:  $P = .009$ ; 2 years:  $P = .026$ ). There were no significant differences found between the mean  $T1\rho$  or  $T2$  in the AHMED of ipsilateral knees compared with the mean  $T1\rho$  or  $T2$  in the AHMED of contralateral knees.

#### $T1\rho$ and $T2$ Meniscal Relaxation Times of Injured Versus Control Knees

The mean  $T1\rho$  and  $T2$  meniscal relaxation times of ipsilateral knees were higher than those of control knees in the PHLAT at baseline and 1 year (baseline  $T1\rho$ :  $P < .001$ ; baseline  $T2$ :  $P < .001$ ; 1-year  $T1\rho$ :  $P = .009$ ; 1-year  $T2$ :  $P = .003$ ) and in the PHMED at 1 year ( $T1\rho$ :  $P = .012$ ;  $T2$ :  $P = .003$ ). Additionally, the mean  $T2$  of ipsilateral knees was higher than that of control knees in both the AHLAT at baseline ( $P = .018$ ) and in the PHMED at baseline ( $P < .001$ ). Unexpectedly, the mean  $T1\rho$  in the AHMED of ipsilateral knees was significantly lower than the mean  $T1\rho$  of control knees at baseline ( $P = .047$ ); this significant difference was not seen in the  $T2$  meniscal relaxation values. Additionally, in the ACL group, there was no significant difference in  $T1\rho$  or  $T2$  values between those who underwent partial meniscectomy and those who did not or between those who received an allograft and those who received an autograft in any meniscal region at any time point.

#### Analysis of $T1\rho$ and $T2$ of Control and Contralateral Knees as a Comparison Group

With regard to the use of contralateral and control knees as a stable comparison variable, the mean  $T1\rho$  and  $T2$  relaxation times of contralateral knees showed no significant changes between time points in all 4 meniscal regions. The mean  $T1\rho$  and  $T2$  relaxation times of control knees additionally showed no significant differences between time

points in any of the 4 meniscal regions, except in the AHMED. The mean  $T1\rho$  relaxation time in the AHMED of the control knees at baseline was  $19.1 \pm 1.4$  milliseconds, which was unexpectedly significantly higher than the mean  $T1\rho$  relaxation time of control knees at 1 year ( $17.5 \pm 2.2$  ms;  $P = .003$ ) and at 3 years ( $17.6 \pm 2.1$  ms;  $P = .004$ ).

#### Tibial Position and qMRI Regression

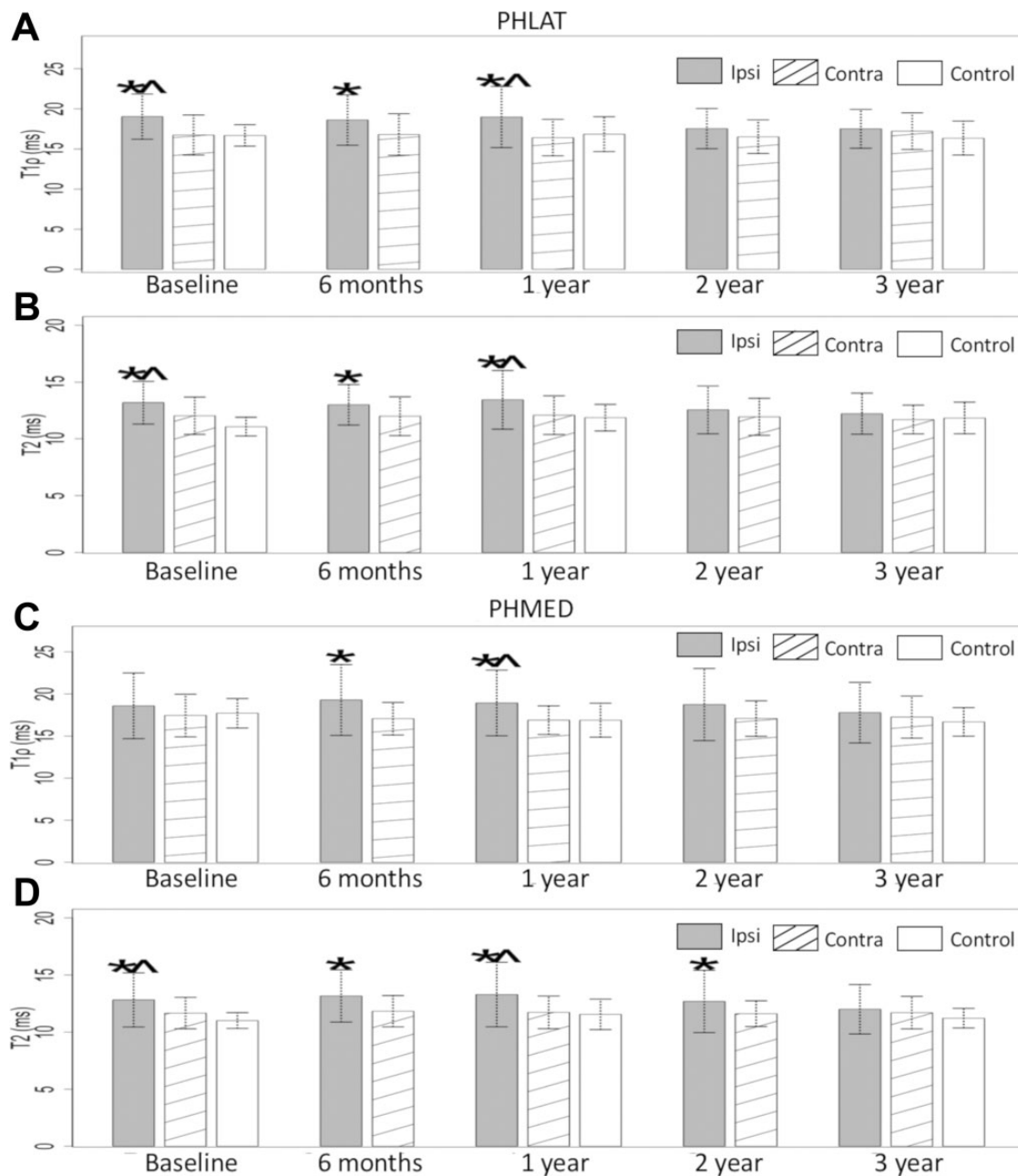
Multiple regression analysis showed that a more anterior tibial position at 3 years was associated with increasing  $T2$  values from baseline to 3 years in the PHMED ( $P = .031$ ) and AHMED ( $P = .040$ ). The  $T2$  changes from baseline to 3 years in the PHLAT and AHLAT of ipsilateral knees, also included in the same regression model, were not significant. Partial correlation plots in Figure 4 show positive associations between the significant variables.

#### DISCUSSION

Although ACL reconstruction clinically allows the restoration of normal activities 1 year postoperatively, more sensitive analysis via qMRI analyzed in this study reported a persistently altered tibial position after ACL reconstruction, as is consistent with the literature.<sup>29</sup> Although there are numerous studies analyzing alterations in tibiofemoral kinematics as they relate to the cartilage status, to our knowledge, this is the first study to show a correlation between the tibial position and sustained alterations in the meniscal matrix in a longer term follow-up after primary ACL reconstruction.<sup>2,15,43</sup>

#### Tibial Position and Internal Tibial Rotation

The tibial position of injured knees was more anterior than the tibial position of noninjured knees at all time points



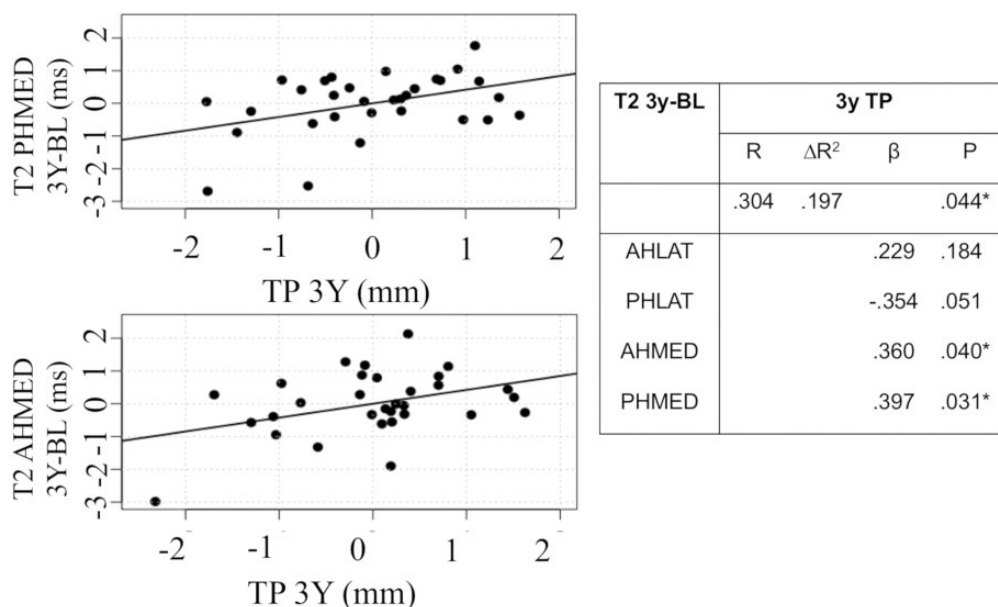
**Figure 3.** Mean relaxation values of all knees: (A) posterior horn of the lateral meniscus (PHLAT) T1 $\rho$ , (B) PHLAT T2, (C) posterior horn of the medial meniscus (PHMED) T1 $\rho$ , and (D) PHMED T2. Error bars =  $\pm 1$  SD. \*Ipsilateral (Ipsi) vs contralateral (Contra):  $P < .05$ . ^Ipsilateral vs control:  $P < .05$ .

( $P < .05$ ), as is consistent with the current understanding of the tibial position after ACL reconstruction.<sup>2,15,43</sup> Despite a persistently anterior tibial position, ACL reconstruction improved internal rotation of the ACL-deficient knee, as differences were only found at baseline. This finding, while consistent with previous studies conducted via qMRI, is contrary to other gait analysis studies that have demonstrated a persistently altered tibial rotation after ACL reconstruction.<sup>2,15,28,31,37</sup> The current literature suggests that knee kinematics can vary between low- and

high-demand activities in ACL-reconstructed knees, which may contribute to dissimilarities between the results of our study and those that used gait analysis.<sup>6,13,28</sup>

#### Quantitative MRI

T1 $\rho$  and T2 values of the menisci of ipsilateral knees showed prolonged elevations predominantly in the posterior portions of the meniscus: up to 1 year in the PHLAT and 2 years in the PHMED. Elevations in T1 $\rho$  and T2 were



**Figure 4.** Correlation plots from multiple regression analysis of the tibial position (TP) of ipsilateral knees at 3 years and changes in T2 values from baseline to 3 years of ipsilateral knees. One data point outlier was removed because of residual significant deviation ( $\geq 2$  SDs) from the mean of residuals. \* $P < .05$ .  $\beta$ , standardized regression coefficient,  $\Delta R^2$ , adjusted  $R^2$  value; AHLAT, anterior horn of the lateral meniscus; AHMED, anterior horn of the medial meniscus; PHLAT, posterior horn of the lateral meniscus; PHMED, posterior horn of the medial meniscus.

also seen before surgery with gradual improvement over time, demonstrating that there is an initial meniscal injury that persists in the short term after reconstruction, although it does improve over a longer follow-up. This gradual improvement in the meniscal status after ACL reconstruction has been demonstrated in other studies.<sup>9,18</sup> Chu et al<sup>9</sup> demonstrated in 11 patients who underwent ACL reconstruction and subsequent qMRI 2 years after reconstruction that ultrashort TE T2 values in the posterior medial meniscus decreased 17% to levels that did not significantly differ from those seen in uninjured controls. In addition, there was an unexpected finding of elevated mean T1 $\rho$  relaxation times in the AHMED of the control group at baseline, also reported in a previous analysis.<sup>40</sup> The same elevation was not seen in T2 relaxation times at baseline or in T1 $\rho$  or T2 relaxation times at 1 or 3 years. No differences were seen in the baseline Marx activity score of the control group, which may have helped explain this surprising observation. A separate analysis of the AHMED of noninjured participants could further elucidate this issue.

### Tibial Position and qMRI

An altered tibial position was correlated with increasing T2 values in the medial regions of the meniscus, and given that these correlations were associated over 3 years, it is likely that these changes are related to longer term outcomes as opposed to acute responses related to the initial insult, the chronic ACL-deficient state, or the immediate postoperative recovery period after ACL reconstruction. Alterations in the tibial position leading to increased loading of the

cartilage and the development of subsequent osteoarthritis are a well-researched phenomenon; however, an understanding of how alterations in loading affect meniscal abnormalities is still being elucidated.<sup>3,4,33,35</sup>

A proposed mechanism is that with persistent anterior translation of the tibia, the PHMED acts as a secondary restraint to translation, leading to increased contact forces and subsequent meniscal injuries. In a study by Guess and Razu,<sup>14</sup> computational multibody models of the knee generated from the medical images and recorded passive leg motion of 2 female participants predicted that loss of the ACL increased contact and hoop forces in the medial menisci by a factor of 4 when a 100-N anterior tibial force was applied. In Markolf et al,<sup>24</sup> in vitro analysis of 12 fresh-frozen knee specimens demonstrated increased forces on the PHMED attachment when a joint-loaded ACL-deficient knee was subjected to a 200-N anterior tibial force while flexed between 20° and 90°. Markolf et al<sup>24</sup> additionally postulated that increased shear forces can lead to the development of medial meniscal tears, limiting the ability of the meniscus to act as a secondary stabilizer and leading to further joint degeneration.

Additionally, despite finding correlations between the tibial position at 3 years and 3-year changes in the meniscal status, we did not find any significant differences between the mean T1 $\rho$  or T2 between the comparison groups and the ACL group at 3 years. Although no specific longitudinal comparison analysis was performed in this study, our multiple regression analysis suggests that there are patients who have an improved meniscal matrix 3 years after reconstruction but also a solid subset of patients that worsen 3 years after



reconstruction. In the regression analysis, more than half of the patients had positive residuals from T2 values in the PHMED from baseline to 3 years, suggesting that there may be additional factors contributing to worsening meniscal outcomes. Findings from this study encourage further longitudinal analyses to examine additional factors that may influence outcomes after ACL reconstruction.

## Limitations

This study has several limitations. The use of static qMRI, while previously proven to be sensitive for changes in the tibial position, cannot fully evaluate tibiofemoral joint changes during motion or higher activity levels, which may present with increased laxity, rotation, or translation of the knee. Additionally, the development of meniscal abnormalities as a result of tibial position alterations may take longer than 3 years, and thus, longer follow-ups are warranted.

## CONCLUSION

Results of the current study indicate that after ACL reconstruction, there is a persistently altered tibial position at 3-year follow-up, with an initial preoperative meniscal injury that shows prolonged but gradual improvement. Additionally, correlations between tibial position and changes in the medial meniscal matrix suggest that tibial position may play a role in the increased susceptibility to medial meniscal tears seen after reconstruction.

## REFERENCES

- Allen CR, Wong EK, Livesay GA, Sakane M, Fu FH, Woo SL. Importance of the medial meniscus in the anterior cruciate ligament-deficient knee. *J Orthop Res*. 2000;18(1):109-115.
- Amano K, Pedroia V, Su F, Souza RB, Li X, Ma CB. Persistent biomechanical alterations after ACL reconstruction are associated with early cartilage matrix changes detected by quantitative MR. *Orthop J Sports Med*. 2016;4(4):2325967116644421.
- Andriacchi TP, Koo S, Scanlan SF. Gait mechanics influence healthy cartilage morphology and osteoarthritis of the knee. *J Bone Joint Surg Am*. 2009;91(suppl 1):95-101.
- Andriacchi TP, Mündermann A, Smith RL, Alexander EJ, Dyrby CO, Koo S. A framework for the in vivo pathomechanics of osteoarthritis at the knee. *Ann Biomed Eng*. 2004;32(3):447-457.
- Bolbos RI, Link TM, Ma CB, Majumdar S, Li X. T1rho relaxation time of the meniscus and its relationship with T1rho of adjacent cartilage in knees with acute ACL injuries at 3 T. *Osteoarthritis Cartilage*. 2009;17(1):12-18.
- Bush-Joseph CA, Hurwitz DE, Patel RR, Bahrani Y, Bach BRJ, Andriacchi TP. Dynamic function after anterior cruciate ligament reconstruction with autologous patellar tendon. *Am J Sports Med*. 2001;29:36-41.
- Carballido-Gamio J, Bauer J, Lee KY, Krause S, Majumdar S. Combined image processing techniques for characterization of MRI cartilage of the knee. *Conf Proc IEEE Eng Med Biol Soc*. 2005;3:3043-3046.
- Carballido-Gamio J, Bauer JS, Stahl R, et al. Inter-subject comparison of MRI knee cartilage thickness. *Med Image Anal*. 2008;12:120-135.
- Chu CR, Williams AA, West RV, et al. Quantitative magnetic resonance imaging UTE-T2\* mapping of cartilage and meniscus healing after anatomic anterior cruciate ligament reconstruction. *Am J Sports Med*. 2014;42(8):1847-1856.
- Delincé P, Ghafil D. Anterior cruciate ligament tears: conservative or surgical treatment? A critical review of the literature. *Knee Surg Sports Traumatol Arthrosc*. 2012;20(1):48-61.
- Dunn WR, Lyman S, Lincoln AE, Amoroso PJ, Wickiewicz T, Marx RG. The effect of anterior cruciate ligament reconstruction on the risk of knee reinjury. *Am J Sports Med*. 2004;32(8):1906-1914.
- Fox AJ, Bedi A, Rodeo SA. The basic science of human knee menisci: structure, composition, and function. *Sports Health*. 2012;4(4):340-351.
- Georgoulis AD, Papadonikolakis A, Papageorgiou CD, Mitsou A, Stergiou N. Three-dimensional tibiofemoral kinematics of the anterior cruciate ligament-deficient and reconstructed knee during walking. *Am J Sports Med*. 2003;31(1):75-79.
- Guess TM, Razu S. Loading of the medial meniscus in the ACL deficient knee: a multibody computational study. *Med Eng Phys*. 2017;41:26-34.
- Haughom B, Schairer W, Souza RB, Carpenter D, Ma CB, Li X. Abnormal tibiofemoral kinematics following ACL reconstruction are associated with early cartilage matrix degeneration measured by MRI T1rho. *Knee*. 2012;19(4):482-487.
- Hoshino Y, Fu FH, Irrgang JJ, Tashman S. Can joint contact dynamics be restored by anterior cruciate ligament reconstruction? *Clin Orthop Relat Res*. 2013;471(9):2924-2931.
- Hunter DJ, Zhang YQ, Niu JB, et al. The association of meniscal pathologic changes with cartilage loss in symptomatic knee osteoarthritis. *Arthritis Rheum*. 2006;54(3):795-801.
- Knox J, Pedroia V, Wang A, et al. Longitudinal changes in MR T1rho/T2 signal of meniscus and its association with cartilage T1rho/T2 in ACL-injured patients. *Osteoarthritis Cartilage*. 2018;26(5):689-696.
- Kobayashi K, Nakayama Y, Shirai Y, Narita T, Mori A. Meniscal tears after anterior cruciate ligament reconstruction. *J Nippon Med Sch*. 2001;68(1):24-28.
- Lansdown DA, Zaid M, Pedroia V, et al. Reproducibility measurements of three methods for calculating in vivo MR-based knee kinematics. *J Magn Reson Imaging*. 2015;42:533-538.
- Leathers MP, Merz A, Wong J, Scott T, Wang JC, Hame SL. Trends and demographics in anterior cruciate ligament reconstruction in the United States. *J Knee Surg*. 2015;28(5):390-394.
- Lebel B, Hulet C, Galaud B, Burdin G, Locker B, Vielpeau C. Arthroscopic reconstruction of the anterior cruciate ligament using bone-patellar tendon bone autograft: a minimum 10-year follow-up. *Am J Sports Med*. 2008;36(7):1275-1282.
- Lohmander LS, Ostenberg A, Englund M, Roos H. High prevalence of knee osteoarthritis, pain, and functional limitations in female soccer players twelve years after anterior cruciate ligament injury. *Arthritis Rheum*. 2004;50(10):3145-3152.
- Markolf KL, Jackson SR, McAllister DR. Force measurements in the medial meniscus posterior horn attachment: effects of anterior cruciate ligament removal. *Am J Sports Med*. 2012;40(2):332-338.
- Nebelung S, Tingart M, Pufe T, Kuhl C, Jahr H, Truhn D. Ex vivo quantitative multiparametric MRI mapping of human meniscus degeneration. *Skeletal Radiol*. 2016;45(12):1649-1660.
- Prasad AP, Nardo L, Schooler J, Josep G, Link TM. T1rho and T2 relaxation times predict progression of knee osteoarthritis. *Osteoarthritis Cartilage*. 2013;21(1):69-76.
- Rauscher I, Stahl R, Cheng J, et al. Meniscal measurements of T1rho and T2 at MR imaging in healthy subjects and patients with osteoarthritis. *Radiology*. 2008;249(2):591-600.
- Ristanis S, Stergiou N, Patras K, Vasilidis HS, Giakas G, Georgoulis AD. Excessive tibial rotation during high-demand activities is not restored by anterior cruciate ligament reconstruction. *Arthroscopy*. 2005;21(11):1323-1329.
- Rodríguez-Roiz JM, Caballero M, Ares O, Sastre S, Lozano L, Popescu D. Return to recreational sports activity after anterior cruciate ligament reconstruction: a one- to six-year follow-up study. *Arch Orthop Trauma Surg*. 2015;135(8):1117-1122.

30. Rusinkiewicz S, Levoy M. Efficient variants of the ICP algorithm. In: *Proceedings of the International Conference on 3-D Digital Imaging and Modeling*. Quebec, Canada: IEEE; 2001:145-152.
31. Scanlan SF, Chaudhari AM, Dyrby CO, Andriacchi TP. Differences in tibial rotation during walking in ACL reconstructed and healthy contralateral knees. *J Biomech*. 2010;43(9):1817-1822.
32. Smith TO, Postle K, Penny F, McNamara I, Mann CJ. Is reconstruction the best management strategy for anterior cruciate ligament rupture? A systematic review and meta-analysis comparing anterior cruciate ligament reconstruction versus non-operative treatment. *Knee*. 2014; 21(2):462-470.
33. Stergiou N, Ristanis S, Moraiti C, Georgoulis AD. Tibial rotation in anterior cruciate ligament (ACL)-deficient and ACL-reconstructed knees: a theoretical proposition for the development of osteoarthritis. *Sports Med*. 2007;37(7):601-613.
34. Su F, Hilton JF, Nardo L, et al. Cartilage morphology and T1 $\rho$  and T2 quantification in ACL-reconstructed knees: a 2-year follow-up. *Osteoarthritis Cartilage*. 2013;21(8):1058-1067.
35. Suggs J, Wang C, Li G. The effect of graft stiffness on knee joint biomechanics after ACL reconstruction: a 3D computational simulation. *Clin Biomech (Bristol, Avon)*. 2003;18(1):35-43.
36. Sun Y, Mauerhan DR, Kneisl JS, et al. Histological examination of collagen and proteoglycan changes in osteoarthritic menisci. *Open Rheumatol J*. 2012;6:24.
37. Tashman S, Collon D, Anderson K, Kolowich P, Anderst W. Abnormal rotational knee motion during running after anterior cruciate ligament reconstruction. *Am J Sports Med*. 2004;32(4):975-983.
38. Theologis AA, Haughom B, Liang F, et al. Comparison of T1rho relaxation times between ACL-reconstructed knees and contralateral uninjured knees. *Knee Surg Sports Traumatol Arthrosc*. 2014;22(2): 298-307.
39. Titchenal MR, Chu CR, Erhart-Hledik JC, Andriacchi TP. Early changes in knee center of rotation during walking after anterior cruciate ligament reconstruction correlate with later changes in patient-reported outcomes. *Am J Sports Med*. 2017;45(4):915-921.
40. Wang A, Pedroia V, Su F, et al. MR T1 $\rho$  and T2 of meniscus after acute anterior cruciate ligament injuries. *Osteoarthritis Cartilage*. 2016;24(4): 631-639.
41. Wang X, Wang Y, Bennell KL, et al. Cartilage morphology at 2-3 years following anterior cruciate ligament reconstruction with or without concomitant meniscal pathology. *Knee Surg Sports Traumatol Arthrosc*. 2017;25(2):426-436.
42. Williams A, Qian Y, Chu CR. UTE-T2\* mapping of human articular cartilage in vivo: a repeatability assessment. *Osteoarthritis Cartilage*. 2011;19(1):84-88.
43. Zaid M, Lansdown D, Su F, et al. Abnormal tibial position is correlated to early degenerative changes one year following ACL reconstruction. *J Orthop Res*. 2015;33(7):1079-1086.