

# UC Davis

## Dermatology Online Journal

### Title

Additive effect of propranolol and pulsed dye laser for infantile hemangioma

### Permalink

<https://escholarship.org/uc/item/8852k72j>

### Journal

Dermatology Online Journal, 19(6)

### Authors

Herschthal, Jordana  
Wulkan, Adam  
George, Manju  
et al.

### Publication Date

2013

### DOI

10.5070/D3196018570

### Copyright Information

Copyright 2013 by the author(s). This work is made available under the terms of a Creative Commons Attribution-NonCommercial-NoDerivatives License, available at <https://creativecommons.org/licenses/by-nc-nd/4.0/>

Peer reviewed

## Case Report

### Additive effect of propranolol and pulsed dye laser for infantile hemangioma

Jordana Herschthal MD<sup>1</sup>, Adam Wulkan MD<sup>1,2</sup>, Manju George MD<sup>3</sup>, Jill Waibel MD<sup>1,2</sup>

Dermatology Online Journal 19 (6): 13

<sup>1</sup>Miami University of Miami Miller School of Medicine, University of Miami, Miller School of Medicine  
Department of Dermatology & Cutaneous Surgery

<sup>2</sup>Dermatology & Laser Institute, Department of Dermatology & Cutaneous Surgery

<sup>3</sup>Pediatric Dermatology West Palm Beach

#### Correspondence:

Adam J Wulkan

Miami Dermatology & Laser Institute

7800 SW 87<sup>th</sup> Avenue

Suite B200

Miami, FL 33173

Office: 305.279.6060

Fax: 305.279.6548

[AJWulkan@med.miami.edu](mailto:AJWulkan@med.miami.edu)

## Abstract

The combination of propranolol and pulsed dye laser for the treatment of infantile hemangiomas may be superior to either alone. This case report illustrates the additive effect of propranolol and pulsed dye laser for an infantile hemangioma in a high-risk location. Although thorough clinical trials are needed, combination therapy for infantile hemangiomas may prove to be optimal for efficacy.

## Introduction

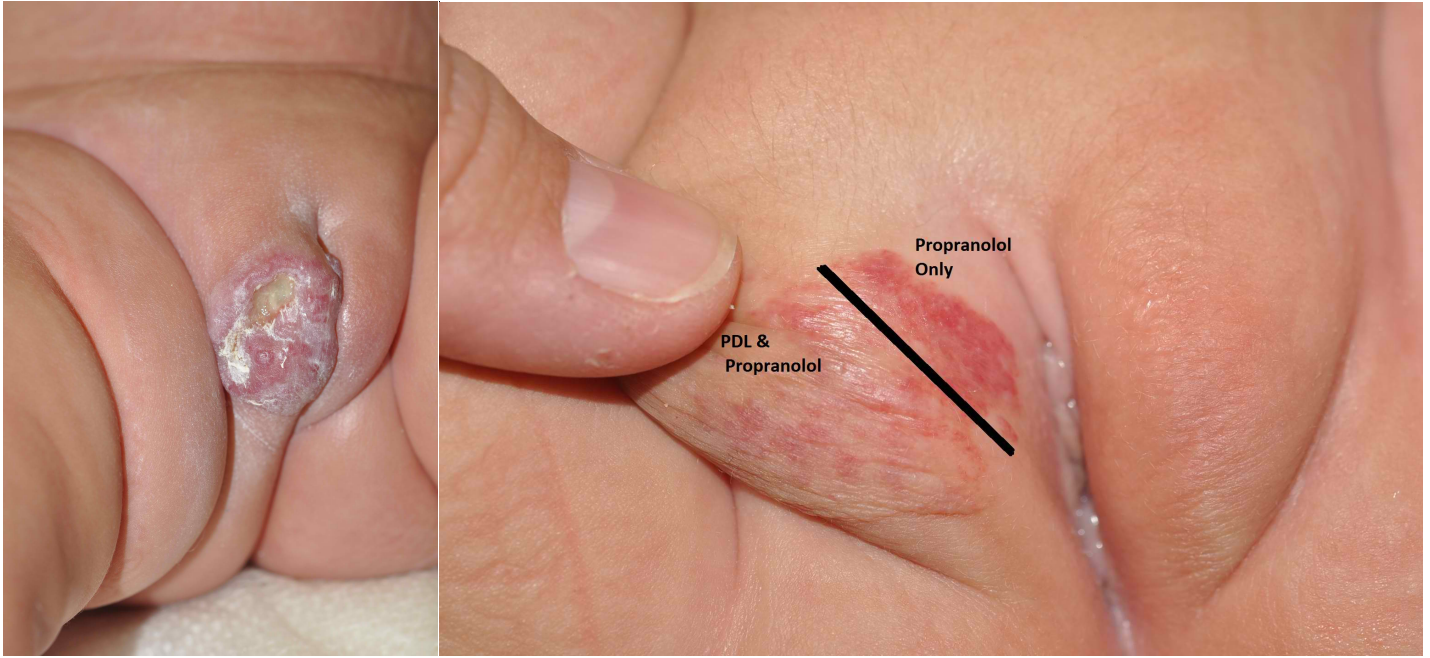
Infantile hemangiomas (IHs) are among the most common vascular tumors in childhood [1]. Whereas 90% of IHs follow a benign course of rapid growth and spontaneous involution, early treatment is preferred owing to potential complications such as ulceration, infection, scarring, and functional impairment, especially in high-risk locations [1,2]. If untreated, significant psychological and physiologic sequelae can occur in both the patient and family.

Several treatment modalities exist including topical, systemic, laser, and surgical approaches. At present, there is controversy regarding whether pulsed dye laser (PDL) treatment is better than a wait-and-see policy [3,4,5,6]. Leaute-Labreze et al. first reported the efficacy of propranolol for severe infantile hemangiomas in 2008 [7]. Recent evidence suggests propranolol is superior to corticosteroids for complicated IHs. [2] PDL has also been successful for complicated IHs [3]. Currently, there is no consensus on whether IHs should be treated with propranolol alone, PDL alone, or a combination of the two.

## Case Report

A 9-week-old girl presented for evaluation of a rapidly growing and ulcerated IH on her right labia majora. The patient was born prematurely at 32 weeks and was monitored in the neonatal intensive care unit for 24 days. No prior treatment had been administered for the hemangioma.

Upon presentation, the examination revealed a 4 X 2.4cm ulcerating hemangioma involving the right labia majora (Figure 1A). After an extensive discussion of the risks and benefits of different treatment modalities, a decision to treat with both the 595-nm pulsed-dye laser (Vbeam Perfecta; Candela Corp., Wayland, MA) with 30:20 cooling (Dynamic Cooling Device, Candela Corp., Wayland, MA) and systemic propranolol (1.5 mg/kg/day) was made because of the size and high-risk location of the hemangioma. Treatment with PDL (7.25 J/cm<sup>2</sup>/1.5ms/7mm) was initiated on the day of evaluation. The patient was also initiated on propranolol therapy after cardiac clearance shortly after the first PDL treatment for concerns of progressive ulceration and pain.



**Figure 1a:** Right labial hemangioma on initial clinic visit. **Figure 1b:** After two PDL treatments illustrating additive effect between PDL and propranolol. The more erythematous portion of the inner labia had not received PDL treatment.

Improvement was noted at 2 weeks follow-up. A second treatment with PDL (7.25 J/cm<sup>2</sup>/1.5ms/7mm) was performed at this time and the patient was continued on 1.5 mg/kg/day of propranolol. The hemangioma significantly improved at 6 weeks and measured 3 x 2.2cm. Follow-up evaluation that day also revealed an area on the inner labia majora that was not as improved as compared to the outer labia majora (Figure 1B). This related to failure to retract the labia majora during treatment with the PDL, thus leaving an area that only received propranolol for treatment. The clear demarcation between the outer labia (treated with the combination of PDL and propranolol) compared to the inner labia (treated with propranolol alone) suggests that there may be an improvement with combination PDL and propranolol therapy. A third PDL treatment (8 J/cm<sup>2</sup>/1.5ms/7mm) was performed and the propranolol was increased to 2 mg/kg/day. Two more treatments of PDL at 10 weeks and 5 months were performed (8-8.5 J/cm<sup>2</sup>) with propranolol maintained at 2 mg/kg/day.

Following the 5 treatments with PDL and increasing doses of propranolol, the hemangioma dramatically decreased in size and improved in appearance. The family was very pleased with both the cosmetic outcome and lack of functional impairment (Figure 1C, 1D).

## Conclusion

We report a case of a high-risk IH treated with a combination of propranolol and PDL with significant improvement compared to propranolol alone. There is a growing trend in dermatologic therapeutics to combine laser and drugs in various approaches for increased efficacy. A determination of whether or not the combination proves to be superior to either treatment alone and the ideal laser parameters for combination therapy should be determined in a clinical trial. Future clinical trials to determine if PDL is the optimal laser for combination with propranolol should also be performed to further advance treatment for this potentially disfiguring tumor.

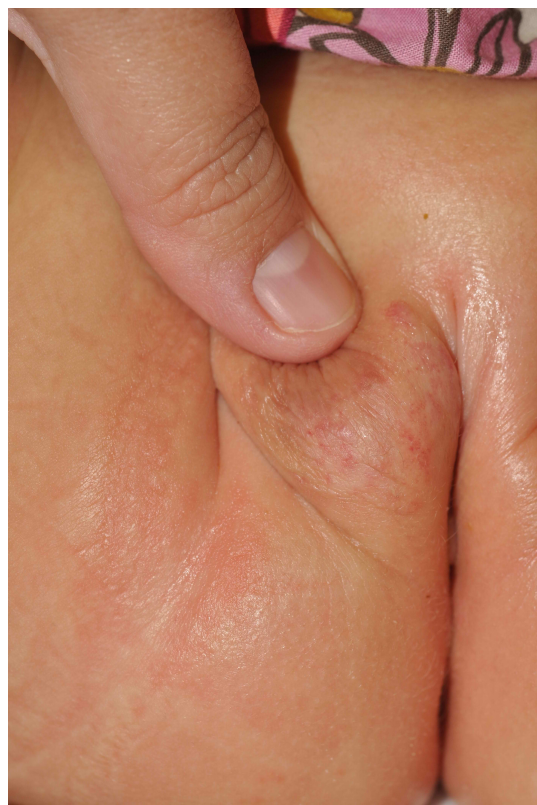
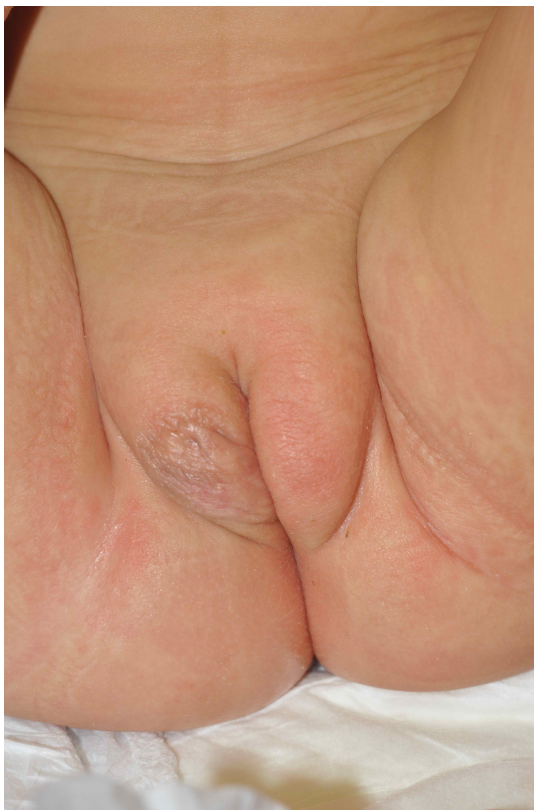
Figure 1c: Right labial hemangioma after five PDL treatments. Figure 1d: Right labial hemangioma (retracted) after five PDL treatments.

## References

1. Akhavan A, Zippin JH. Current treatments for infantile hemangiomas. *J Drugs Dermatol*. 2010;9:176-180. PMID: 20214185
2. Price CJ, Lattouf C, Baum B, et al. Propranolol vs corticosteroids for infantile hemangiomas. *Arch Dermatol*. 2011. [PMID: 21844428]
3. Hunzeker CM, Geronemus RG. Treatment of superficial infantile hemangiomas of the eyelid using the 595-nm pulsed dye laser. *Dermatol Surg*. 2010;36:590-597. [PMID: 20384759]
4. C. Rizzo, L. Brightman, A.M. Chapas, E.K. Hale, J.L. Cantatore-Francis, L.J. Bernstein, R.G. Geronemus, Outcomes of childhood hemangiomas treated with the pulsed-dye laser with dynamic cooling: a retrospective chart analysis. *Dermatol Surg* 35 (2009) 1947-1954. [PMID: 19889007]
5. R.G. Geronemus, A.N. Kauvar, The pulsed-dye laser for infantile hemangiomas. *Plast Reconstr Surg* 97 (1996) 1302-1303. [PMID: 8628815]
6. J.P Kessels, E.T. Hamers, JU Ostertag. Superficial Hemangioma: Pulsed Dye Laser Versus Wait-and-See. *Dermatologic Surgery*. (2013) 414-421. [PMID: 23279058]
7. C. Leaute-Labreze, E. Dumas de la Roque, T. Hubiche, F. Boralevi, J.B. Thambo, A. Taieb, Propranolol for severe hemangiomas of infancy. *N Engl J Med* 358 (2008) 2649-261. [PMID: 18550886]