

# UC Davis

## UC Davis Previously Published Works

### Title

A comparison of retrobulbar and two peribulbar regional anesthetic techniques in dog cadavers

### Permalink

<https://escholarship.org/uc/item/8841928m>

### Journal

Veterinary Anaesthesia and Analgesia, 44(4)

### ISSN

1467-2987

### Authors

Shilo-Benjamini, Yael  
Pascoe, Peter J  
Wisner, Erik R  
et al.

### Publication Date

2017-07-01

### DOI

10.1016/j.vaa.2017.02.009

Peer reviewed

## RESEARCH PAPER

## A comparison of retrobulbar and two peribulbar regional anesthetic techniques in dog cadavers

Yael Shilo-Benjamini<sup>a</sup>, Peter J Pascoe<sup>b</sup>, Erik R Wisner<sup>b</sup>, Nili Kahane<sup>a</sup>, Philip H Kass<sup>c</sup> & David J Maggs<sup>b</sup>

<sup>a</sup>Koret School of Veterinary Medicine, The Robert H Smith Faculty of Agriculture, Food and Environment, Hebrew University of Jerusalem, Jerusalem, Israel

<sup>b</sup>Department of Surgical and Radiological Sciences, School of Veterinary Medicine, University of California Davis, Davis, CA, USA

<sup>c</sup>Department of Population Health and Reproduction, School of Veterinary Medicine, University of California Davis, Davis, CA, USA

**Correspondence:** Yael Shilo-Benjamini, Koret School of Veterinary Medicine, Robert H Smith Faculty of Agriculture, Food and Environment, Hebrew University of Jerusalem, P.O. Box 12, Rehovot 7610001, Israel. E-mail: [shilo.yael@gmail.com](mailto:shilo.yael@gmail.com)

### Abstract

**Objective** To compare injectate distribution and likelihood of regional anesthesia to the orbit following retrobulbar (RB) or peribulbar (PB) injections in dog cadavers.

**Study design** Randomized, masked study.

**Animals** Twenty-four dog cadavers (aged 5.5–17 years, 2.0–36.3 kg).

**Methods** Orbits underwent one of three injection techniques with bupivacaine 0.5% and iohexol (1:1): ventrolateral RB injection (1–2 mL; 15 orbits), medial canthal PB injection (2–8 mL; PB-1; 16 orbits), or dorsomedial and ventrolateral PB injections (each 1–4 mL; PB-2; 16 orbits). The likelihood of successful regional anesthesia was estimated based on computed tomographic images scored for injectate volume of distribution at the base and within the extraocular muscle cone (EOMC), and injectate distribution around the optic nerve. Intraocular pressure (IOP) was measured before and after injections. Mixed-effects linear regression with *post hoc* Bonferroni contrast adjustments was performed. Significance was set at 0.05.

**Results** A difference in injectate volume of distribution within or at the base of the EOMC was not detected among groups. The median optic nerve

circumference of injectate distribution was significantly higher in the RB injected group than in the PB-2 group. Injectate distribution following RB, PB-1 and PB-2 injections was graded as likely to provide regional anesthesia within the EOMC in 40%, 19% and 31% of eyes, and at the EOMC base in 60%, 63% and 50% of eyes, respectively. The probability of likelihood to provide regional anesthesia was lower in dogs of higher body weights. The IOP was significantly higher than baseline following PB-1 ( $18 \pm 14$  mmHg) and in comparison with RB ( $2 \pm 3$  mmHg), but not different from PB-2 injection ( $10 \pm 11$  mmHg).

**Conclusions and clinical relevance** None of the techniques reliably produced 'successful' injectate distribution based on this study's definitions; however, clinical assessment of anesthetic success is required.

**Keywords** canine, peribulbar anesthesia, regional ocular anesthesia, retrobulbar anesthesia.

### Introduction

In humans, retrobulbar (RB) anesthesia [injection of local anesthetic into the extraocular muscle cone (EOMC)] and peribulbar (PB) anesthesia (injection of local anesthetic outside the EOMC) produce excellent perioperative analgesia and extraocular muscle

akinesia, and protect against the oculocardiac reflex (Ghali & El Btarny 2010). The PB injection may provide better analgesia for periorbital structures, and may be safer as the needle is introduced extraconally and is less likely to cause injury to nerves and vessels that pass inside the cone (Nouvellon et al. 2010).

It has been proposed that in dogs the RB injection provides better distribution into the orbital muscle cone than does PB injection (Accola et al. 2006). However, in that study, the injectate volume for both techniques was 2 mL, whereas in humans the volume used for PB anesthesia is 2–4 times that used for RB anesthesia (Nouvellon et al. 2010). Therefore, the goals of the present study were to develop a reliable method for PB injectate delivery, to describe potential complications of two PB injection techniques and to compare, in dog cadavers, the injectate volume of distribution achieved using these two PB techniques *versus* the distribution achieved using the more commonly used RB injection technique (Accola et al. 2006; Giuliano 2008; Hazra et al. 2008; Myrna et al. 2010). Our hypothesis was that the distribution of injectate produced by PB and RB techniques would be similar.

## Materials and methods

### Preliminary investigation

To establish the injection site and the injectate volume required for PB injections, a pilot study was conducted in five dogs with terminal illnesses that were euthanized and the bodies donated by their owners for unrestricted use. Cadavers were positioned in sternal recumbency with the head elevated on a triangular block of foam to provide easy access for the injection and a good position for imaging.

A 1:1 mixture (by volume) of bupivacaine 0.5% (Kamacaine 0.5%; Kamada, Israel) and an iodinated contrast agent, iohexol (Omnipaque 300; GE Healthcare, Ireland), formed the injectate. The volume injected in each orbit was increased in 0.2 mL kg<sup>-1</sup> increments from 0.2 to 0.8 mL kg<sup>-1</sup>. Computed tomography (CT) was performed to assess injectate distribution. The total volume required for optimal injectate distribution increased nonlinearly with body size. Thus, an allometric equation was developed to calculate the volume required per orbit based on dog body weight (BW) in kg:  $2.33 \times BW^{0.33}$ . In addition, injections were

performed at four injection sites: ventrolateral, dorsomedial, medial canthus and ventrolateral and dorsomedial combined. The medial canthal injection site and the combined ventrolateral and dorsomedial injection sites appeared to provide the best injectate distribution and were used in the present study.

### Study design

Cadavers of 24 dogs with terminal illnesses that were euthanized and donated by their owners for unrestricted use were used. All cadavers were kept at room temperature. Each orbit of all dogs was randomly assigned ([www.random.org/lists/](http://www.random.org/lists/)) to one of three injections: an RB injection (group RB), a single PB injection at the medial canthus (group PB-1) and two PB injections, one each in the ventrolateral and dorsomedial orbit (group PB-2). This study used the same injectate mixture that was evaluated in the preliminary study.

### Injection techniques

The RB injections were performed using a technique similar to that described by Accola et al. (2006). A 22 gauge, 8.9 cm spinal needle (Shanghai KDL Co. Ltd, Shanghai, China) was bent at the proximal end to achieve an angle of approximately 20°. The needle was inserted through the inferior eyelid at the junction of its middle and temporal thirds, and advanced until a slight popping sensation was detected. The needle was then directed slightly dorsally and nasally toward the apex of the orbit and advanced several millimeters further (depending on the dog's size). Once the needle tip was believed to be in an intraconal location, and after negative aspiration of blood or fluids was obtained, the entire volume was injected, either 1 mL ( $\leq 10$  kg) or 2 mL ( $> 10$  kg).

The PB injections were performed with a 25 gauge, 1.6 cm needle (DYN Medical Equipment Ltd, Israel) inserted through the eyelid and advanced to its full length in close proximity to the wall of the orbit. For both PB injections, the formula  $2.33 \times BW^{0.33}$  mL was used. For PB-1 injections, the needle was inserted at the medial canthus, and the entire calculated volume was injected. For PB-2 injections, one needle was inserted through the inferior eyelid at the ventrolateral region and the second needle was inserted through the superior eyelid at the

dorsomedial region, and the total volume was divided equally between the two injection sites. Negative pressure was obtained on aspiration prior to all injections, and a slight forward pressure was applied to the needle during injection to ensure that it remained in the desired location.

One anesthesiologist performed all injections (YSB). For all techniques, injections were performed with the bevel of the needle oriented toward the globe. Intraocular pressure (IOP) was estimated using applanation tonometry (Tono-Pen Vet; Reichert Technologies, NY, USA) before, immediately after and 10 minutes after each injection.

### Injectate distribution assessment

Before and 10 minutes after each injection, CT was performed (Philips MX8000 IDT; Philips Medical Systems Technologies Ltd, OH, USA), and a board-certified veterinary radiologist (ERW), who was unaware of the injection technique, assessed the volume of distribution of the local anesthetic–contrast mixture. Digital images [digital imaging and communication in medicine (DICOM)] were reviewed on a workstation with commercially available medical imaging software (eFilm; MERGE Healthcare, IL, USA), and the images were reformatted as necessary to enable viewing of dorsal and oblique anatomic planes.

Apparent injectate volume of distribution at the base of the EOMC (where the optic nerve emerges from the skull) and within the EOMC (intraconally) were each assigned a score (0 = none, 1 = moderate, 2 = large). In addition, the circumference of the optic nerve contacted by injectate was estimated to be approximately 0°, 90°, 180°, 270° or 360°. The likelihood of adequate regional anesthesia was estimated as likely, possible, or unlikely using two definitions. The first definition used the intraconal distribution score and the circumference of the optic nerve contacted by injectate: likely, when the intraconal distribution score was 2 and the extent of optic nerve contact was 270–360°; possible, when the intraconal distribution score was 1 and extent of optic nerve contact was 90–180°; and unlikely, when the intraconal distribution score was 0 and extent of optic nerve contact was 0°. The second definition for estimating adequate regional anesthesia used only the distribution score at the base of the EOMC: likely, when the score was 2; possible, when the score was 1; and unlikely, when the score was 0.

### Statistical analysis

Mixed-effects linear regression was used to model the potential effect of injection technique on IOP and on volume of distribution scores. The individual dog was treated as a random effect, and fixed effects included orbit and injection type. A square root transformation of IOP was used to make the distribution of residuals better conform with normality. *Post hoc* comparisons of injection types were adjusted for multiple comparisons using the Bonferroni procedure. Mixed-effects ordinal logistic regression was used to evaluate the relationship between BW category ( $\leq$  or  $>20$  kg) and injection type on the likelihood of achieving clinically successful anesthesia within or at the base of the EOMC. The proportions of orbits with injectate distribution judged likely to provide adequate regional anesthesia were presented with exact 95% binomial confidence intervals. For all analyses, *p* values  $< 0.05$  were considered significant.

### Results

Twenty-four fresh dog cadavers, consisting of 13 females (nine ovariectomized) and 11 males (six castrated), were used. Mean  $\pm$  standard deviation (SD) (range) age and BW were  $12.0 \pm 2.7$  (5.5–17.0) years and  $20.1 \pm 11.1$  (2.0–36.3) kg, respectively. The mean  $\pm$  SD (range) time from euthanasia to injection was  $107 \pm 57$  (40–265) minutes. Each injection technique was performed on 16 orbits; however, one injection in RB lacked a contrast agent, and this orbit was omitted from all analyses. During the PB-1 injection, the needle was inserted into the third eyelid or its gland in three out

**Table 1** Mean  $\pm$  standard deviation (range) for intraocular pressure (mmHg) before (baseline), immediately after, and 10 minutes after retrobulbar (RB; 1–2 mL injectate, *n* = 15), medial canthal peribulbar (PB-1; 2–8 mL injectate, *n* = 16) or ventrolateral and dorsomedial peribulbar (PB-2; 2–8 mL injectate, *n* = 16) injections of a 1:1 mixture by volume of iohexol and 0.5% bupivacaine into 47 orbits of 24 dog cadavers

Group	Time points		
	Before injection	Immediately after injection	Ten minutes after injection
RB	1 $\pm$ 1 (0–4)	2 $\pm$ 3 (0–8)	1 $\pm$ 3 (0–10)
PB-1	0 $\pm$ 1 (0–4)	18 $\pm$ 14 (0–46)*, †	5 $\pm$ 6 (0–21)
PB-2	1 $\pm$ 2 (0–5)	10 $\pm$ 11 (0–42)	3 $\pm$ 5 (0–15)

\* Significantly different from RB at the same time point (*p* < 0.05).

† Significantly different from baseline (*p* < 0.05).

**Table 2** Median (range) distribution scores following retrobulbar (RB; 1–2 mL injectate, *n* = 15), medial canthal peribulbar (PB-1; 2–8 mL injectate, *n* = 16) or ventrolateral and dorsomedial peribulbar (PB-2; 2–8 mL injectate, *n* = 16) injections of a 1:1 mixture of iohexol and 0.5% bupivacaine into 47 orbits of 24 dog cadavers. One observer, unaware of the group assignment, scored computed tomographic images for injectate volume of distribution within and at the base of the extraocular muscle cone (EOMC) (0 = none, 1 = moderate or 2 = large) and the circumference of the optic nerve with which injectate came in contact (0°, 90°, 180°, 270° or 360°)

Group	Volume of distribution score within EOMC (0–2)	Optic nerve circumference contacted (°)	Volume of distribution score at the EOMC base (0–2)
RB	2 (0–2)	180 (0–360)*	2 (0–2)
PB-1	1 (0–2)	90 (0–360)	2 (0–2)
PB-2	1 (0–2)	0 (0–360)	1.5 (0–2)

\*Significantly different from PB-2 (*p* < 0.05).

of 16 (19%) orbits; in two of these cases, the malposition was noticed immediately and the needle was repositioned. With all three cases, only part of the volume was injected into the third eyelid area. Subjectively, exophthalmos was evident following all PB-1 and most PB-2 injections (14 out of 16 orbits).

The IOP values prior to injection ranged from 0 to 5 mmHg and were below the physiologic range

(Table 1). Immediately following injection, IOP increased significantly from baseline in PB-1, and was significantly different between PB-1 and RB (*p* < 0.001), but not between RB and PB-2 (*p* = 0.077) or between PBA-1 and PB-2 (*p* = 0.171). At 10 minutes after injection, the mean IOP returned toward baseline values in all eyes, except one—in PB-1 that remained at 21 mmHg.

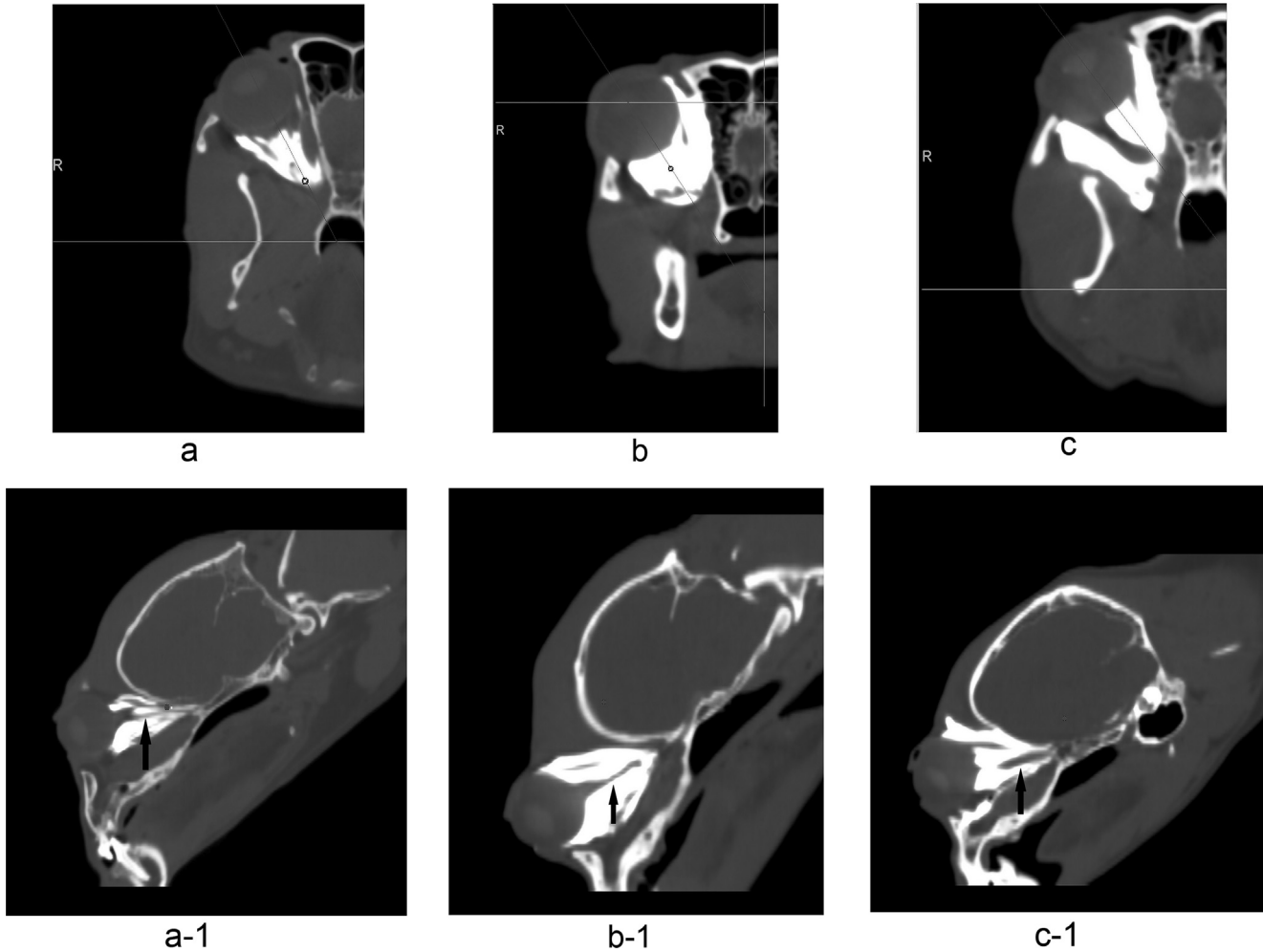
Scores for injectate volume of distribution within and at the base of the EOMC and around the optic nerve had variable ranges with all techniques (Table 2). The injectate distribution around the optic nerve was significantly less in PB-2 than in RB (*p* = 0.025). Injectate distribution considered likely or possible to result in adequate regional anesthesia was achieved using all three injection techniques regardless of whether the intraconal or base of the EOMC definition was used (Fig. 1). The number of dogs in which such results were achieved varied depending on technique and definition used (Table 3). Regardless of whether the intraconal or EOMC base definition was used, no technique provided better probability for achieving adequate regional anesthesia as defined. For all techniques, the probability of likely to achieve regional anesthesia was higher in dogs weighing ≤20 kg; however, this difference was significant only when using the intraconal distribution definition (Table 4; *p* = 0.015).

No CT evidence of intraocular, intravascular, intrathecal or intraneural injectate deposition was detected following any of the injections.

**Table 3** Number (percentage) of orbits in which adequate regional anesthesia was considered likely or possible based upon distribution of a 1:1 mixture by volume of iohexol and 0.5% bupivacaine and detected intraconally or at the base of the extraocular muscle cone (EOMC) using computed tomography. Injections were performed in 47 orbits of 24 dog cadavers: retrobulbar (RB; 1–2 mL injectate, *n* = 15), medial canthal peribulbar (PB-1; 2–8 mL injectate, *n* = 16) or ventrolateral and dorsomedial peribulbar (PB-2; 2–8 mL injectate, *n* = 16)

Parameter	Group	Estimated adequacy of nerve block			
		Likely	CI	Possible	CI
Intraconal distribution and optic nerve circumference					
	RB	6 (40%)	18–65%	5 (33%)	13–59%
	PB-1	3 (19%)	5–43%	6 (38%)	17–62%
	PB-2	5 (31%)	12–56%	0 (0%)	0–31%
EOMC base distribution					
	RB	9 (60%)	32–78%	3 (20%)	5–45%
	PB-1	10 (63%)	38–83%	4 (25%)	9–50%
	PB-2	8 (50%)	27–73%	4 (25%)	9–50%

Likely, intraconal distribution score of 2 and extent of optic nerve contact 270–360°, or an EOMC base distribution score of 2; possible, intraconal distribution score of 1 and extent of optic nerve contact 90–180°, or an EOMC base distribution score of 1. CI, confidence interval.



**Figure 1** Transverse plane (a, b and c) and reformatted, sagittal oblique plane (a-1, b-1 and c-1) computed tomography (CT) images of the right orbit of three dog cadavers following injections of 1:1 mixture of iodinated contrast agent (iohexol) and 0.5% bupivacaine. Arrows in a-1, b-1 and c-1 demonstrate the optic nerve in long axis. (a) A 14 year old, female, 11 kg mixed-breed dog was administered 2 mL of injectate via a retrobulbar injection. (b) A 15 year old, female, 10 kg Dachshund was administered 5 mL of injectate via a single medial canthal peribulbar injection. (c) An 11 year old, male, 7 kg mixed-breed dog was administered 4.5 mL of injectate via paired peribulbar injections at ventrolateral and dorsomedial sites. For all CT images shown, the injectate volume of distribution within and at the base of the extraocular muscle cone was scored as 2, and the injectate contact area with the optic nerve was estimated as 360° (i.e. the highest score for each parameter assessed).

**Table 4** Number (percentage) of orbits from dogs weighing  $\leq 20$  or  $>20$  kg that computed tomography identified distribution of a 1:1 mixture by volume of iohexol and 0.5% bupivacaine intraconally and around the optic nerve or at the base of the extraocular muscle cone (EOMC). Injections were made into 47 orbits of 24 dog cadavers: retrolubar (RB; 1–2 mL injectate,  $n = 15$ ), medial canthal perilubar (PB-1; 2–8 mL injectate,  $n = 16$ ) or ventrolateral and dorsomedial perilubar (PB-2; 2–8 mL injectate,  $n = 16$ )

Parameter	Group	Body weight	
		$\leq 20$ kg	$>20$ kg
Intraconal distribution and optic nerve circumference			
	RB	5/8 (63%)	1/7 (14%)
	PB-1	3/7 (43%)	0/9 (0%)
	PB-2	5/11 (46%)	0/5 (0%)
	All groups	13/26 (50%)*	1/21 (0.05%)
EOMC base distribution			
	RB	5/8 (63%)	4/7 (57%)
	PB-1	6/7 (86%)	4/9 (44%)
	PB-2	6/11 (55%)	2/5 (40%)
	All groups	17/26 (65%)	10/21 (48%)

\*Significantly different from  $>20$  kg ( $p < 0.05$ ).

## Discussion

In the present study, none of the injection techniques reliably delivered intraconal injectate with distribution scores the authors believed necessary to likely produce adequate regional anesthesia. The first report of PB injectate distribution in dogs used four cadaver orbits each injected with 2 mL of latex material divided between two injection locations (1 mL per location): dorsal (superior) and ventral (inferior) (Accola et al. 2006). These were deemed unsuccessful, and were omitted from further investigation. In comparison with findings in dogs by Accola et al. (2006), distribution of 6 mL of colored latex within the EOMC following PB injections was considered excellent in 10 orbits of human cadavers (Ripart et al. 2001). Likewise, CT evidence in cats suggested that PB injection of 4 mL bupivacaine combined with a contrast agent achieved excellent intraconal delivery in 11 out of 13 cat cadaver orbits (Shilo-Benjamini et al. 2013). The lack of success by Accola et al. (2006) may be related to the small volume of injectate and/or the injection location. A larger volume of injectate is required for diffusion into the EOMC when using the PB technique (Nouvellon et al. 2010). In addition, since the canine orbit is open laterally and somewhat open dorsally (Evans 1993; Miller 2013), some injectate may diffuse peripherally instead of

caudally. In the present study, despite the use of a larger volume and selection of injection points where the orbit is more closed, the intraconal distribution still was not consistent. For this reason, the likelihood of achieving adequate regional anesthesia was evaluated at the EOMC base in addition to the EOMC space. At the EOMC base, the ophthalmic branch of the trigeminal nerve emerges from the orbital fissure, which is adjacent to the optic nerve as it emerges from the optic foramen (Evans & Kitchell 1993). Therefore, we hypothesized that although the intraconal distribution was lacking, if the base of the EOMC had a good distribution of injectate, then it is likely to provide regional anesthesia to the orbit. Differences in injectate distribution seen in dogs, humans and cats may be attributed to species differences. For example, humans are purported to have no membrane between the extraconal and intraconal spaces; thus, local anesthetic solution can diffuse easily from one space to the other (Ripart et al. 2001). By contrast, dogs have retractor bulbi muscles in this location, which may alter injectate distribution relative to humans who lack retractor bulbi muscles (Miller 2013). However, the presence of retractor bulbi muscles in dogs does not explain the difference in intraconal distribution between dogs and cats, as these muscles are present in cats.

Although projected clinical success following PB injections in the present study was low, a recent experimental study in 15 dogs (30 orbits) reported clinical success (measured by decreased corneal sensitivity) following PB injection of 0.3 mL kg<sup>-1</sup> of 1% ropivacaine injected via a ventrolateral site (Wagatsuma et al. 2014). To better correlate data from the present study and those from clinical trials, it will require another investigation that will correlate the injectate distribution scores and the clinical effects following RB and PB injections in dogs.

The proposed clinical success of RB injections in the present study was lower than that reported in previous studies in dogs. Complete intraconal placement of injectate was evident in six out of 15 (40%) of orbits injected using the RB technique, and partial intraconal placement of injectate was evident in another five out of 15 (33%). By comparison, in the first experimental study to describe RB injection in dogs, a successful outcome was projected in all four Beagle dog cadavers (eight orbits) assessed via magnetic resonance imaging; however, based on a significant increase in horizontal pupil diameter and central rotation of the globe in four anesthetized Beagle dogs (four orbits), a 75% success rate was

reported (Accola et al. 2006). Reported success in clinical studies varies. One study reported that 10 out of 10 (100% success) canine eyes became central following extraconal RB injection of 2 mL of 2% lidocaine prior to cataract surgery (Hazra et al. 2008). Another study reported 82% success (nine out of 11 dogs) based on rescue analgesia being required following enucleation surgery. These dogs were administered a ventrolateral RB injection with 2–3 mL of 0.5% bupivacaine (Myrna et al. 2010). Two other studies assessed the anesthetic effect of bupivacaine or a lidocaine–bupivacaine mixture administered via a presurgical RB injection versus local infiltration at the end of enucleation (Ploog et al. 2014; Chow et al. 2015). Considering only the dogs administered an RB injection, one out of 15 dogs in one study required rescue analgesia (93% success) (Chow et al. 2015), whereas 0 out of 11 dogs in a second study required rescue analgesia (100% success) (Ploog et al. 2014).

Shorter and smaller gauge needles are used in humans for the PB technique in comparison to the needles used for the RB technique (Nouvellon et al. 2010). This difference in needle size was not reported to produce any difference in the spread of the local anesthetic between these techniques in humans (Ali-Melkkilä et al. 1993) or in cats (Shilo-Benjamini et al. 2014). As the PB technique relies on distribution and not on specific deposition of the injectate, then the use of a shorter and smaller gauge needle is sufficient and potentially decreases the adverse effects of the PB injection technique (El Said & Kabeel 2010).

The significantly lower probability of achieving successful regional anesthesia based on intraconal distribution with all techniques in dogs of higher BW (>20 kg) was surprising since, for the PB injection techniques, this study used an allometric method to calculate the injectate volume. In retrospect, this decrease in success may have resulted from use of the same needle length (1.6 cm) for all dogs regardless of BW. In a recent experimental study of PB injection technique in Beagle dogs, a 2.54-cm-long needle was used (Wagatsuma et al. 2014). It is possible that, in larger dogs, longer needles may be required to deposit the injectate more caudally and achieve better distribution. For the RB injection technique, the volume used in the present study may have been too low for dogs >20 kg, as two studies have described RB administration of 3 mL in dogs >15 kg (Myrna et al. 2010; Ploog et al. 2014). In the study by Chow et al. (2015), BWs are not reported but the breeds recorded would suggest that the majority of their dogs

were <20 kg. A higher success rate was reported in a study of dogs limited to 10–15 kg (Hazra et al. 2008).

The increase in IOP following PB injections, especially PB-1, recorded in the present study has also been reported in humans (Bowman et al. 1996; Ghali & El Btarny 2010), cats (Shilo-Benjamini et al. 2013, 2014) and dogs (Wagatsuma et al. 2014). The increase in IOP usually does not persist beyond 10 minutes, as noted in the present study. However, pre-injection IOPs in the cadaver eyes used in the present study were below physiologic ranges, and normal autoregulatory mechanisms controlling IOP were absent. Therefore, further investigation is important in living animals with normal or abnormal aqueous outflow pathways. Until this information is available, based on data from the cadaver eyes, PB injection should likely be avoided in dogs with perforated globes or globes at risk of perforation, such as eyes with deep stromal ulcers, descemetocelles or corneal lacerations undergoing globe salvaging procedures. In animals with an elevated IOP, with or without glaucoma, a PB injection may be considered a relative contraindication since mild increases in IOP would be of less concern or no concern if the globe was being removed. It should be noted that the needle was inadvertently passed into or through the third eyelid or its gland in 19% of PB-1 injections. The clinical effect of this is unknown. If the injection preceded enucleation or exenteration, this would likely be of little significance since the entire third eyelid is removed during those procedures.

The present study has several limitations. First, differences in all parameters assessed would be expected between cadavers and live animals, resulting from cardiovascular effects and a normotensive globe on injectate distribution and IOP in the latter subjects. Second, the study population was small and included dogs with terminal diseases, many of whom were older, more cachectic and dehydrated than animals typically undergoing ocular surgery, and consequently enophthalmic with reduced orbital contents. Third, the proposed clinical success in the present study was defined on objective scores from CT images, which have not been correlated with analgesic effectiveness in living animals.

In conclusion, based on the definitions in the study design, the RB, PB-1 and PB-2 injection techniques produced large injectate volumes within the EOMC of 40%, 19% and 31% of orbits, and at the EOMC base in 60%, 63% and 50% of orbits, respectively. Although the circumferential spread was



significantly better with the RB technique, from a clinical perspective a likelihood of success of only 40–60% implies inadequate reliability. Further investigation and clinical assessment of anesthetic success of PB techniques in dogs are required.

### Acknowledgements

This study was supported by an endowment to Collaborative Studies Fund of the Center for Companion Animal Health, School of Veterinary Medicine, University of California, Davis, and the Koret School of Veterinary Medicine, The Hebrew University of Jerusalem (grant number 2013-43-KG). The authors thank Dr Alvaro P Solomon and Mr Rami Price from Koret Veterinary Teaching Hospital for their assistance with the CT.

### Authors' contributions

YSB: conception, study design, data acquisition and interpretation, drafting the manuscript. PJP: study design, data interpretation, manuscript preparation. ERW: study design, data acquisition, manuscript preparation. KN: data acquisition. PHK: data analysis, manuscript preparation. DJM: study design, manuscript preparation. All authors approved the final manuscript.

### Conflict of interest statement

The authors confirm no conflict of interest.

### References

- Accola PJ, Bentley E, Smith LJ et al. (2006) Development of a retrolubar injection technique for ocular surgery and analgesia in dogs. *J Am Vet Med Assoc* 229, 220–225.
- Ali-Melkkilä T, Virkkilä M, Leino K, Pälve H (1993) Regional anaesthesia for cataract surgery: comparison of three techniques. *Br J Ophthalmol* 77, 771–773.
- Bowman R, Liu C, Sarkies N (1996) Intraocular pressure changes after peribulbar injections with and without ocular compression. *Br J Ophthalmol* 80, 394–397.
- Chow DW, Wong MY, Westermeyer HD (2015) Comparison of two bupivacaine delivery methods to control postoperative pain after enucleation in dogs. *Vet Ophthalmol* 18, 422–428.
- El Said TM, Kabeel MM (2010) Comparison of classic peribulbar anesthesia and new entry point (single percutaneous injection technique) in vitreoretinal surgery. *Saudi J Anaesth* 4, 80–85.
- Evans H (1993) The skeleton. In: *Miller's Anatomy of the Dog* (3rd edn). Evans H (ed.). W.B. Saunders Company, USA, pp. 122–218.
- Evans H, Kitchell R (1993) Cranial nerves and cutaneous innervation of the head. In: *Miller's Anatomy of the Dog* (3rd edn). Evans H (ed.). W.B. Saunders Company, USA, pp. 953–987.
- Ghali AM, El Btarny AM (2010) The effect on outcome of peribulbar anaesthesia in conjunction with general anaesthesia for vitreoretinal surgery. *Anaesthesia* 65, 249–253.
- Giuliano EA (2008) Regional anesthesia as an adjunct for eyelid surgery in dogs. *Top Companion Anim Med* 23, 51–56.
- Hazra S, De D, Roy B et al. (2008) Use of ketamine, xylazine, and diazepam anesthesia with retrolubar block for phacoemulsification in dogs. *Vet Ophthalmol* 11, 255–259.
- Miller PE (2013) Orbit. In: *Slatter's Fundamentals of Veterinary Ophthalmology* (5th edn). Maggs DJ, Miller PE, Ofri R (eds). Elsevier Saunders, USA, pp. 372–393.
- Myrna KE, Bentley E, Smith LJ (2010) Effectiveness of injection of local anesthetic into the retrolubar space for postoperative analgesia following eye enucleation in dogs. *J Am Vet Med Assoc* 237, 174–177.
- Nouvellon E, Cuvillon P, Ripart J (2010) Regional anesthesia and eye surgery. *Anesthesiology* 113, 1236–1242.
- Ploog CL, Swinger RL, Spade J et al. (2014) Use of lidocaine–bupivacaine-infused absorbable gelatin hemostatic sponges versus lidocaine–bupivacaine retrolubar injections for postoperative analgesia following eye enucleation in dogs. *J Am Vet Med Assoc* 244, 57–62.
- Ripart J, Lefrant JY, de La Coussaye JE et al. (2001) Peribulbar versus retrolubar anesthesia for ophthalmic surgery: an anatomical comparison of extraconal and intraconal injections. *Anesthesiology* 94, 56–62.
- Shilo-Benjamini Y, Pascoe PJ, Maggs DJ et al. (2013) Retrolubar and peribulbar regional techniques in cats: a preliminary study in cadavers. *Vet Anaesth Analg* 40, 623–631.
- Shilo-Benjamini Y, Pascoe PJ, Maggs DJ et al. (2014) Comparison of peribulbar and retrolubar regional anesthesia with bupivacaine in cats. *Am J Vet Res* 75, 1029–1039.
- Wagatsuma JT, Deschk M, Floriano BP et al. (2014) Comparison of anesthetic efficacy and adverse effects associated with peribulbar injection of ropivacaine performed with and without ultrasound guidance in dogs. *Am J Vet Res* 75, 1040–1048.

Received 30 November 2016; accepted 13 February 2017.

Available online 13 April 2017