

UCSF

UC San Francisco Previously Published Works

Title

Myocarditis in children after COVID-19 vaccine

Permalink

<https://escholarship.org/uc/item/86m1c67w>

Journal

Annals of Pediatric Cardiology, 15(3)

ISSN

0974-2069

Authors

Aljohani, Othman A

Arcilla, Lisa

Kaushik, Neeru

et al.

Publication Date

2022

DOI

10.4103/apc.apc_135_21

Copyright Information

This work is made available under the terms of a Creative Commons Attribution-NonCommercial-ShareAlike License, available at <https://creativecommons.org/licenses/by-nc-sa/4.0/>

Peer reviewed

Myocarditis in children after COVID-19 vaccine

Othman A. Aljohani¹, Lisa Arcilla¹, Neeru Kaushik¹, Nicole M. Cresalia¹, Boran Li¹, April A. Edwell², Alice M. Ramirez², Shafkat Anwar^{1,3}

¹Department of Pediatrics, Division of Pediatric Cardiology, Benioff Children's Hospital, University of California, San Francisco, California, USA,

²Department of Pediatrics, Division of Pediatric Critical Care Medicine, Benioff Children's Hospital, University of California, San Francisco, California, USA,

³Department of Radiology and Biomedical Imaging, University of California, San Francisco, California, USA

ABSTRACT

Three healthy adolescents presented with myocarditis confirmed on cardiac magnetic resonance imaging after receiving Pfizer-BioNTech COVID-19 vaccine. All patients were hemodynamically stable and had good short-term outcomes. Long-term outcomes are yet to be determined. Larger studies are needed to determine whether an association between Pfizer-BioNTech COVID-19 vaccine and myocarditis exists.

Keywords: Cardiac magnetic resonance imaging, COVID-19, mRNA COVID-19 vaccination, myocarditis, pediatric, Pfizer-BioNTech

INTRODUCTION

As of June 21, 2021, approximately 318 million COVID-19 vaccine doses have been administered in the United States (U. S).^[1] The Pfizer-BioNTech COVID-19 mRNA vaccine received Emergency Use Authorization from the U. S. Food and Drug Administration for individuals ≥ 16 years in December 2020 and those 12–15 years in May 2021.^[2] While the Pfizer-BioNTech COVID-19 vaccine trials included over 43,000 participants ≥ 16 years in Phase 2/3, the number of participants in the younger age groups was limited. According to the Pfizer-BioNTech COVID-19 mRNA Vaccine Fact Sheet, Phase 2/3 included 138 and 145 adolescents 16 and 17 years of age in the vaccine and placebo groups, respectively. There were 2260 participants aged 12–15 years: 1131 and 1129 in the vaccine and placebo groups, respectively.^[2] It is possible that rare adverse events could manifest when administered to a larger population. We report three healthy male adolescents diagnosed with

myocarditis following Pfizer-BioNTech COVID-19 vaccination, confirmed on cardiac magnetic resonance imaging (CMR).

CASE REPORTS

Case 1

A 17-year-old male with a history of asthma presented to the emergency department (ED) with chest pain 2 days after receiving his second Pfizer-BioNTech COVID-19 vaccine. He initially developed fever, chills, malaise, myalgia, nausea, and vomiting, followed by sharp, central chest pain and dyspnea. The chest pain did not respond to albuterol or ibuprofen. There was no preceding upper respiratory infection (URI) or other gastrointestinal (GI) symptoms. Laboratory and clinical data are summarized in [Table 1]. Initial troponin was 8.1 ng/mL (normal <0.05 ng/mL). Electrocardiogram (ECG) was consistent with myopericarditis [Figure 1]. An

Access this article online	
Quick Response Code: 	Website: www.annalspc.com
	DOI: 10.4103/apc.apc_135_21

This is an open access journal, and articles are distributed under the terms of the Creative Commons Attribution-NonCommercial-ShareAlike 4.0 License, which allows others to remix, tweak, and build upon the work non-commercially, as long as appropriate credit is given and the new creations are licensed under the identical terms.

For reprints contact: WKHLRPMedknow_reprints@wolterskluwer.com

How to cite this article: Aljohani OA, Arcilla L, Kaushik N, Cresalia NM, Li B, Edwell AA, *et al.* Myocarditis in children after COVID-19 vaccine. *Ann Pediatr Card* 2022;15:280-3.

Address for correspondence: Dr. Othman A. Aljohani, University of California San Francisco, Benioff Children's Hospital, Box 0544, 550 16th St, 5th Floor, San Francisco 94143, California, USA.

E-mail: dr.othman.aljohani@gmail.com

Submitted: 08-Jul-2021

Revised: 14-Dec-2021

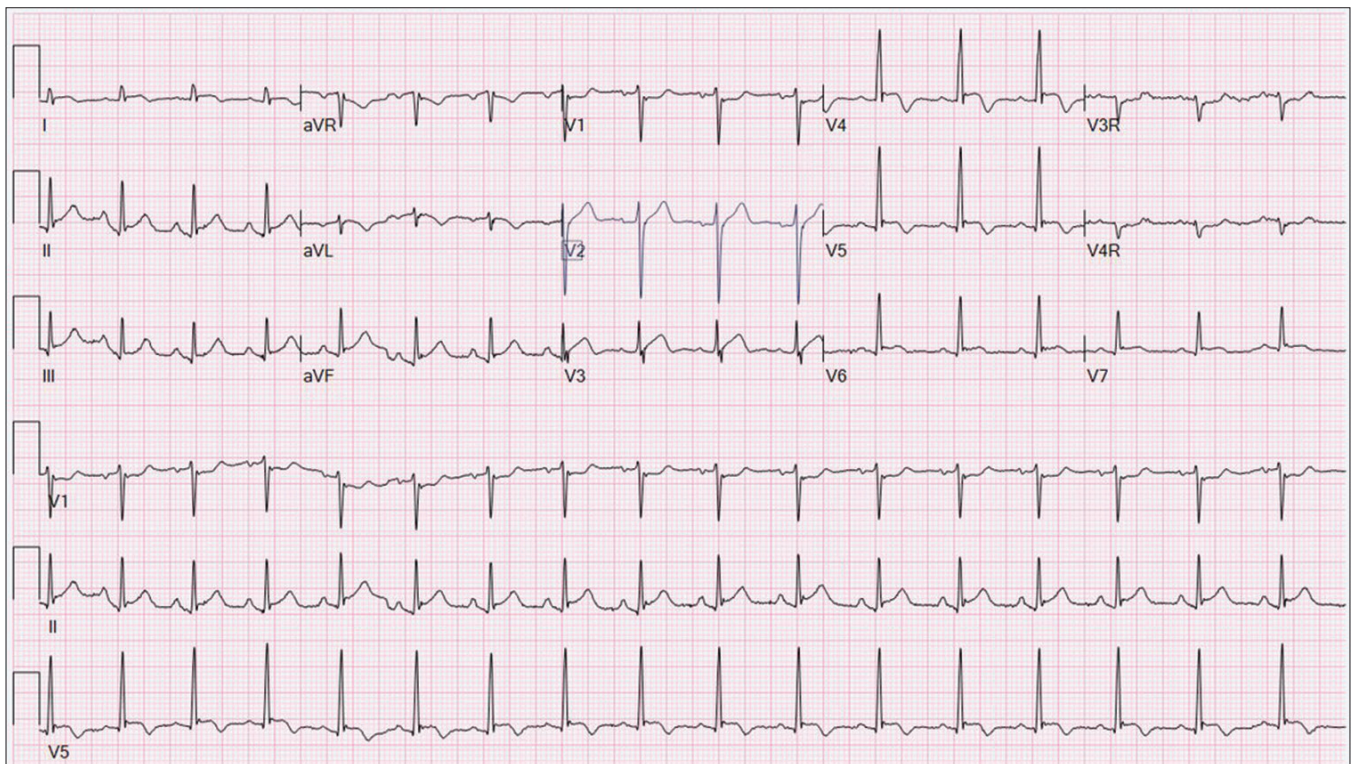
Accepted: 08-Jun-2022

Published: 16-Nov-2022

Table 1: Laboratory and clinical data

	Case 1	Case 2	Case 3
Presentation after dose	2	1	2
Previous COVID-19 infection	No	Yes	No
Troponin (initial/peak)	8.1/12.5 (normal <0.05 ng/mL)	13.3/13.3 (normal <0.05 ng/mL)	4.9/27.7 (normal <0.05 ng/mL)
CRP (initial/peak)	75/87 (normal 0.1-1.7 mg/L)	Initial: 60 (High-sensitivity, normal <8.1 mg/L) Peak: 55 (0.1-1.7 mg/L)	37/37 (normal <5.0 mg/L)
WBC on presentation	12 (normal 4.5-13.2 x10 ⁹ /L)	7.4	13.6
ALC* on presentation (%)	15 (normal 20-70)	27	16
COVID-19 PCR	Negative	Negative	Negative
COVID-19 Antibody (IgG against nucleocapsid protein)	Negative	Positive 8.2 (normal <0.8, intermediate 0.8-1, positive >1)	Negative
Treatments			
IVIG	2 g/kg	2 g/kg	2 g/kg
Aspirin	Yes	Yes	Yes
Steroids	Steroid taper	Steroid taper	Steroid taper
Outcome	Recovery	Recovery	Recovery

ALC=Absolute lymphocytic count

**Figure 1: ECG Case 1. ECG demonstrates sinus tachycardia (heart rate =102 bpm), T-wave inversion in lateral leads, and diffuse ST-segment changes (ST-segment elevation in inferolateral leads and ST-segment depression in aVR and V1). ECG: Electrocardiogram**

echocardiogram demonstrated normal biventricular size/function and proximal coronary arteries. A chest computed tomography was negative for pulmonary embolism. Nitroglycerin was ineffective and resulted in transient hypotension that self-resolved. He was transferred to our center, received 2 g/kg of intravenous immunoglobulin (IVIG) and was started on steroids and aspirin. Colchicine was added for ongoing chest pain, which provided symptomatic relief. CMR was consistent with myocarditis: late-gadolinium enhancement (LGE) at the left ventricular (LV) inferior wall, myocardial edema, and hyperemia at the mid-LV anterior wall [Figure 2].

As symptoms and troponin improved, aspirin was discontinued, and he was discharged after 6 days with exercise restrictions, a steroid taper, and colchicine for 2 weeks. At the 10-day follow-up, he had normal labs and echocardiogram.

Case 2

A 16-year-old previously healthy male presented to the ED with chest pain 3 days after receiving his first dose of Pfizer-BioNTech COVID-19 vaccine. He had a subjective fever 1 day after vaccination. The following day, he developed sharp left-sided chest pain, exacerbated

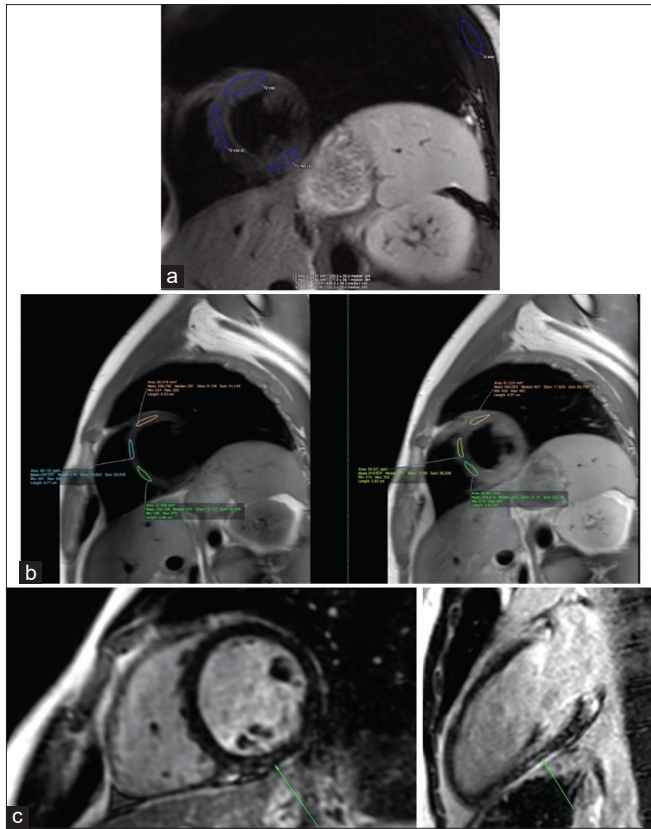


Figure 2: CMR with original Lake Louise Protocol Case 1. (a) T2-weighted black-blood sequence with >2:1 increase in myocardial signal intensity compared to skeletal muscle at the mid-LV, anterior wall. Positive findings were consistent with myocardial edema. (b) T1-weighted TSE sequence with >45% increase in signal intensity postcontrast at the mid-LV. Positive for early gadolinium enhancement, indicating hyperemia. (c) Late-gadolinium enhancement, signifying fibrosis or scar (green arrow), was noted on several slices at the LV inferior wall. CMR: Cardiac magnetic resonance imaging, TSE: Turbo spin echo, LV: Left ventricular

by deep breathing, with radiation to the left upper extremity. There were no preceding URI or GI symptoms. Notably, he had a mild COVID-19 infection 5 months before presentation. He had a normal ECG and troponin-I of 13.3 (normal <0.05 ng/ml) on presentation [Table 1]. An echocardiogram showed normal biventricular size/function and proximal coronary arteries. The patient received IVIG (2 g/kg) and was started on steroids and aspirin. CMR was consistent with myocarditis: hyperemia at the LV base and mid-LV, and a small focus of LGE at the mid-LV inferolateral segment. As his symptoms and troponin improved, he was discharged with exercise restrictions, steroids, and aspirin after 3 days of hospitalization. At the 2-week follow-up, labs, ECG, and echocardiogram were normal. Aspirin was discontinued and he was placed on tapering dose of steroid.

Case 3

A 16-year-old previously healthy male presented to the ED with chest pain 2 days after receiving the

second dose of Pfizer-BioNTech COVID-19 vaccine. He had subjective fever 1-day postvaccine followed by difficulty breathing, vomiting, and chest pain, which was sharp and intermittent without radiation. On presentation, troponin-I was 4.9 ng/mL. ECG showed sinus rhythm with mild ST elevation in inferolateral leads. Echocardiogram showed normal biventricular size/function and proximal coronary arteries. During IVIG (2 g/kg) infusion, he had acute worsening of chest pain, marked ST elevation, and troponin rise to 27.7 ng/mL [Table 1]. He was given nitroglycerin, aspirin, and morphine and started on steroids. CMR demonstrated LGE involving the inferolateral wall and hypokinesis in the mid-ventricular level inferolateral wall. As troponin downtrended and symptoms improved, he was discharged with exercise restrictions, aspirin, and a steroid taper after 7 days of hospitalization. Troponin-I was 0.29 (normal <0.09 ng/mL) 4 days after discharge, and follow-up echocardiogram was normal.

DISCUSSION

In this case series, we report three male adolescents with CMR-confirmed myocarditis diagnosed shortly after receiving Pfizer-BioNTech COVID-19 vaccine. The estimated incidence of myopericarditis after the second dose of the Pfizer mRNA COVID-19 vaccine is around 0.01% (12–15 years) and 0.008% (16–17 years).^[3] A recent multicenter case series reported this entity in seven children, and shortly thereafter Shaw *et al.* reported two adolescents.^[4,5] In the Marshall *et al.* series, all cases followed the second dose of the vaccine. Interestingly, two cases in the Shaw *et al.* series and one of our cases had myocarditis following the first vaccine dose. All three of these patients had documented previous COVID-19 infection. An increased immunogenic response may be a factor in patients with previous COVID-19 infection receiving COVID-19 vaccination and warrants further study.

Given myocarditis is a potentially life-threatening condition, it must be diagnosed promptly.^[6] CMR is the gold standard noninvasive diagnostic modality for diagnosing myocarditis and can differentiate ischemic versus nonischemic inflammatory processes. In adults, parametric T1, T2, and extracellular volume mapping techniques are well-validated for diagnosing myocarditis. However, the pediatric evidence for parametric mapping is much more limited, and currently, applying the original Lake Louise Criteria yields higher sensitivity to the CMR diagnosis of pediatric myocarditis.^[7] Children with myocarditis occasionally present with symptoms mimicking acute coronary syndrome: chest pain, dyspnea, elevated cardiac enzymes, and ECG abnormalities.^[6] In these instances, it is important to keep myocarditis high on the differential diagnosis as

opposed to ischemic coronary disease, which is rare in children.

CONCLUSIONS

COVID-19 vaccine-related myocarditis is an emerging entity that must be closely examined and reported to the Vaccine Adverse Event Reporting System in the U. S. All published cases to date have had good clinical outcomes in the short term, and it is vitally important to collect long-term data in this population. It is crucial to remember this entity can mimic acute coronary syndrome, to avoid unnecessary procedures for adolescents in whom ischemic coronary disease is exceedingly rare. CMR is the gold standard noninvasive test that can help establish the diagnosis of myocarditis. Larger studies are needed to further delineate the association between the Pfizer-BioNTech COVID-19 vaccine and myocarditis. We recommend following Centers for Disease Control guidelines and updates.

Declaration of patient consent

The authors certify that they have obtained all appropriate patient consent forms. In the form, the patient(s) has/have given his/her/their consent for his/her/their images and other clinical information to be reported in the journal. The patients understand that their names and initials will not be published and due efforts will be made to conceal their identity, but anonymity cannot be guaranteed.

Acknowledgment

Drs. Kimberly Kallianos and Yoo Jin Lee coperformed the magnetic resonance imagings for Cases 1 and 2 with Dr. Anwar.

Financial support and sponsorship

Nil.

Conflicts of interest

There are no conflicts of interest.

REFERENCES

1. Coronavirus (COVID-19) vaccinations. Our World in Data. Available from: <https://ourworldindata.org/covid-vaccinations?country=USA>. [Last accessed on 2021 Jun 21].
2. Pfizer-BioNTech. Full Emergency Use Authorization (EUA) Prescribing Information. Available from: <http://labeling.pfizer.com/ShowLabeling.aspx?id=14471&format=pdf&#page=13>. [Last accessed on 2021 Jun 19].
3. Schauer J, Buddhe S, Colyer J, Sagiv E, Law Y, Mallenahalli Chikkabyrappa S, et al. Myopericarditis after the pfizer messenger ribonucleic acid coronavirus disease vaccine in adolescents. *J Pediatr* 2021;238:317-20.
4. Marshall M, Ferguson ID, Lewis P, Jaggi P, Gagliardo C, Collins JS, et al. Symptomatic acute myocarditis in seven adolescents following Pfizer-Biontech COVID-19 vaccination. *Pediatrics* 2021;148:e2021052478.
5. Shaw KE, Cavalcante JL, Han BK, Gössl M. Possible association between COVID-19 vaccine and myocarditis: Clinical and CMR findings. *JACC Cardiovasc Imaging* 2021;14:1856-61.
6. Simpson KE, Anwar S, Canter CE. Myocarditis. Moss and Adam's Heart Disease. 10th ed. Philadelphia: Lippincott Williams & Wilkins (LWW); 2021.
7. Ferreira VM, Schulz-Menger J, Holmvang G, Kramer CM, Carbone I, Sechtem U, et al. Cardiovascular magnetic resonance in nonischemic myocardial inflammation: Expert recommendations. *J Am Coll Cardiol* 2018;72:3158-76.