

UC Davis

Dermatology Online Journal

Title

Generalized morphea successfully treated with extracorporeal photochemotherapy (ECP).

Permalink

<https://escholarship.org/uc/item/86f3g7zi>

Journal

Dermatology Online Journal, 20(1)

Authors

Pileri, A
Raone, B
Raboni, R
et al.

Publication Date

2014

DOI

10.5070/D3201021258

Copyright Information

Copyright 2014 by the author(s). This work is made available under the terms of a Creative Commons Attribution-NonCommercial-NoDerivatives License, available at <https://creativecommons.org/licenses/by-nc-nd/4.0/>

Letter

Generalized morphea successfully treated with extracorporeal photochemotherapy (ECP).

A. Pileri¹ MD PhD, B. Raone¹ MD PhD, R. Raboni MD¹, V. Giudice² MD, A. Patrizi¹ MD

Dermatology Online Journal 20 (1): 17

¹Dermatology, Department of Specialised, Experimental and Diagnostic Medicine, University of Bologna, Italy

²Immunohematology Service and Blood Bank, S. Orsola-Malpighi Hospital, Bologna, Italy

Correspondence:

Alessandro Pileri MD PhD
Dermatology, Department of Specialised, Experimental and Diagnostic Medicine
University of Bologna,
Via Massarenti 1, 40138, Bologna, Italy.
alessandropileri@hotmail.it

Abstract

A patient is presented with generalized morphea whose disease completely resolved after combination therapy with extracorporeal photopheresis and broad band UVA treatments.

Key words: Generalized morphea, extracorporeal photopheresis, broad band UVA-therapy

Case synopsis

Scleroderma may be widespread or localized and involves skin and subcutaneous thickening [1]. It can be classified as systemic sclerosis and localized scleroderma (morphea). The former is characterized by visceral involvement; the latter is limited to the skin and subcutaneous tissue [2]. Generalized morphea is a localized scleroderma variety consisting of the presence of at least four plaques larger than three cm that become confluent affecting more than two anatomic areas [3]. Morphea pathogenesis is unknown. Nevertheless, a variety of features suggest autoimmune pathogenesis [2].

A 62-year-old otherwise healthy female presented with indurated, erythematous plaques on the abdomen (Figure 1) and upper and lower limbs (body surface involved: 60%) for 4 months. Moreover, the patient's daily life was limited because of stiffness as well as painful contractures in both upper and lower limbs that hampered her mobility. The diagnosis of generalized morphea was made.

Laboratory testing showed eosinophilia (13,3%), an increase in IgE levels (441 UI/mL), and positivity for antinuclear antibody (speckled pattern 1:80). Furthermore, chest X-ray and respiratory functional tests were normal. Both topical and oral steroids (prednisone, starting dose 1mg/kg/day tapered off within a few months) were unsuccessfully started, along with methotrexate (15 mg/week). Finally, extracorporeal photopheresis (ECP) was administered (one cycle of two consecutive days at 2-week intervals for the first four months). After four months the disease improved and ECP was administered one cycle every four weeks for three months, then every six weeks for three months, and every seven weeks for three months. Finally, the frequency was decreased to eight-week intervals for three months. After sixteen months ECP was stopped. No pain was noted by the patient; all the above described lesions resolved and no indurated plaques were palpable. Thereafter, the patient underwent broad band UVA treatment (four times per week for 5 weeks, then twice a week for 6 weeks, starting dose 1 J/cm², maximum single dose administered 7 J/cm², cumulative total dose 118 J/cm²) as maintenance therapy. After a 12-months-follow up the patient is still in complete remission.

ECP can be regarded as one of the most widely useful immunotherapies and is used in treatment of cutaneous T-cell lymphoma, transplant rejection, autoimmune diseases, and GVHD [4,5,6]. ECP efficacy for systemic sclerosis has been proven in a multicenter, randomized, single-blind controlled trial [7]. Furthermore, Schlaak et al.[8] reported a bullous scleroderma case successfully treated with ECP and mycophenolate mofetil. Notably, in accordance with Neustadter et al [2], ECP in our case was scheduled in a similar way. However, unlike these authors [2], ECP was decreased more rapidly in the last months of our therapy and was followed by broad band UVA as maintenance. As previously reported [2], we observed a clinical improvement after two months from beginning ECP. The therapeutic mechanism of ECP remains unknown. However, it has been observed that ECP can increase anti-inflammatory responses enhancing regulatory T-cell (Treg) activity. Treg releasing IL-10 and transforming growth factor-beta (TGF-beta) can decrease pro-inflammatory activity, which is thought to be involved in scleroderma pathogenesis [9]. These findings suggest that ECP, unlike immunosuppressant therapies (i.e. steroids), seems not to decrease general immunocompetence [7].

After ECP we chose broadband UVA therapy as maintenance. Although UVA-1 is a well-known treatment for its efficacy in generalized morphea, anti-fibrotic effects of broadband UVA are similar to those reported with UVA-1 [10]. Our case corroborates ECP's effectiveness on generalized morphea suggesting that ECP warrants consideration in selected cases.

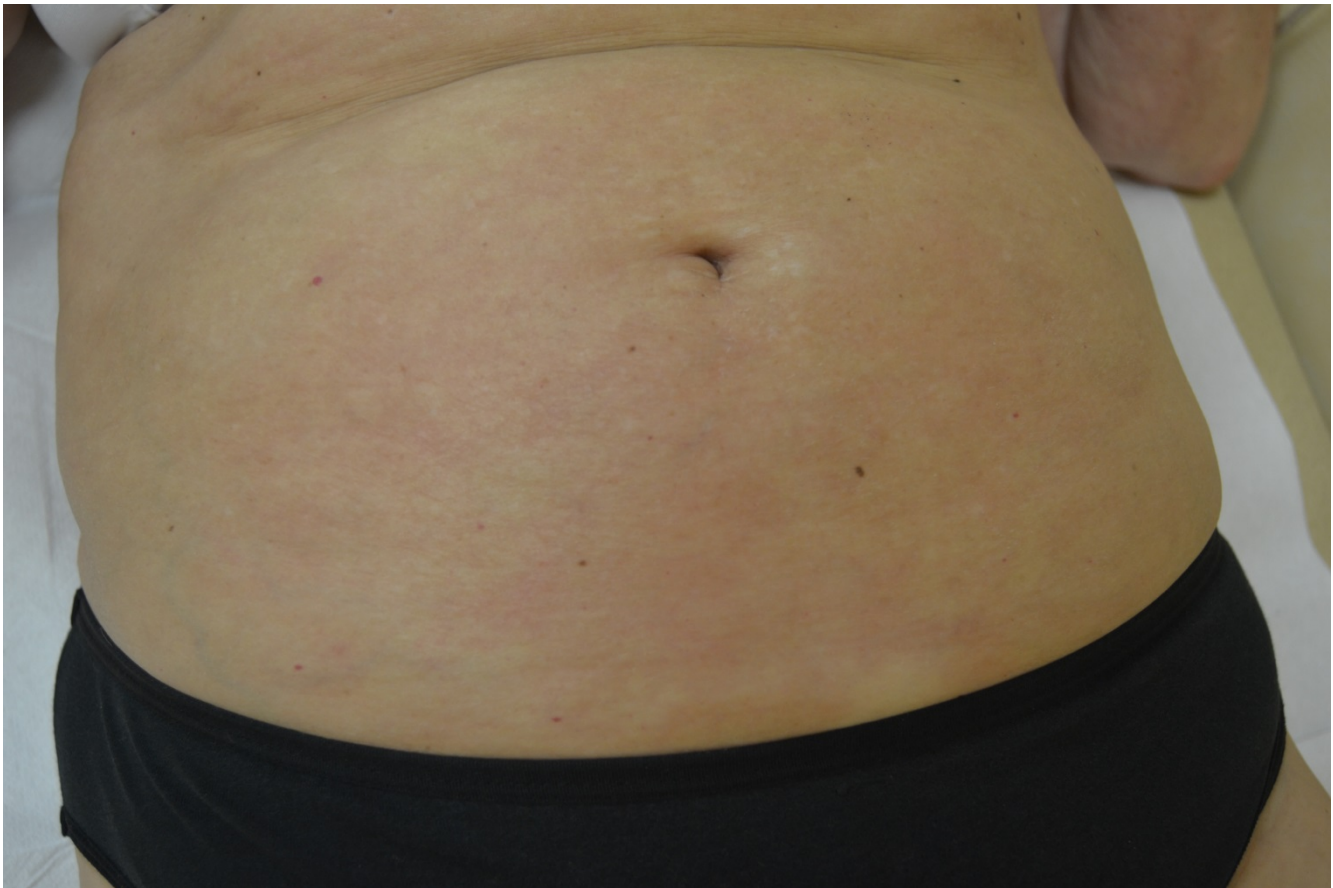


Figure 1. erythematous indurated plaque on the abdomen

References

1. Peterson LS, Nelson AM, Su WP. Classification of morphea (localized scleroderma). *Mayo Clin Proc.* 1995;70: 1068-76. [PMID: 7475336]
2. Neustadter JH, Samarin F, Carlson KR, Girardi M. Extracorporeal photochemotherapy for generalized deep morphea. *Arch Dermatol.* 2009;145: 127-30. [PMID: 19221256]
3. Chung L, Lin J, Furst DE, Fiorentino D. Systemic and localized scleroderma. *Clin Dermatol.* 2006;24: 374-92. [PMID: 16966019]
4. Nihtyanova SI, Denton CP. Current approaches to the management of early active diffuse scleroderma skin disease. *Rheum Dis Clin North Am.* 2008;34:161-79. [PMID: 18329538]
5. Rossetti F, Zulian F, Dall'Amico R, Messina C, Montini G, Zacchello F. Extracorporeal photochemotherapy as single therapy for extensive, cutaneous, chronic graft-versus-host disease. *Transplantation* 1995; 59:149-51. [PMID: 7839419]
6. Fimiani M, Rubegni P, D'Ascenzo G, Andreassi L. Extracorporeal photochemotherapy in the early treatment of cutaneous T-cell lymphoma. *J Am Acad Dermatol.* 1994;31:828-30. [PMID: 7929941]

7. Knobler RM, French LE, Kim Y, Bisaccia E, Graninger W, Nahavandi H, Strobl FJ, Keystone E, Mehlmauer M, Rook AH, Braverman I; Systemic Sclerosis Study Group. A randomized, double-blind, placebo-controlled trial of photopheresis in systemic sclerosis. *J Am Acad Dermatol.* 2006;54:793-99. [PMID: 16635659]
8. Schlaak M, Friedlein H, Kauer F, Renner R, Rogalski C, Simon JC.. Successful therapy of a patient with therapy recalcitrant generalized bullous scleroderma by extracorporeal photopheresis and mycophenolate mofetil. *J Eur Acad Dermatol Venereol.* 2008;22:631-33. [PMID: 18410628]
9. Bladon J, Taylor PC. Lymphocytes treated by extracorporeal photopheresis can down-regulate cytokine production in untreated monocytes. *Photodermatol Photoimmunol Photomed.* 2005;21:293-02. [PMID: 16313240]
10. El-Mofty M, Mostafa W, Esmat S, Youssef R, Bousseila M, Nagi N, Shaker O, Abouzeid A. Suggested mechanisms of action of UVA phototherapy in morphea: a molecular study. *Photodermatol Photoimmunol Photomed.* 2004;20:93-100. [PMID: 15030594]