

# UCSF

## UC San Francisco Previously Published Works

### Title

Periportal Capsulotomy: A Technique for Limited Violation of the Hip Capsule During Arthroscopy for Femoroacetabular Impingement

### Permalink

<https://escholarship.org/uc/item/84p965m1>

### Journal

Arthroscopy Techniques, 8(2)

### ISSN

2212-6287

### Authors

Monroe, Emily J  
Chambers, Caitlin C  
Zhang, Alan L

### Publication Date

2019-02-01

### DOI

10.1016/j.eats.2018.10.015

### Copyright Information

This work is made available under the terms of a Creative Commons Attribution-NonCommercial-NoDerivatives License, available at <https://creativecommons.org/licenses/by-nc-nd/4.0/>

Peer reviewed



# Periportal Capsulotomy: A Technique for Limited Violation of the Hip Capsule During Arthroscopy for Femoroacetabular Impingement

Emily J. Monroe, M.D., Caitlin C. Chambers, M.D., and Alan L. Zhang, M.D.

**Abstract:** Hip arthroscopy has become the standard treatment for symptomatic femoroacetabular impingement as patients have shown good outcomes and high satisfaction with this intervention. However, capsular management to gain access for intra-articular procedures remains greatly debated. Capsular closure is advocated particularly in the setting of interportal or T-capsulotomy to avoid complications of instability or nonhealing capsule. We introduce a technique for capsular management through a limited periportal capsulotomy during arthroscopic treatment of femoroacetabular impingement. In using dilation of the anterolateral and mid-anterior portals without completion of a full interportal capsulotomy, the stabilizing iliofemoral ligament is preserved. We have found that periportal capsulotomy provides safe and sufficient access to the hip joint without necessitating capsular closure.

**H**ip arthroscopy has become the standard treatment for femoroacetabular impingement because studies have shown good outcomes and high satisfaction with this intervention.<sup>1,2</sup> Adequate visualization and working space within the hip joint requires distraction and some form of capsulotomy because of the anatomic constraints of the hip joint. The optimal type of capsulotomy and its need for subsequent closure remains debated among experienced hip arthroscopists. The most common capsular entry technique is the interportal capsulotomy, where the capsule and iliofemoral ligament are incised in line between the anterolateral portal (ALP) and the mid-anterior portal (MAP) or direct anterior portal.<sup>3</sup> Alternatively, some surgeons use a T-capsulotomy, in which

the capsule is incised longitudinally in a distal and lateral direction along the anterior femoral head–neck junction starting proximally from the interportal capsulotomy for improved access to large, distal cam lesions.<sup>4</sup> More recently, puncture capsulotomy, using multiple (4–5) small, undilated portals, has been introduced to preserve capsule integrity.<sup>4</sup>

Although technically challenging, capsular closure has been advocated because of concerns regarding iatrogenic hip instability with either low-energy dislocation or microinstability causing persistent pain postoperatively.<sup>5</sup> Compromise of the iliofemoral ligament with transection from interportal or T-capsulotomy eliminates its ability to resist hip extension and anterior translation, which may be the driving force for postoperative instability.<sup>6</sup> Consequently, some clinical studies report improved postoperative outcomes with closure of interportal and T-capsulotomies, whereas other studies show equivalent outcomes with or without closure of interportal capsulotomies.<sup>3,7</sup> Recent magnetic resonance imaging–based analyses have also demonstrated that interportal capsulotomies can heal without surgical closure similarly to hips with surgically closed capsules.<sup>8,9</sup>

The perfect answer for capsular management remains undefined. Our described technique exploits minimally dilated portals to allow instrument movement to visualize and intervene on pertinent pathology. Maintaining the structural integrity of the iliofemoral ligament contributes to stability of the postoperative hip and

From the Department of Orthopaedic Surgery, University of California—San Francisco, San Francisco, California, U.S.A.

The authors report the following potential conflicts of interest or sources of funding: A.L.Z. is a consultant for Stryker, outside the submitted work. Full ICMJE author disclosure forms are available for this article online, as [supplementary material](#).

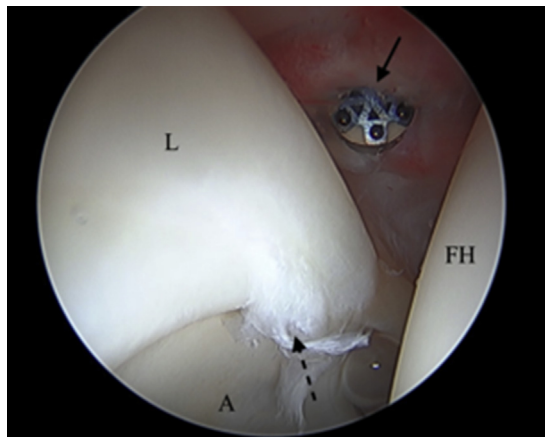
Received August 10, 2018; accepted October 19, 2018.

Address correspondence to Alan L. Zhang, M.D., Department of Orthopaedic Surgery, University of California—San Francisco, 1500 Owens St, Box 3004, San Francisco, California 94158, U.S.A. E-mail: [Alan.Zhang@ucsf.edu](mailto:Alan.Zhang@ucsf.edu)

© 2018 by the Arthroscopy Association of North America. Published by Elsevier. This is an open access article under the CC BY-NC-ND license (<http://creativecommons.org/licenses/by-nc-nd/4.0/>).

2212-6287/18992

<https://doi.org/10.1016/j.eats.2018.10.015>

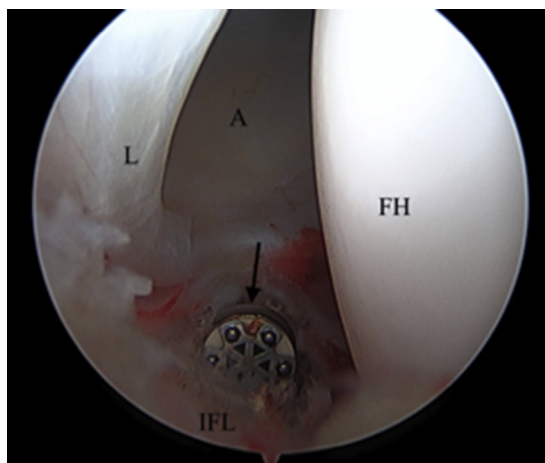


**Fig 1.** A right hip from the ALP, viewing anteriorly and medially. The MAP, noted by a solid arrow, is dilated with a radiofrequency ablator in the posterosuperior direction in line toward the ALP, then in the anteroinferior direction away from the ALP to a total size of 8 to 10 mm. A tear of the anterosuperior labrum is seen at the dashed arrow. (A, acetabulum; ALP, anterolateral portal; FH, femoral head; L, labrum; MAP, mid-anterior portal.)

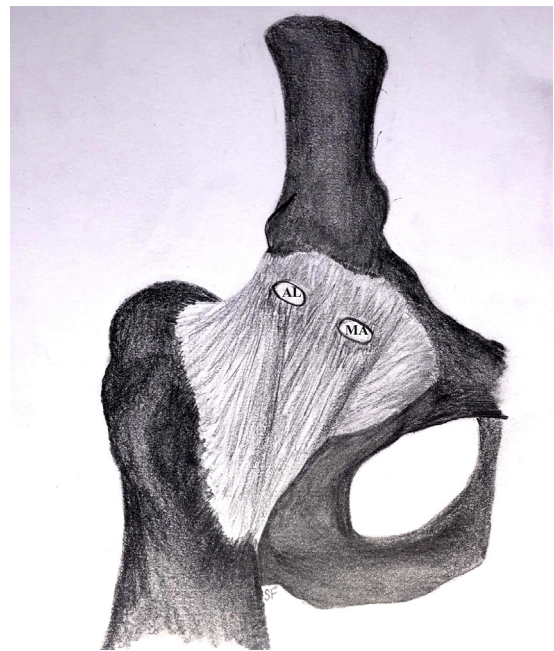allows for completion of the procedure without necessitating closure of the hip capsule.

### Surgical Technique

The patient is positioned supine on a traction table that allows dynamic leg positioning. Both feet are well secured and padded within positioning boots, and a large padded perineal post is used. The operative leg is positioned in neutral rotation. An air arthrogram can be used to decompress the suction seal of the hip before



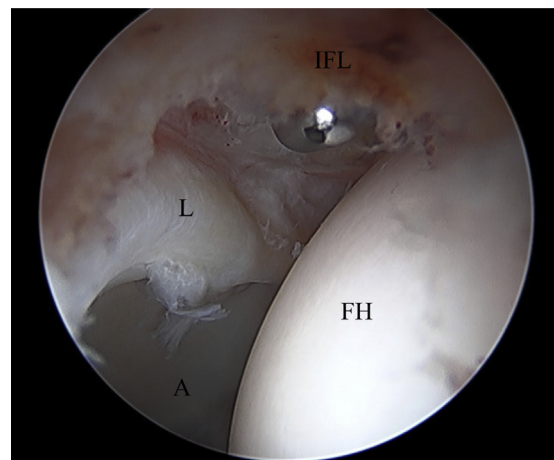
**Fig 2.** A right hip from MAP, viewing laterally. The ALP, noted by a solid arrow, is dilated with a radiofrequency ablator in line with the MAP to approximately 6 to 8 mm. The FH, A, and L are shown, as is the intact IFL between the MAP and ALP. (A, acetabulum; ALP, anterolateral portal; FH, femoral head; IFL, iliofemoral ligament; L, labrum; MAP, mid-anterior portal.)



**Fig 3.** A right hip demonstrating the AL and MA portals near the lateral and medial edges of the iliofemoral ligament, respectively. (AL, anterolateral; MA, mid-anterior.)

traction is applied. The joint is distracted between 1 and 2 cm. The ALP is established first under fluoroscopic guidance with placement of a spinal needle followed by the trocar and cannula for the arthroscope. A 70° arthroscope is inserted to the central compartment. A MAP is placed in a similar fashion 3 cm anterior and just distal to the ALP. This can be established under direct visualization with fluoroscopic aid as needed.

A radiofrequency ablation (RFA) device (Arthrocare; Smith & Nephew, Andover, MA) is then used in the MAP to dilate the capsular opening extending the portal



**Fig 4.** A right hip from ALP with probe on the intact IFL following dilation of both the ALP and mid-anterior portal. (A, acetabulum; ALP, anterolateral portal; FH, femoral head; IFL, iliofemoral ligament; L, labrum.)

**Table 1.** Pearls and Pitfalls

Pearls	Pitfalls
Perform full-thickness capsular dilation.	Overdilation or unintended connection of portals leads to full interportal capsulotomy.
Use a radiofrequency ablator for precise capsulotomy.	Plication of the capsule during repair may occur because of tissue loss from use of radiofrequency ablation.
Keep working side of instruments oriented away from capsule.	Performing for ligamentously lax patients may create microinstability.
Use curved instrumentation and flexible suture anchors to ensure safe implant placement.	Malpositioning the anterior anchor may lead to inadequate bone fixation or penetration of acetabular cartilage.
Fully expose the femoral head–neck junction by undermining the capsule with the radiofrequency ablator.	Under-resecting the distal cam may occur because of capsular restraint.
Flex and rotate the hip to gain full access to the cam lesion for complete decompression.	

posterosuperiorly toward the ALP and anteroinferiorly away from the ALP, for a total dilated MAP width of 8 to 10 mm (Fig 1). The dilation is performed in line with the ALP, in the same plane as an interportal capsulotomy. Care is taken to open through the full thickness of the capsule. This process is repeated for the ALP by changing the arthroscope to view from the MAP and placing the RFA into the ALP. The ALP is also dilated in line with the MAP to a total width of 6 to 8 mm (Figs 2 and 3). This process allows movement of the instruments within the hip without creating a full interportal capsulotomy and, importantly, preserves the iliofemoral ligament (Fig 4, Video 1).

The arthroscope is then reintroduced into the ALP to perform a diagnostic arthroscopy, and an 8.25-mm plastic disposable cannula is placed over a switching stick into the MAP; alternatively, a sled can be used to exchange instruments. To address pincer lesions, the capsule above the anterosuperior labrum is separated and lifted proximally using RFA. A 5.5-mm round burr (Stryker, Kalamazoo, MI) is then used to perform an acetabuloplasty of 5 to 6 mm with adequate resection verified by fluoroscopy. Labral repair is then typically performed. Our preferred technique is by placing sequential flexible anchors (Pivot NanoTack Flex; Stryker) at the chondrolabral junction through curved drill guides from the MAP while visualizing intra-articularly, ensuring there is no penetration of the cartilage. Sutures are then passed in a looped fashion

around the labrum utilizing a suture passer (Pivot NanoPass; Stryker), and 5 reversing half hitch knots are tied.

Traction is then released, the operative hip is flexed 10°, and restoration of the suction seal is visualized. Beginning in neutral hip extension and slight internal rotation, the cam lesion is exposed by undermining the capsule and removing the non–load-bearing articular cartilage along the femoral head neck junction with an RFA. The 5.5-mm round burr is then used to perform a femoroplasty. To ensure that adequate cam resection is performed, the hip is flexed and rotated to varying degrees to fully contour the femoral neck.<sup>10</sup> This is evaluated with direct visualization and fluoroscopy to ensure no residual impingement. Because a full capsulotomy is not performed, maneuvering within the space can be facilitated by moving both camera and working instrument in a similar direction to limit tension across the iliofemoral ligament. Capsular closure is not routinely performed because of the minimal capsular violation (Video 1).

Postoperatively, the patient is maintained on crutches with flat foot touchdown weight bearing for 2 weeks without brace immobilization. Physical therapy guides progressive weight bearing and weaning from crutches at 2 weeks postoperatively, strengthening at 6 weeks, progression to running at 3 months, and cutting or pivoting activities 5 to 6 months following surgery. Pearls and Pitfalls (Table 1) as well

**Table 2.** Advantages and Disadvantages

Advantages	Disadvantages
Capsular closure is unnecessary.	Completion of interportal capsulotomy may require closure.
Operative times are shorter.	Capsular closure may result in plication owing to radiofrequency ablator tissue loss.
Hypothetically, the procedure is less painful because of minimal violation of the capsule, its adjacent innervation, and the overlying musculature.	Distal cam resection is technically demanding.
There is no postoperative instability.	The procedure may not be indicated for ligamentous lax individuals.
There is less fluid extravasation to the surrounding musculature.	

as Advantages and Disadvantages (Table 2) of this technique have been summarized.

### Discussion

Arthroscopic treatment of the hip has advanced in indications and techniques. Interportal and T-capsulotomies have been the primary method of exposure for osteochondroplasty of the acetabulum and femoral neck. Evolving instrumentation for capsular management has made closure technically easier, and many field leaders advocate it. Capsular closure, however, adds time to the procedure, potentially leads to a more constrained hip, and can contribute to irritation of the hip flexors when nonabsorbable suture is used. In addition, literature has not comparatively demonstrated improved patient outcomes or lower complication rates with routine capsular closure and capsular healing occurs even in absence of closure.<sup>9</sup>

The periportal capsulotomy technique allows for adequate exposure of the hip joint without necessitating capsular closure by maintaining integrity of the iliofemoral ligament. Puncture capsulotomy has recently been introduced with a similar goal of providing arthroscopic hip joint access without transection of the iliofemoral ligament.<sup>4</sup> This technique uses 4 to 5 portals of 5 mm width without an interconnecting capsulotomy. In comparison, the periportal capsulotomy uses only 2 portals, dilated to between 6 to 8 mm and 8 to 10 mm. There have not yet been any clinical results published with use of the puncture capsulotomy technique. Further, although the theory of iliofemoral ligament maintenance is similar, the periportal capsulotomy technique allows for this goal to be met with fewer zones of insult to the ligament.

We believe this technique is easily adopted by those with experience in hip arthroscopy, particularly because the dilation is performed in line with a more traditionally performed interportal capsulotomy. Potential hazards can be encountered if the periportal dilation is inadvertently completed to the full interportal capsulotomy. Using RFA results in capsular tissue loss, if capsular closure is subsequently required, there may be inadequate tissue for repair or plication that occurs as a result of closure. Access to the peripheral compartment can also pose a challenge because visualization of the cam deformity necessitates sequential elevation and lifting of the capsule with progression distally along the femoral neck. A technical pearl in using this technique is moving both camera and working instrument simultaneously while performing the femoroplasty because the intact iliofemoral ligament can act as a tether, limiting the surgeon's ability to reach the full distal extent of the cam lesion. Finally, in hypermobile patients or revision cases, consideration

should be given to closing the periportal capsulotomy or performing an interportal capsulotomy with a sharp blade to facilitate easier closure or plication.

In the technically demanding procedure of hip arthroscopy, periportal capsulotomy provides safe and sufficient access to the hip joint for arthroscopic treatment of femoroacetabular impingement without necessitating capsular closure.

### References

1. Nwachukwu BU, Chang B, Adjei J, et al. Time required to achieve minimal clinically important difference and substantial clinical benefit after arthroscopic treatment of femoroacetabular impingement. *Am J Sports Med* 2018; 363546518786480.
2. Reiman MP, Peters S, Sylvain J, Hagymasi S, Mather RC, Goode AP. Femoroacetabular impingement surgery allows 74% of athletes to return to the same competitive level of sports participation but their level of performance remains unreported: A systematic review with meta-analysis. *Br J Sports Med* 2018;52:972-981.
3. Ekhtiari S, de Sa D, Haldane CE, et al. Hip arthroscopic capsulotomy techniques and capsular management strategies: A systematic review. *Knee Surg Sports Traumatol Arthrosc* 2017;25:9-23.
4. Conaway WK, Martin SD. Puncture capsulotomy during hip arthroscopy for femoroacetabular impingement: Preserving anatomy and biomechanics. *Arthrosc Tech* 2017;6: e2265-e2269.
5. Duplantier NL, McCulloch PC, Nho SJ, Mather RC III, Lewis BD, Harris JD. Hip dislocation or subluxation after hip arthroscopy: A systematic review. *Arthroscopy* 2016;32: 1428-1434.
6. Bakshi NK, Bayer JL, Bigelow EMR, Jameel OF, Sekiya JK. The effect of capsulectomy on hip joint biomechanics. *Orthop J Sports Med* 2017;5: 2325967117722422.
7. Frank RM, Lee S, Bush-Joseph CA, Kelly BT, Salata MJ, Nho SJ. Improved outcomes after hip arthroscopic surgery in patients undergoing T-capsulotomy with complete repair versus partial repair for femoroacetabular impingement: A comparative matched-pair analysis. *Am J Sports Med* 2014;42:2634-2642.
8. Domb BG, Stake CE, Finley ZJ, Chen T, Giordano BD. Influence of capsular repair versus unrepaired capsulotomy on 2-year clinical outcomes after arthroscopic hip preservation surgery. *Arthroscopy* 2015;31:643-650.
9. Strickland CD, Kraeutler MJ, Brick MJ, et al. MRI evaluation of repaired versus unrepaired interportal capsulotomy in simultaneous bilateral hip arthroscopy: A double-blind, randomized controlled trial. *J Bone Joint Surg Am* 2018;100:91-98.
10. Ross JR, Bedi A, Stone RM, et al. Intraoperative fluoroscopic imaging to treat cam deformities: Correlation with 3-dimensional computed tomography. *Am J Sports Med* 2014;42:1370-1376.