

UCLA

Proceedings of UCLA Health

Title

Successful Transcatheter Mitral Valve Repair in Acute Cardiogenic Shock Due to Flail Posterior Leaflet

Permalink

<https://escholarship.org/uc/item/84h06164>

Journal

Proceedings of UCLA Health, 21(1)

Authors

Kane, Bradley

Calfon Press, Marcella Anne

Publication Date

2017-05-22

CLINICAL VIGNETTE

Successful Transcatheter Mitral Valve Repair in Acute Cardiogenic Shock Due to Flail Posterior Leaflet

Bradley Kane, M.D., and Marcella Anne Calfon Press, M.D., Ph.D.

Abstract

Mitral regurgitation (MR) due to flail leaflet is associated with significant morbidity and mortality. The standard of care for severe, symptomatic MR remains surgical repair; however, nearly one-half of patients are ineligible for surgery due to prohibitive risk. In this case, we present an elderly female with decompensated heart failure resulting in acute cardiogenic shock due to severe mitral regurgitation who underwent successful percutaneous mitral valve repair. Our case highlights several important findings in patients undergoing transcatheter mitral valve repair (TMVR). First, we emphasize that TMVR is safe and effective in the setting of cardiogenic shock. Many of the studies validating the use of TMVR have excluded very high-risk patients, including those patients with hemodynamic instability. We also analyze important physiologic hemodynamic effects that often occur immediately post TMVR that are important to consider in high-risk patients. Thus, our case highlights the safety and feasibility of TMVR in a very high-risk population.

Introduction

Mitral regurgitation (MR) is the most common cause of valvular disease in the United States.¹ MR due to flail leaflet is associated with significant morbidity and mortality, specifically in symptomatic patients, or those with reduced left ventricular ejection fraction (LVEF).² While the standard of care for severe, symptomatic MR remains surgical repair, it is estimated that nearly one half of patients with severe MR are deemed a prohibitive surgical risk, often due to age and other comorbidities.³⁻⁴

In 2013, the Food and Drug Administration (FDA) approved the use of the MitraClip device (Abbott Vascular) in patients of prohibitive surgical risk with severe ($\geq 3+$) degenerative MR.⁵ Since then, the number of MitraClip cases continues to increase annually.⁶ There are also a growing number of reports of successful off-label uses of the MitraClip, such as in patients with papillary muscle rupture in acute myocardial infarction or left ventricular outflow tract obstruction.⁷⁻⁸

In this case, we present an elderly female with decompensated heart failure and cardiogenic shock due to flail posterior mitral valve leaflet resulting in severe MR. Percutaneous mitral valve repair with the MitraClip device resulted in prompt resolution of shock with immediate improvement in cardiac output and renal perfusion.

Case Series

A very active 88-year-old female with past medical history of rate-controlled atrial fibrillation and hypertension presented to the emergency room with a two-month history of progressive shortness of breath. On the day of admission, she had acute worsening of symptoms and found to be in acute decompensated heart failure.

Physical examination was significant for elevated jugular venous pressure (JVP) of 11 cm, bilateral pulmonary crackles, and a new grade III/VI holosystolic murmur with radiation to the apex. Initial transthoracic echocardiogram (TTE) revealed LVEF 60%, left ventricular internal diameter diastole (LVIDd) 5.0 cm, left ventricular internal diameter systole [LVIDs] 3.2 cm, and elevated pulmonary arterial (PA) pressures (estimated at 79 mmHg via tricuspid regurgitant (TR) gradient) with development of severe MR due to flail posterior mitral valve leaflet. Right heart catheterization was significant for right atrial (RA) pressure of 16 mmHg, PA pressure of 63/30 mmHg, and pulmonary capillary wedge pressure (PCWP) of 45 mmHg (with venous [v] waves to 65 mmHg). Cardiac index via thermodilution was 0.8 L/min/m². The initial hospital course included attempts to medically optimize the patient for possible surgical mitral valve repair. However, her clinical course deteriorated rapidly with decreasing mean arterial pressure, progressive acute kidney injury, and worsening hypoxia due to pulmonary edema, despite the addition of inotropes and diuretics. The patient had an elevated Society of Thoracic Surgery (STS) operative mortality score, estimated at 35% for mitral valve replacement, and 29% for mitral valve repair. She was considered prohibitive surgical risk by a multidisciplinary mitral valve team (consisting of cardiothoracic surgery, interventional cardiology, and advanced cardiac imaging specialists) and was referred for MitraClip placement.

Intra-operative transesophageal echocardiogram (TEE) revealed a thickened, myxomatous mitral valve with a flail P2 scallop of the posterior leaflet, resulting in severe (4+) MR with an anteriorly directed, eccentric jet (mean inflow gradient 4 mmHg, mitral valve area 6.90 cm², effective regurgitant orifice area (EROA) by proximal isovelocity surface area (PISA) 78 mm², regurgitant volume 71 mL) (Table I). Under general anesthesia, with imaging guidance via three-dimensional (3D) TEE and fluoroscopy, a MitraClip device was positioned on the flail P2/P3 prolapsed segment. Following deployment of the first device, significant MR remained, so a second device was placed in a similar fashion, just lateral to the initial MitraClip.

After deployment of the second clip, the degree of MR improved notably, with only a mild (1+) residual central jet (post-clip mean gradient of 2 mmHg, mitral valve area 2.29 cm², EROA 3 mm² by PISA) (Figure 1). Intraoperative hemodynamics improved immediately, with reduction in PA pressure (67/42 mmHg to 42/29 mmHg) and augmented cardiac index post MitraClip placement (1.1 L/min/m² to 2.0 L/min/m²) (Table II). One day post-procedure, the patient reported improvement in respiratory symptoms. She was rapidly weaned off of vasopressor support, and she began to auto-diurese due to augmented cardiac output. Post-operative day one TTE demonstrated mild 1+ MR, and development of a reduced LVEF (35%). Kidney function returned to baseline four days post procedure (serum creatinine 2.9 mg/dL to 1.0 mg/dL, glomerular filtration rate 15 mL/min to 52 mL/min). Six-month follow-up echocardiogram demonstrated sustained improvement in mitral valve function, with moderate (2+) MR, and improvement in LVEF to 55% (Figure 2). The patient continues to do well post MitraClip placement, and she is able to perform activities of daily living (ADL) without dyspnea. The patient has had no recurrent hospitalizations for heart failure in the following year and remains stable from a cardiovascular standpoint.

Discussion

Our case highlights several interesting immediate and long-term effects of TMVR when compared to surgical mitral valve repair (SMVR). In the EVEREST II trial, the basis of the FDA approval of the MitraClip device, the surgical group demonstrated superior efficacy, as defined by $\leq 2+$ residual MR via TTE at 12 months (88.0% SMVR vs. 72.0% TMVR, $p = 0.04$).⁹ However, despite high rates of residual MR measured on echocardiography, patients undergoing TMVR experienced a greater reduction in symptoms compared to the surgical cohort, with a sustained reduction in NYHA functional class at 12 months (NHYA \leq II, 98% TMVR vs. 86.6% SMVR, $p = 0.03$).⁹ TMVR was also associated with an increased quality of life, improved LV re-modeling, and reduction in re-hospitalization rate for heart failure at 12 months.¹⁰ Further, TMVR had a significantly lower complication rate compared to SMVR (measured as major adverse events at 30 days, 15.0% TMVR vs. 48.0% SMVR, $p < 0.001$).⁹ Importantly, patients with cardiogenic shock were excluded from the original EVEREST studies. Our patient, despite her state of cardiogenic shock, had a positive outcome after TMVR. Further, at 1 year, with 2+ residual MR, she had sustained improvement in symptoms, without a need for re-hospitalization for heart failure. This further validates the use of TMVR in a high-risk patients with cardiogenic shock. As off-label uses of the MitraClip device increase annually, a broader patient population can continue to benefit from this life-saving device.⁷⁻⁸

A second interesting finding in our case is the notable decrease in measured LVEF (75% to 35%) following placement of the MitraClip device. The reduction in LVEF after mitral valve repair is a phenomenon previously described as afterload mismatch.¹¹ In the setting of severe MR, the left ventricle ejects a percentage of the stroke volume into the low-pressure left atrium. The failing mitral valve acts as a “pop-off valve,” which

can create a falsely elevated LVEF prior to MR repair. When the mitral valve is repaired, the option for blood to flow into the low-pressure left atrial system is essentially eliminated, creating increased LV afterload.¹² Despite an apparent reduction in LVEF, overall LV efficacy or cardiac output is often increased following placement of the MitraClip, as in our patient.¹³ Improved cardiac output is often sustained after MitraClip placement, and the long-term augmentation is in part attributed to favorable remodeling of the LV.¹⁴ As the use of the MitraClip device is expanded to patients with severely reduced EF, these hemodynamic effects are important to consider. One feared complication of MR repair in patients with severely reduced EF is low-cardiac output state. Limited studies have demonstrated an apparent increase in CO post percutaneous MV repair,¹⁵ even in patients with low EF, but more studies are needed to validate how these findings translate to clinical outcomes. Nonetheless, our patient and these limited studies help to support TMVR as a viable option in high-risk patients.

Conclusion

Our patient presented with severe degenerative mitral regurgitation, acute cardiogenic shock and renal failure. She underwent successful implantation of two MitraClip devices, and had immediate improvement in symptoms and cardiac output. This case corroborates safe and effective use of percutaneous repair of the mitral valve in cardiogenic shock. As the number of MitraClip cases continues to rise annually,⁶ we hope to see a concomitant expansion in the indications for use of this life-saving device.

Figures and Tables

Figure 1. Intraoperative TEE [transesophageal echocardiogram] pre MitraClip implantation. (A) Four-chamber view of mitral valve in systole, with flail P2 scallop of posterior leaflet. (B) Four-chamber view of mitral valve with color doppler. Severe, eccentric anteriorly directed regurgitant jet, resulting in 4+ MR [mitral regurgitation].

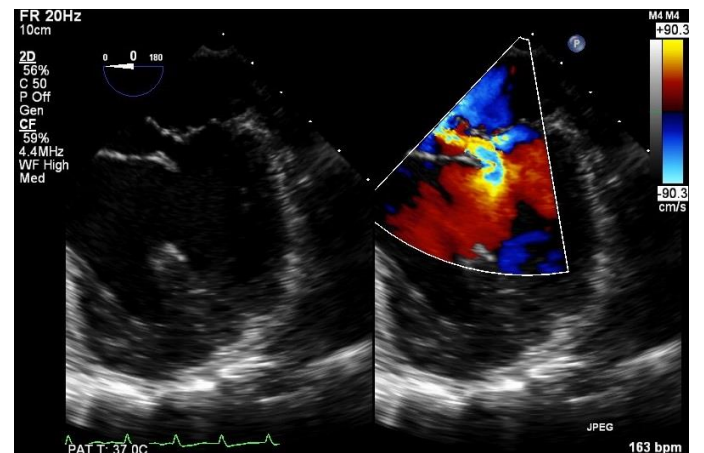


Figure 2. Intraoperative TEE [transesophageal echocardiogram] post MitraClip implantation. (A) Two-chamber view of mitral valve in systole. Resolution of flail P2 scallop of posterior leaflet. (B) Two-chamber view of mitral valve with color doppler. Small residual centrally directed jet, resulting in 1+ MR [mitral regurgitation].

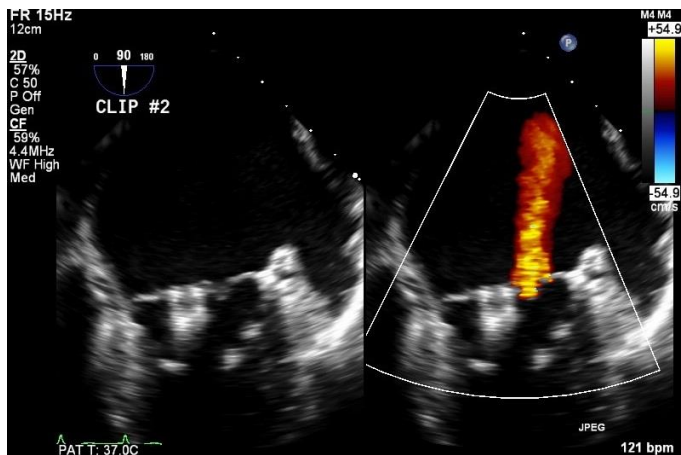


Table I. Transthoracic Echocardiographic Measures Before, Post-Operative Day One, and 1 year after MitraClip Implantation.

	Pre-MitraClip	POD1	1 year
LVEF	75%	35%	60%
Degree of MR	Severe (4+)	Mild (1+)	Moderate (2+)
PA Pressure (estimated)	43 mmHg	33 mmHg	Not obtained
MV Mean Inflow Gradient	4.0 mmHg	2.0 mmHg	3.4 mmHg
MV Area	6.90 cm ²	2.29 cm ²	1.7 cm ²
MV EROA (PISA)*	78 mm ²	3 mm ²	8 mm ²
MV Regurgitant Volume	71 mL	4 mL	10 mL

*Mitral valve effective regurgitant orifice area, as pleasured by proximal isovelocity surface area

Table II. Hemodynamic Measurements Before and After MitraClip Implantation.

	Pre-MitraClip	Post MitraClip
RA Pressure	16 mmHg	7 mmHg
PA Pressure	63/30 mmHg	42/29 mmHg
PCWP	45 mmHg	9 mmHg
V Waves	65 mmHg	absent
Cardiac Index*	0.8 L/min/m ²	2.0 L/min/m ²

*Cardiac Index as measured via transpulmonary thermodilution

REFERENCES

1. **Cioffi G, Tarantini L, De Feo S, Pulignano G, Del Sindaco D, Stefenelli C, Di Lenarda A, Opasich C.** Functional mitral regurgitation predicts 1-year mortality

in elderly patients with systolic chronic heart failure. *Eur J Heart Fail.* 2005 Dec;7(7):1112-7. PubMed PMID: 15919238.

2. **Ling LH, Enriquez-Sarano M, Seward JB, Tajik AJ, Schaff HV, Bailey KR, Frye RL.** Clinical outcome of mitral regurgitation due to flail leaflet. *N Engl J Med.* 1996 Nov 7;335(19):1417-23. PubMed PMID: 8875918.
3. **Mirabel M, Iung B, Baron G, Messika-Zeitoun D, D etaint D, Vanoverschelde JL, Butchart EG, Ravaud P, Vahanian A.** What are the characteristics of patients with severe, symptomatic, mitral regurgitation who are denied surgery? *Eur Heart J.* 2007 Jun;28(11):1358-65. Epub 2007 Mar 9. PubMed PMID: 17350971.
4. **Nishimura RA, Otto CM, Bonow RO, Carabello BA, Erwin JP 3rd, Guyton RA, O'Gara PT, Ruiz CE, Skubas NJ, Sorajja P, Sundt TM 3rd, Thomas JD; American College of Cardiology/American Heart Association Task Force on Practice Guidelines.** 2014 AHA/ACC guideline for the management of patients with valvular heart disease: a report of the American College of Cardiology/American Heart Association Task Force on Practice Guidelines. *J Am Coll Cardiol.* 2014 Jun 10;63(22):e57-185. doi:10.1016/j.jacc.2014.02.536. Epub 2014 Mar 3. Erratum in: *J Am Coll Cardiol.* 2014 Jun 10;63(22):2489. Dosage error in article text. PubMed PMID: 24603191.
5. **Beigel R, Wunderlich NC, Kar S, Siegel RJ.** The evolution of percutaneous mitral valve repair therapy: lessons learned and implications for patient selection. *J Am Coll Cardiol.* 2014 Dec 23;64(24):2688-700. doi:10.1016/j.jacc.2014.08.049. Review. PubMed PMID: 25524345.
6. **Sorajja P, Mack M, Vemulapalli S, Holmes DR Jr, Stebbins A, Kar S, Lim DS, Thourani V, McCarthy P, Kapadia S, Grayburn P, Pedersen WA, Ailawadi G.** Initial Experience With Commercial Transcatheter Mitral Valve Repair in the United States. *J Am Coll Cardiol.* 2016 Mar 15;67(10):1129-40. doi: 10.1016/j.jacc.2015.12.054. PubMed PMID: 26965532.
7. **Rodr guez-Santamarta M, Est vez-Loureiro R, Gualis J, Alonso D, P rez de Prado A, Fern ndez-V zquez F.** Percutaneous mitral valve repair with MitraClip system in a patient with acute mitral regurgitation after myocardial infarction. *Rev Esp Cardiol (Engl Ed).* 2015 Mar;68(3):259-61. doi: 10.1016/j.rec.2014.10.009. Epub 2015 Jan 20. PubMed PMID: 25612473.
8. **Garatti A, Castelvechio S, Bandera F, Medda M, Menicanti L.** Mitraclip procedure as a bridge therapy in a patient with heart failure listed for heart transplantation. *Ann Thorac Surg.* 2015 May;99(5):1796-9. doi: 10.1016/j.athoracsur.2014.07.079. PubMed PMID: 25952210.
9. **Feldman T, Foster E, Glower DD, Kar S, Rinaldi MJ, Fail PS, Smalling RW, Siegel R, Rose GA, Engeron E, Loghin C, Trento A, Skipper ER, Fudge T, Letsou GV, Massaro JM, Mauri L; EVEREST II Investigators.** Percutaneous repair or surgery for mitral regurgitation. *N Engl J Med.* 2011 Apr 14;364(15):1395-406. doi:10.1056/NEJMoa1009355. Epub 2011 Apr 4. Erratum in: *N Engl J Med.* 2011 Jul 14;365(2):189.

- Glower, Donald G [corrected to Glower, Donald D]. PubMed PMID:21463154.
10. **Lim DS, Reynolds MR, Feldman T, Kar S, Herrmann HC, Wang A, Whitlow PL, Gray WA, Grayburn P, Mack MJ, Glower DD.** Improved functional status and quality of life in prohibitive surgical risk patients with degenerative mitral regurgitation after transcatheter mitral valve repair. *J Am Coll Cardiol.* 2014 Jul 15;64(2):182-92. doi: 10.1016/j.jacc.2013.10.021. Epub 2013 Oct 31. PubMed PMID: 24184254.
 11. **Melisurgo G, Ajello S, Pappalardo F, Guidotti A, Agricola E, Kawaguchi M, Latib A, Covello RD, Denti P, Zangrillo A, Alfieri O, Maisano F.** Afterload mismatch after MitraClip insertion for functional mitral regurgitation. *Am J Cardiol.* 2014 Jun 1;113(11):1844-50. doi: 10.1016/j.amjcard.2014.03.015. Epub 2014 Mar 18. PubMed PMID: 24837263.
 12. **Siegel RJ, Biner S, Rafique AM, Rinaldi M, Lim S, Fail P, Hermiller J, Smalling R, Whitlow PL, Herrmann HC, Foster E, Feldman T, Glower D, Kar S; EVEREST Investigators.** The acute hemodynamic effects of MitraClip therapy. *J Am Coll Cardiol.* 2011 Apr 19;57(16):1658-65. doi: 10.1016/j.jacc.2010.11.043. PubMed PMID: 21492763.
 13. **Loh PH, Bourantas CV, Chan PH, Ihlemann N, Gustafsson F, Clark AL, Price S, Mario CD, Moat N, Alamgir F, Estevez-Loureiro R, Søndergaard L, Franzen O.** Catheter-based intervention for symptomatic patient with severe mitral regurgitation and very poor left ventricular systolic function - Safe but no room for complacency. *World J Cardiol.* 2015 Nov 26;7(11):817-21. doi:10.4330/wjc.v7.i11.817. PubMed PMID: 26635930; PubMed Central PMCID: PMC4660477.
 14. **Feldman T, Kar S, Elmariah S, Smart SC, Trento A, Siegel RJ, Apruzzese P, Fail P, Rinaldi MJ, Smalling RW, Hermiller JB, Heimansohn D, Gray WA, Grayburn PA, Mack MJ, Lim DS, Ailawadi G, Herrmann HC, Acker MA, Silvestry FE, Foster E, Wang A, Glower DD, Mauri L; EVEREST II Investigators.** Randomized Comparison of Percutaneous Repair and Surgery for Mitral Regurgitation: 5-Year Results of EVEREST II. *J Am Coll Cardiol.* 2015 Dec 29;66(25):2844-54. doi:10.1016/j.jacc.2015.10.018. PubMed PMID: 26718672.
 15. **Bednar F, Budesinsky T, Linkova H, Kocka V.** Invasive Hemodynamic Assessment of Cardiac Output State after MitraClip Therapy in Nonanaesthetized Patients with Functional Mitral Regurgitation. *Biomed Res Int.* 2016;2016:6296972. doi:10.1155/2016/6296972. Epub 2016 Dec 12. PubMed PMID: 28058260; PubMed Central PMCID: PMC5183761.