

UC Irvine

UC Irvine Previously Published Works

Title

Tuberculosis Variant with Rifampin Resistance Undetectable by Xpert MTB/RIF, Botswana.

Permalink

<https://escholarship.org/uc/item/82q376v2>

Journal

Emerging Infectious Diseases, 29(11)

Authors

Modongo, Chawangwa

Barilar, Ivan

Wang, Qiao

[et al.](#)

Publication Date

2023-11-01

DOI

10.3201/eid2911.230987

Copyright Information

This work is made available under the terms of a Creative Commons Attribution License, available at <https://creativecommons.org/licenses/by/4.0/>

Peer reviewed

Author contributions: E.F., O.B., and E.C. were involved in patient care. C.C., P.C., and L.L. were mycologists in charge of laboratory investigations. O.L. and F.L. reviewed the Centre national de référence des mycoses invasives et antifongiques (CNRMA) materials. D.G.H. is responsible for mycological laboratory investigations in the CNRMA and performed identification of strains and extended antimicrobial susceptibility. E.H. managed the compassionate use in F2G laboratory. E.F., O.B., and F.L. wrote the manuscript. All co-authors reviewed the manuscript.

About the Author

Dr. Faure is an associate professor at Lille University and infectious disease specialist at Lille University Hospital. His primary interests include infection in immunocompromised hosts and host–pathogen interactions.

References

- Miossec C, Morio F, Lepoivre T, Le Pape P, Garcia-Hermoso D, Gay-Andrieu F, et al. Fatal invasive infection with fungemia due to *Microascus cirrosus* after heart and lung transplantation in a patient with cystic fibrosis. *J Clin Microbiol*. 2011;49:2743–7. <https://doi.org/10.1128/JCM.00127-11>
- Liu Q, Kong L, Hua L, Xu S. Pulmonary *Microascus cirrosus* infection in an immunocompetent patient with bronchiectasis: a case report. *Respir Med Case Rep*. 2021;34:101484. <https://doi.org/10.1016/j.rmcr.2021.101484>
- Georgacopoulos O, Nunnally NS, Ransom EM, Law D, Birch M, Lockhart SR, et al. In vitro activity of novel antifungal olorofim against filamentous fungi and comparison to eight other antifungal agents. *J Fungi (Basel)*. 2021;7:378. <https://doi.org/10.3390/jof7050378>
- Wiederhold NP. Review of the novel investigational antifungal olorofim. *J Fungi (Basel)*. 2020;6:122. <https://doi.org/10.3390/jof6030122>
- Wiederhold NP, Patterson HP, Sanders CJ, Cañete-Gibas C. Dihydroorotate dehydrogenase inhibitor olorofim has potent in vitro activity against *Microascus/Scopulariopsis*, *Rasamsonia*, *Penicillium* and *Talaromyces* species. *Mycoses*. 2023;66:242–8. <https://doi.org/10.1111/myc.13548>
- Schoeppler KE, Zamora MR, Northcutt NM, Barber GR, O'Malley-Schroeder G, Lyu DM. Invasive *Microascus trigonosporus* species complex pulmonary infection in a lung transplant recipient. *Case Rep Transplant*. 2015;2015:745638. <https://doi.org/10.1155/2015/745638>
- Woudenberg JHC, Meijer M, Houbraken J, Samson RA. *Scopulariopsis* and *scopulariopsis*-like species from indoor environments. *Stud Mycol*. 2017;88:1–35. <https://doi.org/10.1016/j.simyco.2017.03.001>
- Aguilar C, Pujol I, Guarro J. In vitro antifungal susceptibilities of *Scopulariopsis* isolates. *Antimicrob Agents Chemother*. 1999;43:1520–2. <https://doi.org/10.1128/AAC.43.6.1520>
- Cuenca-Estrella M, Gomez-Lopez A, Buitrago MJ, Mellado E, Garcia-Effron G, Rodriguez-Tudela JL. In vitro activities of 10 combinations of antifungal agents against the multiresistant pathogen *Scopulariopsis brevicaulis*. *Antimicrob Agents Chemother*. 2006;50:2248–50. <https://doi.org/10.1128/AAC.00162-06>
- Skóra M, Bulanda M, Jagielski T. *In vitro* activities of a wide panel of antifungal drugs against various *Scopulariopsis* and *Microascus* species. *Antimicrob Agents Chemother*. 2015;59:5827–9. <https://doi.org/10.1128/AAC.00978-15>

Address for correspondence: Emmanuel Faure, CHRU de Lille—Service Universitaire de Maladies infectieuses, 1 rue Michel Polonovski Lille Nord 59037, France; email: emmanuel.faure@univ-lille.fr

Tuberculosis Variant with Rifampin Resistance Undetectable by Xpert MTB/RIF, Botswana

Chawangwa Modongo, Ivan Barilar, Qiao Wang, Tuduetso Molefi, Topo Makhondo, Stefan Niemann, Sanghyuk S. Shin

Author affiliations: Victus Global Botswana Organisation, Gaborone, Botswana (C. Modongo); Forschungszentrum, Borstel, Germany (I. Barilar, S. Niemann); University of California, Irvine, California, USA (Q. Wang, S.S. Shin); University of California, Los Angeles, California, USA (Q. Wang); Botswana Ministry of Health and Wellness, Gaborone (T. Molefi, T. Makhondo); German Center for Infection Research, Partner Site Hamburg-Lübeck-Borstel-Riems, Borstel, Germany (S. Niemann)

GeneXpert MTB/RIF, a tool widely used for diagnosing tuberculosis, has limitations for detecting rifampin resistance in certain variants. We report transmission of a pre-extensively drug-resistant variant in Botswana that went undetected by GeneXpert. The public health impact of misdiagnosis emphasizes the need for comprehensive molecular testing to identify resistance and guide treatment.

DOI: <https://doi.org/10.3201/eid2911.230987>

The GeneXpert (Xpert) MTB/RIF assay (Cepheid, <https://www.cepheid.com>) has enabled rapid molecular diagnosis of tuberculosis (TB) and identification of resistance to rifampin, a critical first-line TB drug (1). Operating with minimal infrastructure in a cartridge-based system, the assay is the primary TB diagnostic method in many countries (2). Xpert

MTB/RIF detects rifampin resistance by identifying mutations in an 81-bp region of the *rpoB* gene but does not detect resistance-conferring mutations outside that region (3,4). We report a case of a multidrug-resistant (MDR) *Mycobacterium tuberculosis* complex (MTBC) strain in Botswana with a rifampin resistance-conferring mutation, *rpoB* I491F, not detected by Xpert MTB/RIF (3,4). Genomic epidemiology suggested that the infection was part of a transmission chain spanning ≥ 5 years.

The patient was a 44-year-old man who, in August 2021, sought treatment at a public health clinic in Botswana for cough, fever, and night sweats. Xpert MTB/RIF detected MTBC, but no rifampin resistance. No additional drug susceptibility testing occurred during diagnosis. The case-patient reported no previous TB history. He had also newly tested positive for HIV at the time of TB diagnosis and had a CD4+ T-cell count of 117 cells/mm³, reflective of advanced HIV-associated immunosuppression. The case-patient completed the 6-month rifampin-containing regimen 2HRZ(E)/4HR and concurrently started antiretroviral therapy of tenofovir disoproxil, lamivudine, and dolutegravir. His

TB signs and symptoms resolved; sputum smear tests became negative, and by February 2022, treatment was successfully completed (Figure).

At time of TB diagnosis, the patient joined an ongoing genomic TB epidemiology study (<https://reporter.nih.gov/project-details/10327709>) involving whole-genome sequencing (WGS) of MTBC strains obtained from sputum cultures from TB-diagnosed persons in Botswana study clinics. We performed WGS using Illumina NextSeq 500/2000 (<https://www.illumina.com>) and analyzed data using MTBseq (https://github.com/ngs-fzb/MTBseq_source), as described elsewhere (5). We used variable single-nucleotide polymorphism alignments of MTBC genomes to generate the maximum likelihood phylogeny in IQ-TREE version 1.6.12 (6).

Our October 2022 analysis found that the patient carried a lineage 4.3.3 MTBC strain with the *rpoB* I491F mutation, causing rifampin resistance not detected by Xpert MTB/RIF (3,7). Moreover, WGS identified the MTBC strain as pre-extensively drug-resistant (pre-XDR), with resistance to isoniazid, ethambutol, pyrazinamide, moxifloxacin, and levofloxacin. Among the 165 study participants enrolled during 2021–2022, no

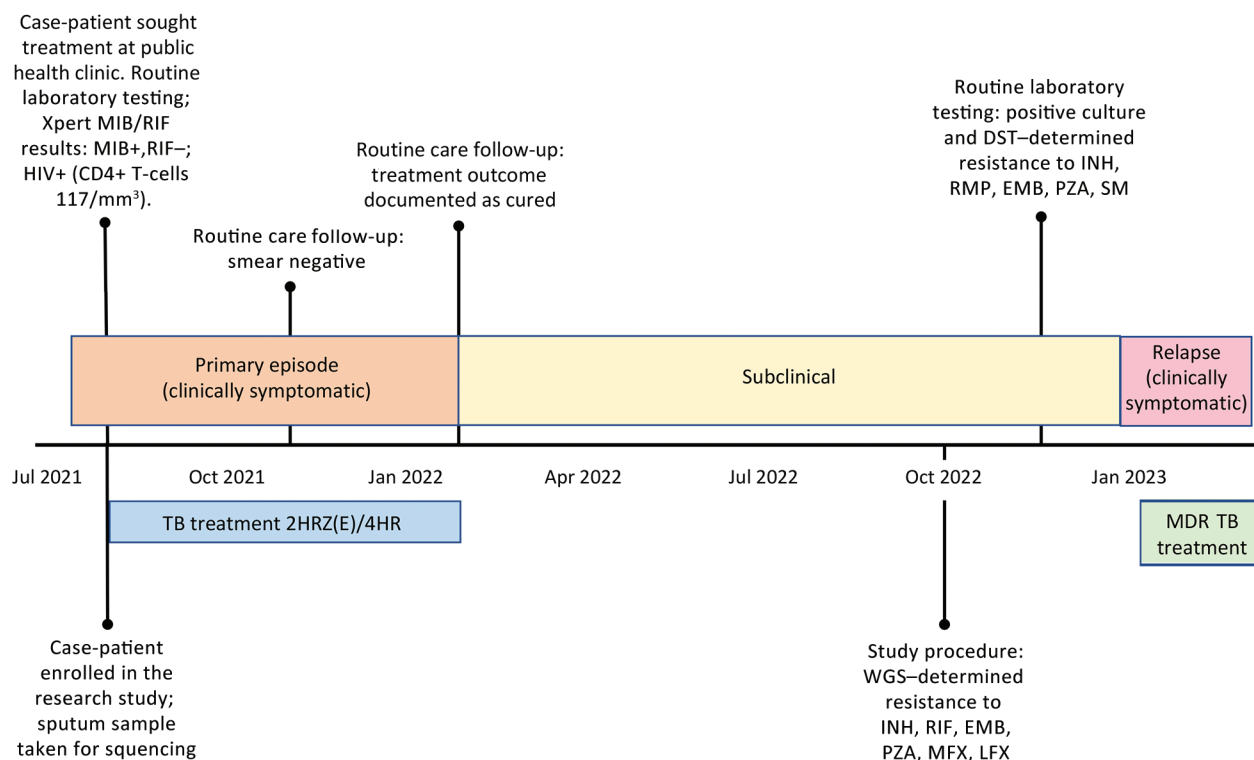


Figure. Timeline of events experienced by case-patient in Botswana from study of a rifampin-resistant TB variant not detectable using Xpert MTB/RIF assay (Cepheid, <https://www.cepheid.com>). Timeline events included routine laboratory procedures, study procedures, and timing of TB treatment. 2HRZ(E)/4HR, standard 6-month tuberculosis treatment regimen (2 months of isoniazid, rifampin and pyrazinamide, with or without ethambutol, followed by 4 months of isoniazid and rifampin); DST, drug susceptibility testing; EMB, ethambutol; INH, isoniazid; LFX, levofloxacin; MDR TB, multidrug-resistant tuberculosis; MFX, moxifloxacin; PZA, pyrazinamide; RMP, rifampin; SM, streptomycin; TB, tuberculosis; WGS, whole-genome sequencing; Xpert, GeneXpert.

other cases were found for which the isolated genome clustered with the MTBC strain from the case-patient. However, examining MTBC sequences from a previous study (8) revealed a clinical MTBC strain, BTB-2087, collected in 2016, in which the genome differed from the present strain, BTC-36, by only 5 single-nucleotide polymorphisms, suggesting that the 2 infections were part of a transmission chain in Botswana that has lasted for ≥ 5 years (Appendix Figure). We identified no epidemiologic links between the 2 persons.

MTBC strains with the *rpoB* I491F mutation have been previously documented in South Africa and Eswatini, and in Eswatini, they constituted $>60\%$ of MDR strains (3,4,7). Of interest, the 2 *rpoB* I491F strains in our study belonged to a different MTBC sublineage (4.3.3) than *rpoB* I491F strains previously identified in Eswatini (4.4.1.1) and South Africa (4.1.1.3), pointing toward convergent evolution and selection of strains that escape diagnosis in the region (3,4).

A public health investigation conducted in November 2022 found that the case-patient remained asymptomatic but was culture positive for MTBC on *Mycobacteria* growth indicator tube 960 medium (Becton Dickinson; <https://www.bd.com>). Drug susceptibility testing indicated resistance to isoniazid, rifampin, pyrazinamide, and fluoroquinolones. We tested 5 members of the patient's household with Xpert MTB/RIF and identified no additional TB cases. In January 2023, the case-patient developed TB symptoms and was placed on an individualized pre-XDR TB treatment of cycloserine, clofazimine, linezolid, bedaquiline, delamanid, pyridoxine, and para-aminosalicylic acid. No mutations linked to bedaquiline and clofazimine resistance were detected. We are conducting additional investigations to explore the extent of the outbreak of undetected MTBC strains.

This case demonstrates the clinical and public health utility of whole-genome sequencing for detecting TB drug resistance missed by conventional molecular tests. Of note, failing to detect the patient's pre-XDR TB resulted in ineffective initial treatment and potentially over a year of infectious TB. Early MDR TB detection could have led to effective initial treatment and reduced the risk of onward transmission. Currently, prevalence of MTBC strains harboring *rpoB* I491F mutation is unknown. Incorporating sequencing into a national TB drug resistance survey and continuing efforts to improve sequencing-based surveillance of drug-resistant TB in Botswana could shed light on the prevalence of MTBC strains harboring the *rpoB* I491F mutation. Those data could be used to inform updates to TB diagnostic guidelines.

In conclusion, our study highlights the utility

of WGS for identifying TB outbreaks and informing public health actions in high-TB burden countries. That approach supports the World Health Organization's recent strategic guidelines for rapidly communicating results from targeted next-generation sequencing combined with conventional tests to inform TB treatment decisions (9). Although Botswana has had remarkable success in improving HIV management, persons not adequately reached by the HIV care system remain at elevated risk of developing TB, including drug-resistant forms (10). Additional efforts are needed to ensure that high-quality HIV and TB care are delivered to underserved communities.

Acknowledgment

We acknowledge the contributions of study participants and the research team involved in data collection who made our study possible.

This work was supported by funding from the National Institute of Allergy and Infectious Diseases (R01AI147336).

About the Author

Dr. Modongo is a physician and the executive director at Victus Global Botswana Organisation in Gaborone, Botswana. Her primary research interests relate to TB and HIV, in particular drug-resistant and complicated TB and TB with adverse effects secondary to HIV or TB drugs.

References

1. Lawn SD, Nicol MP. Xpert® MTB/RIF assay: development, evaluation and implementation of a new rapid molecular diagnostic for tuberculosis and rifampicin resistance. *Future Microbiol*. 2011;6:1067–82. <https://doi.org/10.2217/fmb.11.84>
2. Ismail N, Nathanson C-M, Zignol M, Kasaeva T. Achieving universal access to rapid tuberculosis diagnostics. *BMJ Glob Health*. 2023;8:e012666. <https://doi.org/10.1136/bmjgh-2023-012666>
3. Sanchez-Padilla E, Merker M, Beckert P, Jochims F, Dlamini T, Kahn P, et al. Detection of drug-resistant tuberculosis by Xpert MTB/RIF in Swaziland. *N Engl J Med*. 2015;372:1181–2. <https://doi.org/10.1056/NEJMc1413930>
4. Makhado NA, Matabane E, Faccin M, Pinçon C, Jouet A, Boutachkourt F, et al. Outbreak of multidrug-resistant tuberculosis in South Africa undetected by WHO-endorsed commercial tests: an observational study. *Lancet Infect Dis*. 2018;18:1350–9. [https://doi.org/10.1016/S1473-3099\(18\)30496-1](https://doi.org/10.1016/S1473-3099(18)30496-1)
5. Kohl TA, Utpatel C, Schleusener V, De Filippo MR, Beckert P, Cirillo DM, et al. MTBseq: a comprehensive pipeline for whole genome sequence analysis of *Mycobacterium tuberculosis* complex isolates. *PeerJ*. 2018; 6:e5895. <https://doi.org/10.7717/peerj.5895>
6. Nguyen L-T, Schmidt HA, von Haeseler A, Minh BQ. IQ-TREE: a fast and effective stochastic algorithm for estimating maximum-likelihood phylogenies. *Mol Biol Evol*.

- 2015;32:268–74. <https://doi.org/10.1093/molbev/msu300>
7. Beckert P, Sanchez-Padilla E, Merker M, Dreyer V, Kohl TA, Utpatel C, et al. MDR M. tuberculosis outbreak clone in Eswatini missed by Xpert has elevated bedaquiline resistance dated to the pre-treatment era. *Genome Med.* 2020;12:104. <https://doi.org/10.1186/s13073-020-00793-8>
 8. Zetola NM, Moonan PK, Click E, Oeltmann JE, Basotli J, Wen X-J, et al. Population-based geospatial and molecular epidemiologic study of tuberculosis transmission dynamics, Botswana, 2012–2016. *Emerg Infect Dis.* 2021;27:835–44. <https://doi.org/10.3201/eid2703.203840>
 9. World Health Organization. Use of targeted next-generation sequencing to detect drug-resistant tuberculosis [cited 2023 Aug 22]. <https://www.who.int/publications/i/item/9789240076372>
 10. Thornton J. Botswana's HIV/AIDS success. *Lancet.* 2022; 400:480–1. [https://doi.org/10.1016/S0140-6736\(22\)01523-9](https://doi.org/10.1016/S0140-6736(22)01523-9)

Address for correspondence: Sanghyuk S. Shin, Sue and Bill Gross School of Nursing, UCI Infectious Disease Science Initiative, University of California, Irvine, 854 Health Science Quad, Irvine, CA 92697 USA; email: ssshin2@uci.edu

Scedosporium Infection in Recipients of Kidney Transplants from Deceased Near-Drowning Donor

Devprakash Choudhary, Harsimran Kaur, Vanji Nathan Subramani, Smita Pattanaik, Shivakumar S. Patil, Jasmine Sethi, Manharpreet Kaur, Priya Sreenivasan, Sheetal Thakur, Parul Gupta, Arvind Sekar, Sarbpreet Singh, Muralidharan Jayashree, Deepesh Kenwar, Shivaprakash M. Rudramurthy, Ashish Sharma

Author affiliation: Postgraduate Institute of Medical Education and Research, Chandigarh, India

DOI: <https://doi.org/10.3201/eid2911.231000>

Scedosporium aurianticum infection developed in 2 recipients of kidney transplants in India, acquired from the same deceased near-drowning donor. Given the substantial risk for death associated with *Scedosporium* infection among solid-organ transplant recipients, safety protocols for organ transplantation from nearly drowned donors should be thoroughly reevaluated and refined.

Drowning causes 236,000 deaths annually worldwide and is the third leading cause of accidental child death (1). Hospitalization from near-drowning occurs 2–20 times more frequently than fatal drownings (2). Near-drowning can result in *Scedosporium* spp. fungal infection, which causes pneumonia with a high mortality rate among nearly drowned children and young adults (2). Detecting *Scedosporium* in deceased persons is challenging, and infections thus often remain undetected. Because donor-derived *Scedosporium* infections (DDSI) from nearly drowned donors (NDD) have been linked to substantial allograft loss and increased risk for death among kidney transplant recipients (3–6), undetected *Scedosporium* poses a substantial concern when considering that person for organ donation.

We report on 2 kidney transplant recipients from an NDD, probably infected with *Scedosporium aurianticum*. The Postgraduate Institute of Medical Education and Research ethics committee approved the study. We obtained informed consent from both case-patients to ensure understanding and voluntary participation.

A 2-year-old girl weighing 15 kg was admitted to hospital with hypoxic ischemic encephalopathy and respiratory distress after a nonfatal near-drowning experience in a water tank. Her fever persisted despite antimicrobial treatment for suspected pneumonia but resolved after subsequent liposomal amphotericin B therapy. The girl was declared brain dead after 2 weeks of hospitalization, and her kidneys were retrieved for transplantation (Appendix, <https://wwwnc.cdc.gov/EID/article/29/11/23-1000-App1.pdf>).

Recipient 1, a 42-year-old woman, received 1 kidney from the deceased NDD. However, 10 days after the procedure, thrombosis developed in the graft renal artery, necessitating a graft nephrectomy. The allograft exhibited septate fungal hyphae, and grew *Scedosporium* on culture (Figure). She received a 6-month course of voriconazole and remained symptom-free on hemodialysis while awaiting a second transplant. (Appendix).

Recipient 2, a 23-year-old woman who received the other kidney from the same NDD, developed high-grade fever 3 days after transplantation. We suspected fungal infection on the basis of high β -D-glucan despite sterile blood cultures and initiated liposomal amphotericin B therapy. However, after we identified *S. aurianticum* infection in the first recipient, we switched the second patient's treatment to voriconazole. We briefly halted voriconazole therapy because of a period of elevated liver enzymes, during which the patient experienced occasional headaches and swelling developed in her left leg. The aspirate from the swelling revealed