

# UC Irvine

## UC Irvine Previously Published Works

### Title

At the crossroads of 2 alopecias: Androgenetic alopecia pattern of hair regrowth in patients with alopecia areata treated with oral Janus kinase inhibitors

### Permalink

<https://escholarship.org/uc/item/82m5s411>

### Journal

JAAD Case Reports, 6(5)

### ISSN

2352-5126

### Authors

Yale, Katerina  
Pourang, Aunna  
Plikus, Maksim V  
[et al.](#)

### Publication Date

2020-05-01

### DOI

10.1016/j.jdcr.2020.02.026

### Copyright Information

This work is made available under the terms of a Creative Commons Attribution License, available at <https://creativecommons.org/licenses/by/4.0/>

Peer reviewed

# At the crossroads of 2 alopecias: Androgenetic alopecia pattern of hair regrowth in patients with alopecia areata treated with oral Janus kinase inhibitors



Katerina Yale, MD,<sup>a</sup> Aunna Pourang, MD,<sup>a</sup> Maksim V. Plikus, PhD,<sup>b,c,d,e</sup> and  
Natasha A. Mesinkovska, MD, PhD<sup>a</sup>  
Irvine, California

**Key words:** alopecia areata; androgenetic alopecia; hair regeneration; Janus kinase (JAK) inhibitors.

## INTRODUCTION

Alopecia areata is a nonscarring hair loss disorder caused by an autoimmune attack on the hair follicle.<sup>1</sup> The disease process is thought to result from breakdown of the hair follicle immune privilege, followed by inflammatory infiltration at the base of the follicle, and then transition of the hair follicle from an actively growing (anagen) state to the dormant (telogen) state.<sup>1</sup>

Alopecia areata pathogenesis is primarily influenced by interleukin 15 produced by hair follicles in response to T-cell–secreted interferon- $\gamma$ . This process is mediated by Janus kinase (JAK) 1/2 and JAK 1/3 signaling in T cells, which respond to hair follicle–derived interleukin 15 with more interferon- $\gamma$  production, thus creating a positive pathologic feedback loop.<sup>2</sup> Accordingly, pharmacologic inhibitors of the JAK signaling pathway have emerged as highly effective treatment options for alopecia areata patients.<sup>3</sup> Disease resolution, either spontaneously or after treatment with a JAK inhibitor, results in the reentry of hair follicles into the anagen state and rapid hair growth.

Recently, JAK inhibitors have been considered for treatment of other types of hair loss, such as androgenetic alopecia.<sup>4</sup> However, they have relatively new widespread use, and treatment-induced hair regrowth patterns are difficult to predict. We present 5 cases of men with alopecia areata treated with oral JAK inhibitors, resulting in regrowth with

### Abbreviation used:

JAK: Janus kinase

androgenetic alopecia, and question the efficacy of these medications for treatment of androgenetic alopecia.

## CASE SERIES

We observed the outcomes of 4 men with severe alopecia areata treated with oral JAK inhibitors at a university medical center between 2018 and 2019. Three of the patients had alopecia totalis and 1 had greater than 70% scalp hair loss (on the frontal, parietal, and temporal areas of the scalp) at baseline. No patients reported a known history of androgenetic alopecia. All patients were treated with an oral JAK 1/2 inhibitor and followed for 24 to 40 weeks. They all experienced remarkable widespread hair regrowth while receiving the above-mentioned therapy. They all demonstrated an unexpected yet notable remnant hair loss in a bitemporal recession pattern (Fig 1). There was an obvious lack of terminal hair in the alopecic areas and exclamation point hairs were absent. The average age was 40.5 years (range 27–65 years), with an average disease length of 9 years. Patients had an average improvement in Severity of Alopecia Tool score of 56, and a Hamilton-Norwood scale score of 3 to 4 (Table I).

From the Department of Dermatology,<sup>a</sup> Department of Developmental and Cell Biology,<sup>b</sup> Sue and Bill Gross Stem Cell Research Center,<sup>c</sup> Center for Complex Biological Systems,<sup>d</sup> and NSF-Simons Center for Multiscale Cell Fate Research,<sup>e</sup> University of California—Irvine.

Funding sources: None.

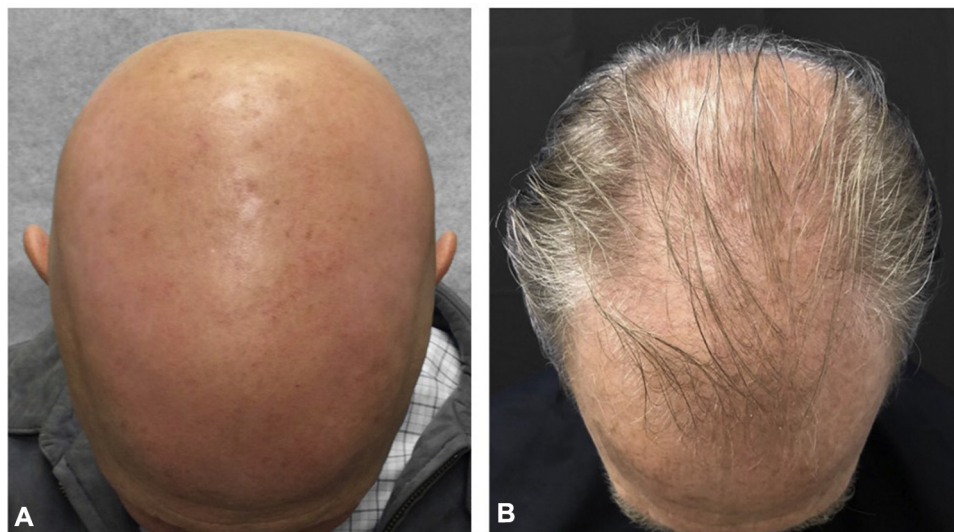
Conflicts of interest: None disclosed.

Correspondence to: Katerina Yale, MD, Department of Dermatology, University of California—Irvine, 843 Health Sciences Rd, Irvine, CA 92617. E-mail: [yalekl@uci.edu](mailto:yalekl@uci.edu).

JAAD Case Reports 2020;6:444–6.  
2352–5126

© 2020 by the American Academy of Dermatology, Inc. Published by Elsevier, Inc. This is an open access article under the CC BY-NC-ND license (<http://creativecommons.org/licenses/by-nc-nd/4.0/>).

<https://doi.org/10.1016/j.jidcr.2020.02.026>



**Fig 1.** A 65-year-old male with a 12-year history of alopecia areata (**A**) before receiving an oral JAK inhibitor (Severity of Alopecia Tool score 100) and (**B**) after 44 weeks (Severity of Alopecia Tool score 40).

**Table I.** Male patients with alopecia areata after treatment with an oral JAK inhibitor and androgenetic alopecia pattern hair regrowth

Patient	Age, years	Race	Duration of AA diagnosis, years	Treatment duration, weeks	SALT score before treatment	SALT score after treatment	Hamilton-Norwood scale score
1	27	Asian	10	36	100	49	3a
2	32	White	2	36	99.7	16	3
3	38	White	12	24	71.8	44	4
4	65	White	12	40	100	40	3v

AA, Alopecia areata; SALT, Severity of Alopecia Tool.

## DISCUSSION

Current studies on human hair regrowth patterns are in their infancy; however, numerous studies in mouse models have shown that hair regrowth occurs as propagating anagen waves, leading to large patches of hair growth.<sup>5</sup> In the clinical setting, an analogous propagating wavelike pattern can be observed in alopecia areata patients experiencing hair regrowth while receiving JAK inhibitors. Given this success in alopecia areata, there was hope that JAK inhibitors could similarly lead to rapid hair regrowth in other types of hair loss, such as androgenetic alopecia. We present this case series to highlight that a significant number of patients receiving JAK inhibitors still experience androgenetic alopecia—pattern growth.

In androgenetic alopecia, miniaturization of terminal scalp hair follicles occurs during several growth cycles, leading to a progressive reduction in anagen duration and hair-shaft diameter.<sup>6</sup> In the setting of alopecia areata, originally terminal hair follicles directly enter a long-lasting telogen state and thus do not undergo this process of progressive

miniaturization. This suggests that alopecia areata—induced telogen hair follicles do not require progressive miniaturization to manifest androgenetic alopecia.

One speculative mechanism for the seemingly immediate androgenetic alopecia onset stems from the fact that the site of inflammation in alopecia areata focuses around the base of the follicle. A study by Garza et al<sup>7</sup> found that androgenetic alopecia hair follicles have reduced numbers of secondary germ epithelial progenitor cells.<sup>7</sup> These progenitors are located below the bulge and are responsible for the formation of the hair follicle on telogen-to-anagen transition. Given that the inflammatory reaction in alopecia areata focuses around secondary germ cells during telogen, it is plausible that it depletes this progenitor population, thus making hair follicles directly susceptible to androgenetic alopecia.

The observations derived from this case series are limited by the small sample size, lack of assessment of follicular caliber, and lack of histology. Severity of

Alopecia Tool scoring was the sole measure of hair density for alopecia areata, and androgenetic alopecia was evaluated according to the Hamilton-Norwood scale.<sup>8</sup> Although the cases presented in this observation are of patients receiving JAK 1/2 inhibitors, we have observed similar hair regrowth patterns in patients receiving JAK 1/3 inhibitors in the clinic (n = 2); however, we were unable to obtain permission to use these cases in the study.

Although JAK inhibitors show promise in the treatment of alopecia areata, there has been speculation that they could be similarly used to treat androgenetic alopecia. Our finding suggests that JAK inhibitors may not be as beneficial in the treatment of androgenetic alopecia as hypothesized previously. As advances are made in the use of JAK inhibitors, clinicians should be aware of the possibility that scalp hair regrowth patterns in patients with alopecia areata may not be the same as when their alopecia areata-related hair loss occurred.

#### REFERENCES

1. McElwee KJ, Tobin DJ, Bystryn JC, King LE Jr, Sundberg JP. Alopecia areata: an autoimmune disease? *Exp Dermatol*. 1999; 8(5):371-379.
2. Xing L, Dai Z, Jabbari A, et al. Alopecia areata is driven by cytotoxic T lymphocytes and is reversed by JAK inhibition. *Nat Med*. 2014;20(9):1043-1049.
3. Phan K, Sebaratnam DF. JAK inhibitors for alopecia areata: a systematic review and meta-analysis. *J Eur Acad Dermatol Venereol*. 2019;33(5):850-856.
4. Ocampo-Garza J, Griggs J, Tosti A. New drugs under investigation for the treatment of alopecias. *Expert Opin Investig Drugs*. 2019;28(3):275-284.
5. Wang Q, Oh JW, Lee HL, et al. A multi-scale model for hair follicles reveals heterogeneous domains driving rapid spatio-temporal hair growth patterning. *Elife*. 2017;6:pii: e22772.
6. Tobin DJ. Gerontobiology of the hair follicle. In: Trüeb R, Tobin D, eds. *Aging Hair*. Berlin: Springer; 2010:1-8.
7. Garza LA, Yang CC, Zhao T, et al. Bald scalp in men with androgenetic alopecia retains hair follicle stem cells but lacks CD200-rich and CD34-positive hair follicle progenitor cells. *J Clin Invest*. 2011;121(2):613-622.
8. Norwood OT. Male pattern baldness: classification and incidence. *South Med J*. 1975;68(11):1359-1365.