

UC Davis

Dermatology Online Journal

Title

Familial pseudoxanthoma elasticum associated with multiple comedones

Permalink

<https://escholarship.org/uc/item/82j7181p>

Journal

Dermatology Online Journal, 23(9)

Authors

Maarouf, Melody
Sharon, Victoria R
Sivamani, Raja K
et al.

Publication Date

2017

DOI

10.5070/D3239036481

Copyright Information

Copyright 2017 by the author(s). This work is made available under the terms of a Creative Commons Attribution-NonCommercial-NoDerivatives License, available at <https://creativecommons.org/licenses/by-nc-nd/4.0/>

Peer reviewed

Familial pseudoxanthoma elasticum associated with multiple comedones

Melody Maarouf¹ MHS, Victoria R Sharon² MD DTMH, Raja K Sivamani³ MD MS CAT, Neha Prakash⁴ MD, TH Bipin⁵ MD, Tracy Davis⁶ MD PhD, Vivian Y Shi⁷ MD

Affiliations: ¹College of Medicine, University of Arizona, Tucson, Arizona, ²Department of Dermatology, Hofstra Northwell School of Medicine, Hempstead, New York, ³Department of Dermatology, University of California, Davis, Sacramento, California, ⁴Department of Dermatology, The Permanente Medical Group, Kaiser Permanente Northern California, Roseville Medical Center, California, ⁵Senior Consultant, BABINA Diagnostics, Imphal, India, ⁶Dermpath Diagnostics, Tucson, Arizona, ⁷Division of Dermatology, Department of Medicine, University of Arizona, Tucson, Arizona

Corresponding Author: Vivian Y. Shi MD, Assistant Professor of Medicine, Dermatology Division, Arizona Cancer Center, 1515 N. Campbell Ave. (PO Box 245024), Building #222, Levy Bldg. 1906E, Tucson, AZ 85724-5024, Email: vshi@email.arizona.edu

Abstract

Pseudoxanthoma elasticum (PXE) is an autosomal recessive disorder characterized by atypical elastic fibers that causes connective tissue abnormalities of the skin, eyes, and heart, among other organs. The disorder is rare, with a classic presentation of yellow-orange cobblestone-like papules on flexural areas, lax skin, ocular degeneration, and moribund vasculature in multiple organs. There is wide variability in the presentation of the affected organs [1]. We present two sisters with classic cutaneous findings of PXE with the additional unusual findings of numerous open comedones on the neck. To our knowledge, this is the first report of numerous open comedones in familial PXE.

Keywords: pseudoxanthoma elasticum, comedones, acneiform, connective tissue, elastin

Introduction

Pseudoxanthoma elasticum (PXE) is an autosomal recessive disorder associated with elastic tissue fragmentation and calcification caused by inactivating mutations in the *ATP-binding cassette subfamily C member 6* (ABCC6) gene. Though the pathophysiology of PXE is not entirely elucidated, the metabolic hypothesis is a widely accepted theory. The ABCC6 gene product is an ATP-binding cassette protein involved in the active transport of nucleoside triphosphates (NTP), which gives rise to pyrophosphate, a molecule that prevents mineralization within elastic tissue. The absence of

normal ABCC6 protein structure and function alters pyrophosphate level, leading to unwanted elastic tissue mineralization [2, 3]. In vitro studies have shown that serum from a PXE patient is unable to prevent calcium and phosphate precipitation in smooth muscle cell culture [4]. Despite the predominant expression of the ABCC6 gene product in the kidney and liver, phenotypic abnormalities are most commonly seen on the skin, eye, and cardiovascular system [5].

PXE is rare, with an estimated prevalence of approximately 1 in 100,000, with a 2:1 female predominance without racial or ethnic predilection [6]. Disease onset is typically within the second or third decade of life. When cutaneous manifestations are mild, the disease may go undiagnosed until the seventh decade of life [7]. Diagnosis is typically made through both clinical presentation and histopathologic examinations of the skin. Cutaneous manifestations result from degeneration, disorganization, and calcification of elastic fibers within the reticular dermis. Lesions commonly start on the neck and progress in a cephalad-to-caudad fashion. Patients develop characteristic yellow-orange papules that coalesce to form pebbled plaques, typically affecting flexural areas of the neck, axillae, and the periumbilical region. Degeneration and fragmentation of elastic fibers causes lax and redundant skin. Calcified elastic fibers can be confirmed by a von Kossa stain on histopathologic examination [7, 8].

Although cutaneous manifestations are often the initial clue to the diagnosis of PXE, they are not

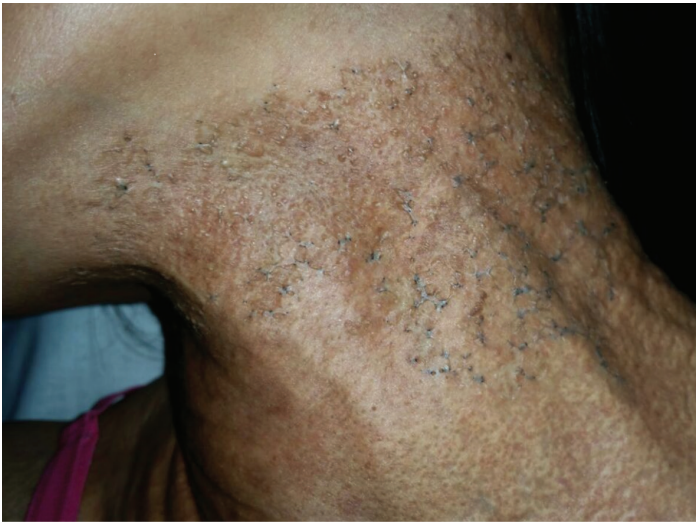

Figure 1. Older sister: Multiple open comedones associated with plaques are an unusual initial presentation of PXE.

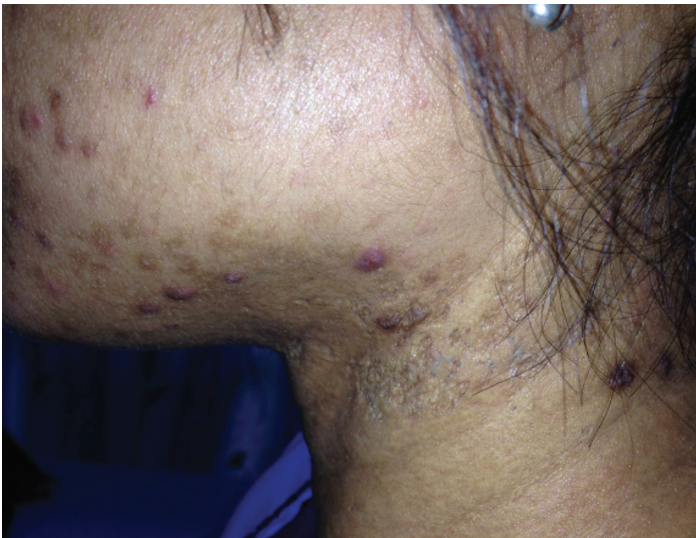

Figure 2. Younger sister: In contrast to her older sister, this patient demonstrates less involvement of the nuchal region. Multiple open comedones are also present and associated with a scar-like plaque.

pathognomonic and diagnostic criteria also require the presence of retinal angioid streaks. Angioid streaks are breaks in the Bruch membrane, which is the elastin-rich tissue layer between the retina and capillaries that supply the choroid. The destruction of this layer leads to central vision loss. Late in the course of the disease, vascular anomalies begin to appear. Mineralization of the internal elastic laminae causes vasculature to break down leading to myocardial and cerebral ischemia and infarction [6]. The morbidity and mortality from PXE are classically a result of cardiovascular complications, such as arterial hypertension, restrictive cardiomyopathy, mitral valve prolapse or stenosis, stroke, and sudden

cardiac failure [9, 10].

The presence of multiple comedones is a very rare finding in PXE without prior reports of familial cases. Herein, we report familial PXE in two sisters living in the remote mountainous regions of eastern India whose cutaneous manifestations include numerous open comedones.

Case Synopsis

During a medical outreach trip to Tuensang, a village in eastern India, two otherwise healthy sisters, 22 and 44 years-old, presented with firm plaques studded with numerous open comedones on their necks. In contrast to her older sister (**Figure 1**), the younger patient demonstrates less involvement of the nuchal region. Multiple open comedones are also present and associated with a scar-like plaque (**Figure 2**).

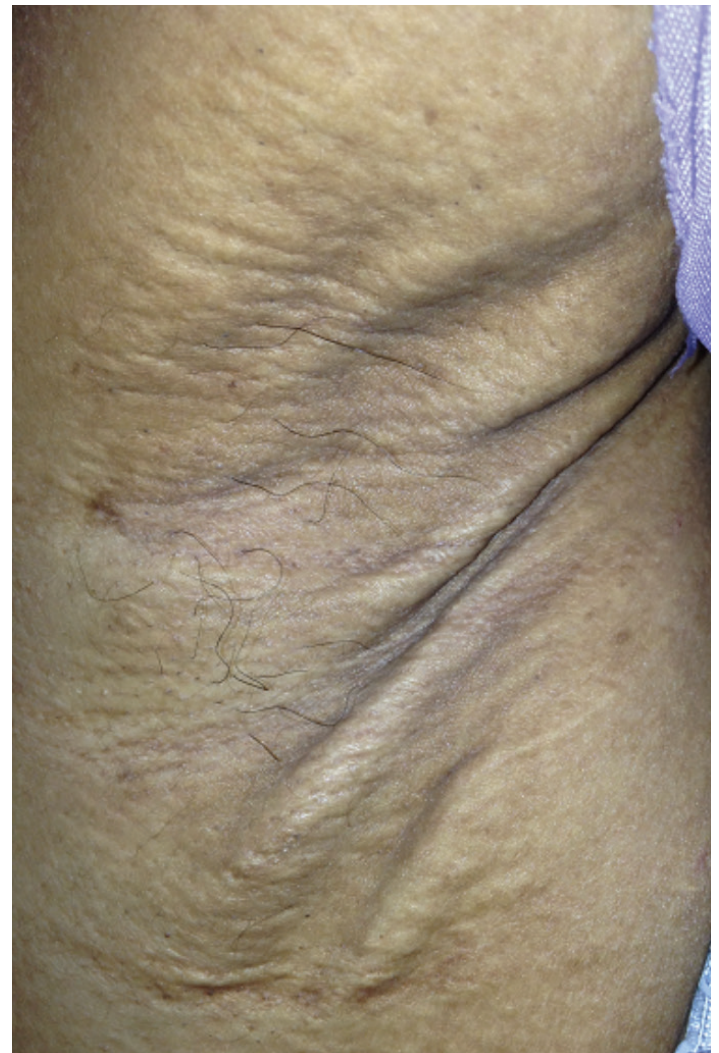

Figure 3. Younger sister: Axillary fold demonstrating multiple skin colored papules forming a cobblestone-like plaque, associated with skin laxity and wrinkling.

They endorsed onset since adolescence. The younger sister also reported severe acneiform lesions on her face since the age of 12. Both sisters had multiple 2 to 5mm round yellow papules coalescing into cobblestone plaques with associated skin laxity. The younger sister's axillary fold demonstrates multiple skin colored papules forming a cobblestone-like plaque, associated with skin laxity and wrinkling (**Figure 3**). The older sister demonstrated redundant skin folds and increased laxity over the abdomen (**Figure 4**). The open comedones were limited to the neck in both patients. Both patients noted progressive blurry vision over the past 2 years. However, fundoscopic evaluation was unable to be performed because of a lack of medical resources in the village health clinic. Despite unremarkable smart Tel-based electrocardiograms, the younger sister reported shortness of breath both on exertion and at rest. The patients had four other siblings, but to the sisters' knowledge, no other family member had dermatologic, ocular, or cardiovascular pathology suggestive of PXE.

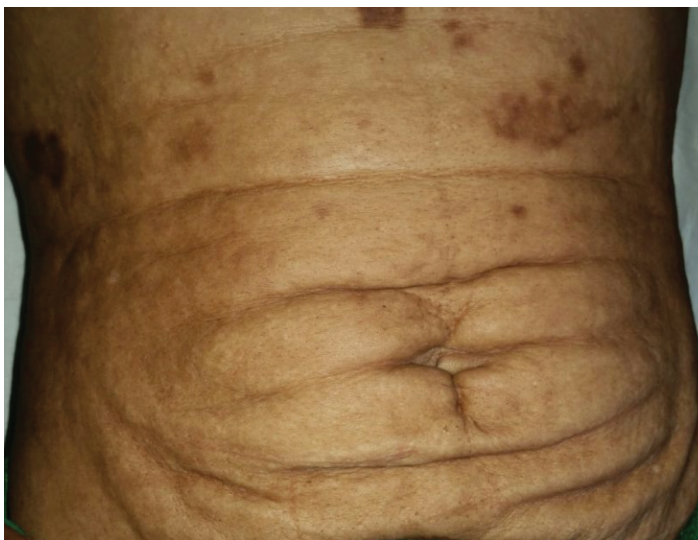

Figure 4. Older sister: Redundant skin folds and increased laxity over the abdomen. PXE lesions tend to develop in a cephalo-caudal fashion starting in late childhood.

Incisional biopsies of the left lateral neck were performed on both sisters. Microscopic review of affected skin demonstrates abnormal accumulation of elastic fibers particularly in the mid and upper reticular dermis with sparing of the papillary dermis except in areas undergoing transepidermal elimination. Affected elastic fibers are basophilic and fragmented with a thickened and curled or frayed

morphology (**Figure 5**). A von Kossa stain highlights the haphazard accumulation of calcified fragmented, thickened and curled elastic fibers in the reticular dermis (**Figure 6**).

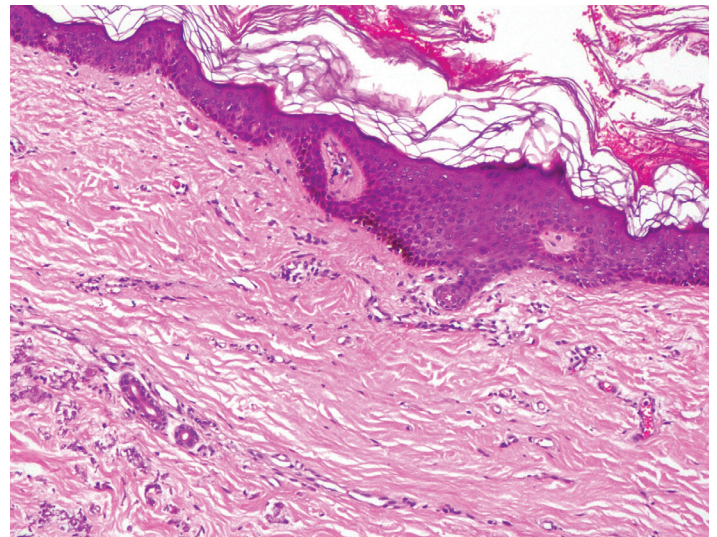


Figure 5. Sections show orthokeratotic epidermis with haphazard accumulation of basophilic calcified elastic fibers in the reticular dermis and sparing of the papillary dermis. The elastic fibers are abnormally thickened and show degenerative fragmentation with curled and frayed morphology. H&E, 10%.

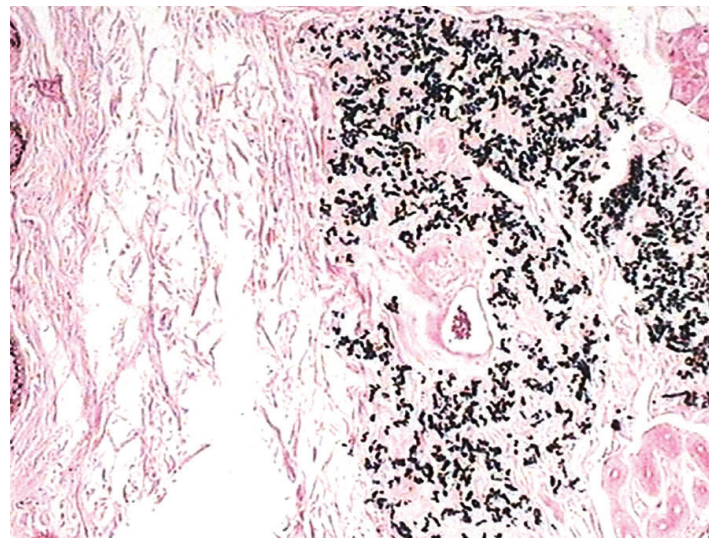


Figure 6. A von Kossa stain highlights the haphazard accumulation of calcified, fragmented, thickened and curled elastic fibers in the reticular dermis, 10%.

Since both patients were seen in rural India with limited resources, a thorough workup was not feasible. Additional testing for patients with PXE should include ophthalmologic evaluation for tears in Bruch membrane and cardiovascular evaluation for mineralization of the internal elastic laminae, which may present as myocardial and cerebral ischemia

and infarction.

Case Discussion

PXE is inherited in an autosomal recessive manner, though sporadic mutations of the *ABCC6* gene are common. There is marked clinical heterogeneity and even familial cases may differ in disease severity as well as in the number of organ systems involved [9, 10]. The true prevalence of familial PXE is unknown [9]. Our patients presented with dermatologic findings and reported ocular symptoms, but had a normal electrocardiogram. Other family members were not known to have cutaneous, ocular, or cardiovascular deficits. Since PXE is slowly progressive, other younger siblings may manifest signs of disease later in life.

A review conducted by Finger et al, in 2009 revealed 110 different inactivating mutations of the *ABCC6* gene. The authors did not find any genotype-phenotype correlation, which may relate to confounding factors such environmental and nutritional influences and mutations in other modifying genes [7]. For instance, there has been an alarming acceleration of clinical presentation in children who have a high intake of dairy products rich in calcium and phosphate [8]. Clinical cutaneous or ocular findings are usually necessary to render a diagnosis of PXE. Other common manifestations include decreased or absent peripheral pulses (25%), arterial hypertension (22.5%), angina pectoris (19%), intermittent claudication (18%), and gastrointestinal hemorrhage (13%), [7].

Effective treatments for systemic mineralization and fragmentation of PXE are currently lacking, though certain interventions may reduce associated complications. Surgical cosmetic treatment can be performed to mitigate the appearance of skin laxity and aging. Subcutaneous rhytidectomy and neck lift have had satisfactory results with minimal complications [11]. Carbon dioxide laser skin resurfacing had promising results with significant improvement in skin irregularity and elasticity, color, texture/hydration, and volume. Results were maintained at 2-year follow up [12].

Decreased abnormal calcified elastic fibers in the dermis following a low-calcium and high-magnesium

diet suggests that phosphate binders may be in treating PXE by reducing serum calcium levels. Phosphate binders lower the availability of calcium to cause aberrant mineralization and degeneration of elastic fibers. A preliminary study using aluminum hydroxide in 6 patients showed marked improvement of skin lesions in 3 of the patients with reduction of dermal calcification. One-year follow-up showed no clinically significant progression of ocular damage. Murine studies have shown that supplementation with fetuin-A, a systemic inhibitor of calcification, also reduces soft tissue mineralization by 70% at 12 weeks of use [11]. The systemic administration of magnesium, phosphate binders, or fetuin-A provides a potential approach to improve dermatologic manifestations and reduce ocular and cardiovascular morbidity [9, 10].

The presence of multiple nuchal comedones is an unusual feature of PXE not previously reported in the English literature in the familial setting. To our knowledge, there are two other cases of PXE with comedone described in medical literature [13, 14]. **Table 1** demonstrates the characteristics of the four patients with comedonal PXE, illustrating the distinctive presentation in our report. Unfortunately, the reports were not all published in English literature, but it is clear that our case is the first case in the literature of familial PXE with comedones. Other aspects of presentation were similar among the patients. The age at which PXE with comedones was diagnosed ranged from 16-44 years, with most cases presenting in females. Similar enough to our cases (Patients 1 and 2), Patient 3 was from Japan. PXE and associated comedones were limited to neck, axillae, and antecubital fossa. Unlike our case, the other patients presented with significant extra-cutaneous manifestations, such as retinal angioid streaks [13, 14]. Patient 3 also had diffuse obstruction due to stenosis in the left anterior descending artery, left circumflex artery, and right coronary artery [14]. Our two patients reported mild angina but had normal screening EKGs. Additional workup was not possible because of geographic and economic limitations of her village. Patient 3 had similar histopathology as our patients. It was noted that there were swollen and irregularly clumped elastic fibers in the upper and mid-dermis with calcium deposit von Kossa staining surrounding the plugged hair follicles, characteristic

Table 1. Patient characteristics of all reported patients with comedonal PXE in the literature.

Patient	Familial PXE	Age (at diagnosis)	Sex	Race	Lesion Location	Systemic Manifestations	Pathology
Younger Sister	Yes	22	Female	Indian	Neck, axillae, antecubital fossae, abdomen	Cutaneous lesions, angina, unspecified ocular abnormality	Orthokeratotic epidermis with degenerated elastic fibers of the dermis; von Kossa staining highlights an abundance of degenerated calcified elastic fibers.
Older sister	Yes	44	Female	Indian	Neck, axillae, antecubital fossae, abdomen	Cutaneous lesions, unspecified ocular abnormality	Orthokeratotic epidermis with degenerated elastic fibers of the dermis; von Kossa staining highlights an abundance of degenerated calcified elastic fibers. Numerous yeast forms and hyphae of a fungus in the stratum corneum resembling <i>Malasseiza sp.</i>
Patient 3 [14]	No	32	Female	Japanese	Neck, axillae, cubital fossae, groin	Cutaneous lesions, angina, retinal angioid streaks, stenosis of major cardiac vessels	Swollen and irregularly clumped elastic fibers in the upper and mid-dermis; von Kossa's stain showed presence of calcium deposits
Patient 4 [13]	No	16	Female	Unknown	Flexural, cervical, and neck	Cutaneous lesions, bilateral retinal angioid streaks	Inflammatory lesions (characterized by phagocytosis of pathological elastic fibers inducing granuloma) with degenerated fibers were observed around large comedones

of comedone presence. Patient 4 had a more unique histopathologic presentation, with inflammatory infiltrates surrounding and degenerated elastic fibers. Phagocytosis of degenerating elastic fibers induces granuloma formation and the histologic findings of PXE were present around large comedones. Von Kossa staining was not present in the granulomatous lesions, but positive in the comedones. The authors theorized that calcification may play a protective role for the elastopathic fibers from being phagocytosed [13].

Comedone formation within classic PXE lesions may be related to UV-induced degeneration of elastic fibers in the dermis, similar to those seen in Favre-Racouchot syndrome [14]. We postulate that chronic intense UV exposure at high elevation may have accelerated premature comedone formation within elastic degeneration in our patients. This hypothesis

is supported by the distribution of comedones on sun-exposed sites (lateral neck) with relative sparing in adjacent sun-protected areas (submental region). These two cases demonstrate the importance of diligent sun protection in patients with PXE to prevent comedone formation and worsened elastic degeneration. A hypothesis for the expression of comedones solely on the neck correlates well with PXE's typical cephalo-caudal progression [7]. Perhaps if these sisters were examined years later, the comedones would have progressed to more caudal regions.

Conclusion

Pseudoxanthoma elasticum is a rare genodermatosis caused by a mutation in the ABCC6 gene resulting in elastic fiber degeneration in multiple organ systems. We present two rare cases of PXE associated with multiple open comedones confirmed with skin

biopsy in two sisters. To our understanding, this is the first report of familial comedonal PXE in the literature. Although some cases have late-onset in adulthood, it is imperative for healthcare providers to recognize this unusual cutaneous presentation of PXE and promptly pursue further ophthalmologic, cardiovascular, and neurologic evaluation.

References

1. Uitto J, Bercovitch L, Terry SF, Terry PF. Pseudoxanthoma elasticum: progress in diagnostics and research towards treatment : Summary of the 2010 PXE International Research Meeting. *Am J Med Genet A*. 2011;155A(7):1517-1526. [PMID: 21671388].
2. Bergen AA, Plomp AS, Hu X, de Jong PT, Gorgels TG. ABCC6 and pseudoxanthoma elasticum. *Pflugers Arch*. 2007;453(5):685-691. [PMID: 16604369].
3. Jansen RS, Kucukosmanoglu A, de Haas M, et al. ABCC6 prevents ectopic mineralization seen in pseudoxanthoma elasticum by inducing cellular nucleotide release. *Proc Natl Acad Sci U S A*. 2013;110(50):20206-20211. [PMID: 24277820].
4. Jiang Q, Endo M, Dibra F, Wang K, Uitto J. Pseudoxanthoma elasticum is a metabolic disease. *J Invest Dermatol*. 2009;129(2):348-354. [PMID: 18685618].
5. Legrand A, Cornez L, Samkari W, et al. Mutation spectrum in the ABCC6 gene and genotype-phenotype correlations in a French cohort with pseudoxanthoma elasticum. *Genet Med*. 2017;19(8):909-917. [PMID: 28102862].
6. Revenga Arranz F, Gamazo Carrasco M, Nevado Lopez-Alegria L, Pimentel Leo J. [Familial pseudoxanthoma elasticum]. *Rev Clin Esp*. 1996;196(7):458-460. [PMID: 8927764].
7. Finger RP, Charbel Issa P, Ladewig MS, et al. Pseudoxanthoma elasticum: genetics, clinical manifestations and therapeutic approaches. *Surv Ophthalmol*. 2009;54(2):272-285. [PMID: 19298904].
8. Li Q, Jiang Q, Pfindner E, Varadi A, Uitto J. Pseudoxanthoma elasticum: clinical phenotypes, molecular genetics and putative pathomechanisms. *Exp Dermatol*. 2009;18(1):1-11. [PMID: 19054062].
9. Jin L, Jiang Q, Wu Z, et al. Genetic Heterogeneity of Pseudoxanthoma Elasticum: The Chinese Signature Profile of ABCC6 and ENPP1 Mutations. *J Invest Dermatol*. 2015;135(9):2338. [PMID: 26084751].
10. Terry SF, Bercovitch L. Pseudoxanthoma Elasticum. In: Pagon RA, Adam MP, Ardinger HH, et al., eds. *GeneReviews(R)*. Seattle (WA)1993. [PMID: 20301292].
11. Marconi B, Bobyr I, Campanati A, et al. Pseudoxanthoma elasticum and skin: Clinical manifestations, histopathology, pathomechanism, perspectives of treatment. *Intractable Rare Dis Res*. 2015;4(3):113-122. [PMID: 26361562].
12. Salles AG, Remigio AF, Moraes LB, Varoni AC, Gemperli R, Ferreira MC. Pseudoxanthoma Elasticum Treatment with Fractional CO2 Laser. *Plast Reconstr Surg Glob Open*. 2014;2(9):e219. [PMID: 25426402].
13. Loche F, Raynal H, Bazex J. Acne-like eruption induced by pseudoxanthoma elasticum: effectiveness of liquid nitrogen cryotherapy. *Eur J Dermatol*. 1998;8(1):63-65. [PMID: 9649690].
14. Nogita T, Maeguchi M, Kawashima M, Hidano A. An unusual presentation of pseudoxanthoma elasticum with multiple comedones on the neck. *Br J Dermatol*. 1991;124(6):612. [PMID: 2064951].