

UC Davis

Dermatology Online Journal

Title

Frontal fibrosing alopecia in a 46-year-old man

Permalink

<https://escholarship.org/uc/item/82h822bg>

Journal

Dermatology Online Journal, 22(12)

Authors

White, Forrest
Callahan, Shields
Kim, Randie H
et al.

Publication Date

2016

DOI

10.5070/D32212033392

Copyright Information

Copyright 2016 by the author(s). This work is made available under the terms of a Creative Commons Attribution-NonCommercial-NoDerivatives License, available at <https://creativecommons.org/licenses/by-nc-nd/4.0/>

Peer reviewed

Frontal fibrosing alopecia in a 46-year-old man

Forrest White, MD, Shields Callahan, MD, Randie H. Kim, MD, PhD, Shane A Meehan, MD, Jennifer Stein, MD, PhD

Ronald O. Perelman Department of Dermatology, NYU School of Medicine, NYU Langone Medical Center

Abstract

Frontal fibrosing alopecia is a scarring alopecia that is characterized by recession of the frontotemporal hairline with the frequent loss of eyebrows. It predominantly affects postmenopausal women and only rarely affects men. We report the case of a 46-year-old man with a ten-year history of an erythematous patch with perifollicular erythema at the superior aspect of the forehead and frontotemporal hairline. A skin biopsy specimen showed a perivascular, lymphocytic infiltrate with periinfundibular fibrosis. These findings established a diagnosis of frontal fibrosing alopecia. The pathogenesis of this condition is poorly understood but may be hormonally-mediated.

Case Presentation

PATIENT: 46-year-old man

DURATION: Ten years

DISTRIBUTION: Frontal hairline and forehead

HISTORY: A 46-year-old man presented to the Skin and Cancer Unit for the evaluation of redness at the frontal hairline of ten-years duration. He denied pain or pruritus. He denied hair loss and reported that his hairline had not receded since the redness appeared. The area had not been treated. He was not taking any medications. He had no history of autoimmune diseases.

PHYSICAL EXAMINATION: On the superior aspect of the forehead and extending to the frontal hairline was an erythematous patch with perifollicular accentuation of the erythema. No scale was present. The frontal hairline had recession at the

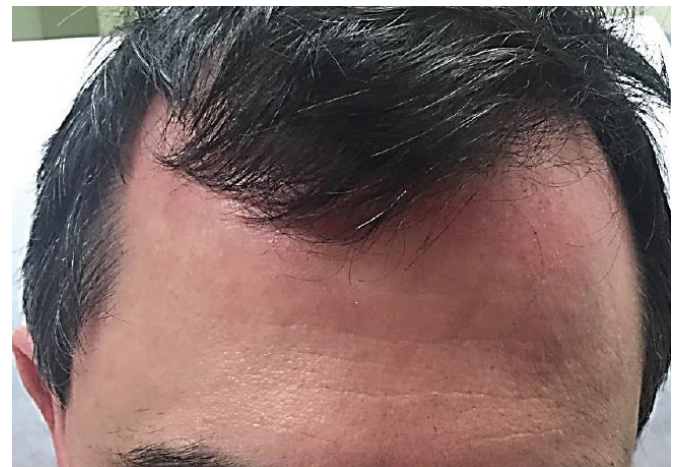
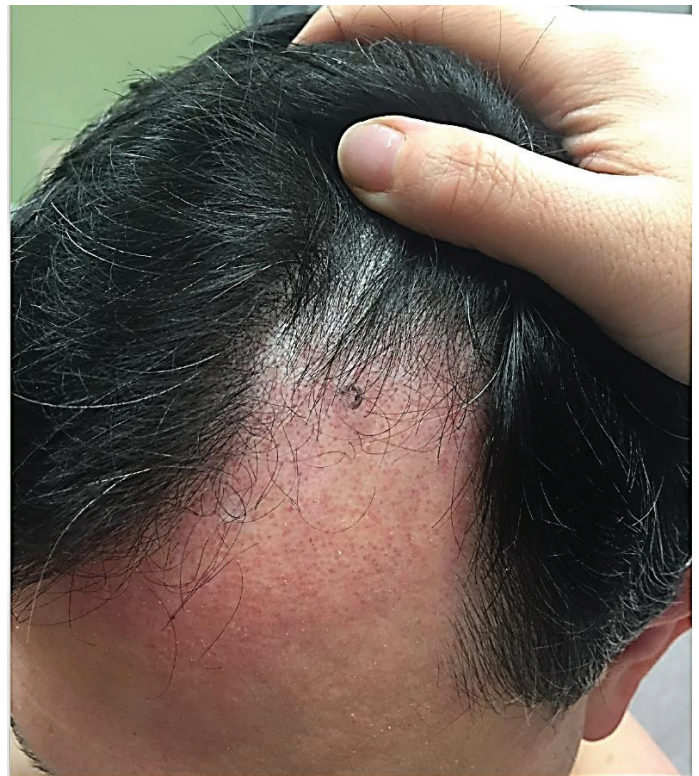
Figure 1. Recession at the frontotemporal hairline, along with an erythematous patch with perifollicular accentuation of erythema from the forehead to hairline.

frontotemporal hairline bilaterally, with isolated hairs present (**Figure 1**). The remainder of the scalp was normal. There was no alopecia of the eyebrows.

LABORATORY DATA: None

HISTOPATHOLOGY: There is a decreased number of terminal anagen follicles. A band-like, lymphocytic infiltrate is present at the dermoepidermal junction of the follicular epithelium. Rare necrotic keratinocytes are identified within the follicular epithelium. Perifollicular fibrosis also is present. The overlying epidermis is unremarkable (**Figure 2**).

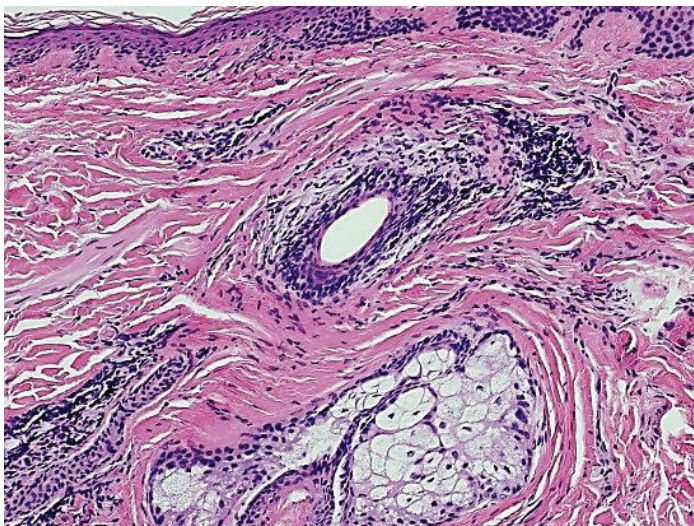


Figure 2. Biopsy showing decreased number of terminal anagen follicles. A band-like, lymphocytic infiltrate is present at the dermoepidermal junction of the follicular epithelium. Rare necrotic keratinocytes are within the follicular epithelium. Perifollicular fibrosis also present

DIAGNOSIS: Frontal fibrosing alopecia

Discussion

Frontal fibrosing alopecia (FFA), which was first described in 1994, is a scarring alopecia that is characterized by recession of the frontotemporal hairline [1-5]. It is increasing in incidence and predominately affects Caucasian, postmenopausal women [2-3, 6-8]. Partial or complete alopecia of the eyebrows occurs in the majority of patients and may precede the loss of scalp hair. Alopecia of body hair and, less commonly, of eyelashes also may occur [2-4]. Patients often complain of pruritus, pain, and burning, but some cases are asymptomatic. Examination shows perifollicular

erythema in a majority of patients, and many also have perifollicular hyperkeratosis. Isolated lonely hairs often are present [2].

Some authors consider FFA to be a clinical variant of lichen planopilaris (LPP) while others consider it to be a distinct entity [3, 4]. FFA and LPP have similar histopathologic findings of a lichenoid, lymphocytic, inflammatory infiltrate that involves the isthmus and infundibulum, apoptotic keratinocytes in the external root sheath, perifollicular fibrosis, and fibrous tracts [6,9]. However, FFA and LPP have differing clinical presentations [2]. In addition, the prevalence of lichen planus among patients with FFA is low [6].

The pathogenesis of FFA is unclear; genetic, immune, and hormone-mediated mechanisms have been proposed [2, 5]. Familial cases have been described [3]. In 16.5-30% of cases, FFA has been reported to coexist with other autoimmune diseases, which include vitiligo, Sjögren's syndrome, and discoid lupus erythematosus [4,10].

Men are infrequently affected by FFA. In one review of 355 patients, only 12 were men [5]. Another review found that only one of 62 patients was a man. That male patient had received estrogen therapy as part of neoadjuvant hormonal therapy for prostate cancer eight years before developing FFA [2]. In light of the fact that most patients with FFA are postmenopausal women, the possibility of a hormonal etiology has been raised. Women with FFA have a prevalence of early menopause of 14% compared to only 6% in the general population [5]. In addition, FFA has affected a number of women after a hysterectomy [10, 11]. In patients with FFA, it is possible that the effects of decreased estrogen on hair cycle regulation provoke an inflammatory response of the hair follicle. A hormonally-mediated mechanism of disease would help explain the benefit of antiandrogen therapy with finasteride and dutasteride in treating this condition [5].

The optimal treatment of FFA has not been established, and randomized trials comparing different therapies are lacking. Treatment modalities include topical and intralesional glucocorticoids, tetracyclines, hydroxychloroquine, finasteride,

dutasteride, and mycophenolate mofetil [2-5]. Our patient declined systemic therapy and was treated initially with clobetasol foam.

References

1. Kossard S. Postmenopausal frontal fibrosing alopecia: scarring alopecia in a pattern distribution. *Arch Dermatol* 1994; 130: 770
2. Banka N, et al. Frontal fibrosing alopecia: a retrospective clinical review of 62 patients with treatment outcome and long-term follow-up. *Int J Dermatol* 2014; 53: 1324
3. Navarro-Belmonte MR, et al. Case series of familial frontal fibrosing alopecia and a review of the literature. *J Cosmet Dermatol* 2015; 14: 64
4. MacDonald A, et al. Frontal fibrosing alopecia: a review of 60 cases. *J Am Acad Dermatol* 2012; 67: 955
5. Vañó-Galván S, et al. Frontal fibrosing alopecia: a multicenter review of 355 patients. *J Am Acad Dermatol* 2014; 70: 670
6. Kossard S, et al. Postmenopausal frontal fibrosing alopecia: a frontal variant of lichen planopilaris. *J Am Acad Dermatol* 1997; 36: 59
7. Moreno-Ramirez D, Camacho Martinez F. Frontal fibrosing alopecia: a survey in 16 patients. *J Eur Acad Dermatol Venereol* 2005; 19: 700
8. Vaisse V, et al. Postmenopausal frontal fibrosing alopecia: 20 cases. *Ann Dermatol Venereol* 2003; 130: 607
9. E. Poblet, et al. Frontal fibrosing alopecia versus lichen planopilaris: a clinicopathological study. *Int J Dermatol* 2006; 45: 375
10. Tan KT, Messenger AG. Frontal fibrosing alopecia: clinical presentations and prognosis. *Br J Dermatol* 2009; 160: 75
11. Ladizinski B, et al. Frontal fibrosing alopecia: a retrospective review of 19 patients seen at Duke University. *J Am Acad Dermatol* 2013; 68: 749