

# UC Irvine

## UC Irvine Previously Published Works

### Title

Complications of hydroxyapatite reconstruction of suboccipital craniotomy

### Permalink

<https://escholarship.org/uc/item/81m4w21h>

### Authors

Djalilian, H  
Charbel, F  
Mafee, MF

### Publication Date

2023-06-07

### Copyright Information

This work is made available under the terms of a Creative Commons Attribution License, available at <https://creativecommons.org/licenses/by/4.0/>

Peer reviewed

Issue Date: November 2009, Posted On: 11/1/2009

## **Complications of hydroxyapatite bone cement reconstruction of retrosigmoid craniotomy: Two cases**

### **Abstract**

Hydroxyapatite bone cement is a versatile material used to reconstruct many types of bony surgical defects, and its applications have been widely reported in the literature. Still, complications of its use do occur. We describe 2 cases of hydroxyapatite resorption and subsequent seroma formation in patients who had undergone retrosigmoid craniotomy. The presentation in both cases mimicked a CSF leak. In both cases, the fragmented cement was removed, and the patient experienced no further complications. While hydroxyapatite cement is a highly useful product for the reconstruction of some craniofacial or skull base defects, we believe that it should not be used for the reconstruction of retrosigmoid/suboccipital craniotomies because it is associated with unacceptably high complication rates. Surgeons must exercise caution in selecting candidates for hydroxyapatite reconstruction of cranial defects.

by Aaron G. Benson, MD and Hamid R. Djalilian, MD

### **Introduction**

Hydroxyapatite bone cement is commonly used for craniotomy defect reconstruction following resection of vestibular schwannomas, craniofacial skeleton reconstruction, frontal sinus obliteration, cerebrospinal fluid (CSF) leak repair, and reconstruction of skull base defects.<sup>1-4</sup>

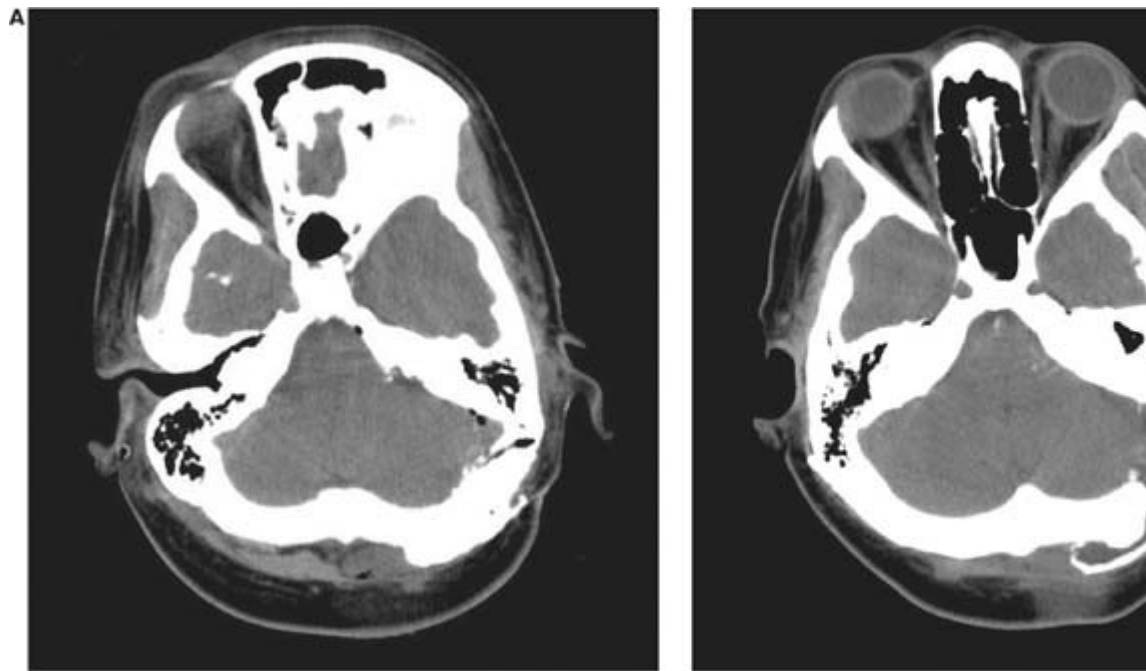
The use of alloplastic materials for the reconstruction of skull base defects has been promoted widely in the literature, but not as much attention has been paid to the complications resulting from the use of these materials. We describe the cases of 2 patients who developed complications after their retrosigmoid craniotomy was reconstructed with BoneSource (Stryker Leibinger GMBH; Freiburg, Germany), one of several commercially available brands of hydroxyapatite cement.

### **Case reports**

**Patient 1.** A 41-year-old woman was administered stereotactic radiation therapy for the treatment of a 1.8-cm left-sided vestibular schwannoma. One year later, follow-up magnetic resonance imaging (MRI) demonstrated evidence of tumor growth to 2.2 cm, and 4 months after that, she underwent a retrosigmoid craniotomy for resection of the tumor. The dura

was closed in a watertight fashion and covered with a collagen matrix (DuraGen; Integra LifeSciences; Plainsboro, N.J.). Autologous fibrin glue was used to secondarily seal the dura. No leakage of CSF was observed after the Valsalva maneuver was carried out to 35 cm H<sub>2</sub>O. After the fibrin glue had solidified, the bony contour was restored with BoneSource. Immediate postoperative computed tomography (CT) showed the hydroxyapatite reconstruction to be intact (figure 1, A).

**Figure 1. Patient 1. A: Axial noncontrast CT immediately following surgery shows that the hydroxyapatite reconstruction of the left retrosigmoid craniotomy is intact. B: Three weeks postoperatively, CT shows the partial destruction of the hydroxyapatite cement**



Two weeks postoperatively, the patient was found to have no evidence of CSF leakage and no seroma or hematoma of the wound site. However, at 3 weeks postoperatively, she presented with a subcutaneous fluid collection in the area of the wound. CT of the head showed some mild dilation of the ventricles and breakdown of the hydroxyapatite cement (figure 1, B). Aspiration obtained 60 ml of straw-colored fluid.

At 1 month postoperatively, the patient was again found to have a reaccumulation of the fluid. Given the dilated ventricles and the subcutaneous fluid collection, it was thought that she had developed a communicating hydrocephalus with CSF leakage. She then had a ventriculoperitoneal shunt placed by the neurosurgery service. However,

she again developed a reaccumulation of the subcutaneous fluid. It was then assumed that the ventriculoperitoneal shunt had malfunctioned, so the patient underwent a revision of the shunt procedure and placement of a programmable shunt. But once again, the fluid reaccumulated. Aspiration again obtained a clear straw-colored fluid. Through the same needle, 6 ml of fibrin glue was introduced into the cavity, and a tight mastoid dressing was applied. After 5 days of dressing application, the subcutaneous fluid again gradually reaccumulated. Finally, an aspirate of the fluid was sent to the laboratory for analysis and culture. No beta-2-transferrin was found, and aerobic and anaerobic bacterial cultures showed no growth.

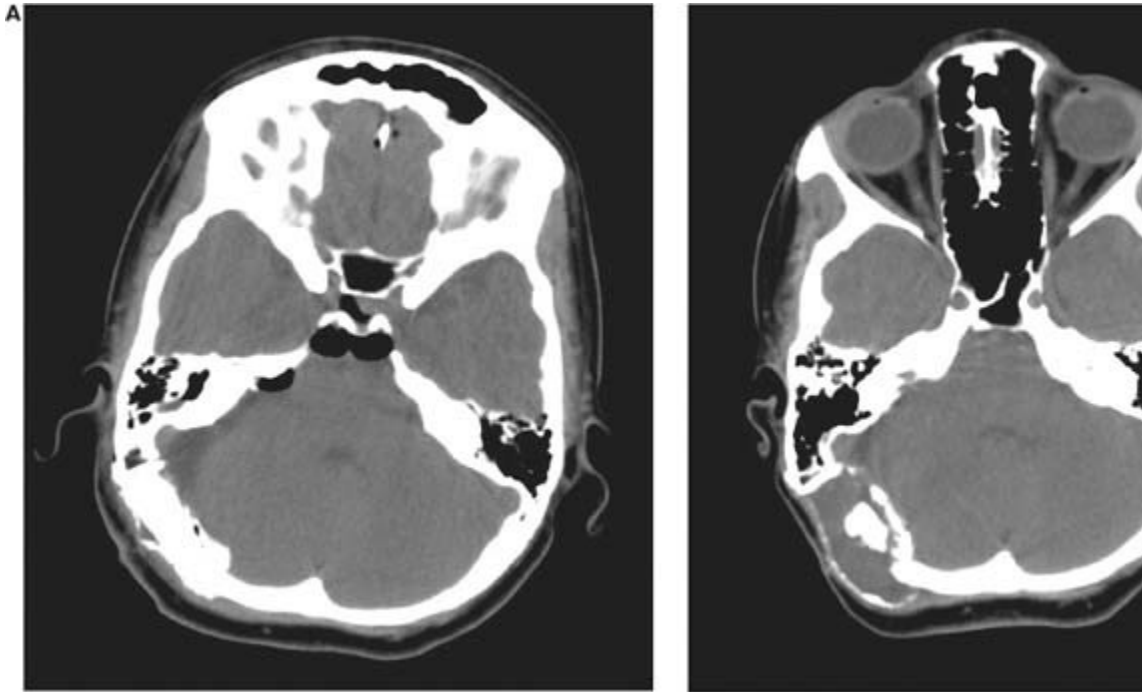
A re-exploration of the wound was performed, and all the hydroxyapatite bone cement was removed. The surrounding tissues were inflamed, and some granulation tissue was present. The hydroxyapatite cement was found to have fragmented into small pieces that were floating in the fluid surrounding it. The underlying dura was intact, and after the Valsalva maneuver was applied to 35 cm H<sub>2</sub>O, no CSF leakage was observed. The dura was not covered further, and the wound was closed. No mastoid or head dressing was applied.

After removal of the hydroxyapatite cement, no reaccumulation of the subcutaneous fluid occurred, and the patient had no complaints of headache at the 2-year follow-up.

**Patient 2.** A 26-year-old woman underwent a right retrosigmoid resection to remove a 2.4-cm vestibular schwannoma. Intraoperatively, a small air cell was found in the internal auditory canal. At the end of the operation, the air cell was packed with muscle. Wound closure and cranioplasty with BoneSource were carried out in the same manner used for patient 1.

The patient's postoperative course was complicated by a delayed CSF rhinorrhea, which developed 2 weeks postoperatively. The source of this leak was determined to be a separate, nearby air cell that had been not been packed during the initial operation. The craniotomy was reopened, the area of the leak was sealed with bone wax, and the craniotomy site was again closed in the same fashion as the initial closure. An immediate CT showed that the hydroxyapatite cement reconstruction was intact (figure 2, A). Two weeks later, the wound's appearance was normal and no evidence of CSF leakage or subcutaneous fluid collection was noted.

**Figure 2. Patient 2. A: Immediately following surgery, axial noncontrast CT shows that the hydroxyapatite cement reconstruction of the right retrosigmoid craniotomy is intact. B: One month after the second operation, CT shows the partial breakdown of the hydroxyapatite**



One month after the second operation, the patient returned to the clinic with fluctuance in the area of the retrosigmoid incision. CT detected an apparent breakdown of the hydroxyapatite cement and a collection of fluid within the cement (figure 2, B). The outer border of the hydroxyapatite reconstruction appeared to be pushed out and thinned. Aspiration yielded 70 ml of straw-colored fluid from the subcutaneous tissues. Afterward, a tight dressing was applied for 7 days.

Three weeks after removal of the dressing, the patient returned again with a fluid collection in the wound area. In view of the CSF leakage after the resection, it was assumed that the patient had another CSF leakage through the dural closure. The patient was taken to the operating room, and the fluid was aspirated and sent to the laboratory for beta-2-transferrin and bacterial culture analysis. The wound was reopened and the hydroxyapatite cement, which had completely disintegrated, was removed. The overlying tissues showed signs of inflammation with minimal granulation in the tissue that was in contact with the hydroxyapatite cement. The dural closure was found to be intact, and no CSF leakage was observed during performance of the Valsalva maneuver to 35 cm H<sub>2</sub>O. The wound was closed, and no subsequent fluid collection occurred. Analysis of the aspirated fluid revealed no beta-2-transferrin, and bacterial and fungal cultures were both negative.

At 2 years, no evidence of recurrent fluid collection or CSF leakage was reported.

## Discussion

Hydroxyapatite bone cement was approved by the U.S. Food and Drug Administration in 1996. Since then it has become something of a reconstruction panacea, and it has been advocated for a wide range of uses, including reconstruction of bony defects in the skull.<sup>1-4</sup> Still, complications do occur. Although BoneSource was the particular brand used in our 2 patients, complications have been reported with other brands, as well.

Kveton et al reported the use of hydroxyapatite cement in the reconstruction of skull base cavities in 42 patients, including 8 who had undergone a suboccipital craniotomy.<sup>3</sup> Of these 8 patients, a complete resorption of the hydroxyapatite cement occurred in 3 (37.5%) and a partial resorption occurred in 3 others.

In a more recent series, Kveton and Coelho reported that 2 of 16 patients (12.5%) who underwent reconstruction of retrosigmoid craniotomy defects experienced a complete resorption of hydroxyapatite cement.<sup>4</sup>

Matic and Phillips reported 3 cases of complications associated with hydroxyapatite cement reconstruction following craniofacial surgery in children.<sup>5</sup> All 3 of these patients experienced late inflammation of the operative site and delamination of the hydroxyapatite. Histopathology showed evidence of a foreign-body inflammatory reaction. The authors theorized that an inflammatory process caused an increase in local blood flow, which in turn initiated resorption of the hydroxyapatite cement. They postulated that the loose cement fragments further stimulated the inflammatory process and led to the foreign-body reaction that was seen on histopathologic examination.

Moreira-Gonzalez et al studied 449 cranioplasty procedures and found that hydroxyapatite cement was associated with a significantly higher incidence of complications compared with polymethylmethacrylate and autologous bone grafts.<sup>6</sup> Upon surgical exploration of the areas of the hydroxyapatite cement breakdown, the authors found fluid collection, fragmentation of the material, and a tissue reaction similar to what we found in our 2 patients. Histopathologic examination of the areas of hydroxyapatite breakdown revealed the presence of neutrophils, lymphocytes, fibroblasts, and a large number of plasma cells, which indicated an immune reaction. Equal rates of complications were observed with BoneSource and Mimix (W. Lorenz Surgical; Jacksonville, Fla.), another brand of hydroxyapatite cement.

We believe that the partial resorption and breakdown of the hydroxyapatite cement in our 2 patients might have been attributable to an initial inflammatory process. Kveton and Coelho speculated that the breakdown of hydroxyapatite occurs as a reaction to seroma leakage.<sup>4</sup> In both of our patients, the seroma was not present 2 weeks postoperatively. The delayed nature of the hydroxyapatite breakdown and the large amount of fluid collection support the idea of an inflammatory reaction. The fluid accumulation resolved in both patients once the hydroxyapatite cement was

removed.

In conclusion, hydroxyapatite cement is a highly useful product for the reconstruction of some craniofacial or skull base defects. However, surgeons must exercise caution in selecting candidates for hydroxyapatite reconstruction. Like Ridenour et al,<sup>7</sup> we believe that the complication rate is unacceptably high when hydroxyapatite is used to reconstruct a large defect such as a retrosigmoid/suboccipital craniotomy. When reviewing the risks and benefits of retrosigmoid/suboccipital craniotomies with patients, the complications associated with alloplastic reconstruction materials must be included in the discussion. It is interesting that over a 24-month period, we performed reconstruction of suboccipital craniotomy defects in a series of 25 patients using materials other than hydroxyapatite cement, and we observed no complications (unpublished data).

Finally, some authors have advocated using a drain to prevent the resorption of hydroxyapatite cement when it is used to reconstruct suboccipital craniotomies.<sup>4</sup> But the presence of a postoperative drain can create a route for bacteria to enter the surgical site and infect the alloplastic material and possibly the meninges. Since there are several other alloplastic alternatives that can be used without the need for a drain, it seems counterintuitive to use hydroxyapatite in these particular cases.

From the Department of Otolaryngology-Head and Neck Surgery, University of Illinois at Chicago (Dr. Benson), and the Department of Otolaryngology-Head and Neck Surgery (HRD), University of California Irvine Medical Center, Orange, Calif. (Dr. Djalilian).

Hamid R. Djalilian, MD, Department of Otolaryngology-Head and Neck Surgery, University of California Irvine Medical Center, Bldg. 56, 101 The City Drive S., Orange, CA 92868. E-mail: [skullbasesurgery@yahoo.com](mailto:skullbasesurgery@yahoo.com)

## References

1. Costantino PD, Friedman CD, Jones K, et al. Hydroxyapatite cement. I. Basic chemistry and histologic properties. *Arch Otolaryngol Head Neck Surg* 1991; 117 (4): 379-84.
2. Kveton JF, Friedman CD, Costantino PD. Indications for hydroxyapatite cement reconstruction in lateral skull base surgery. *Am J Otol* 1995; 16 (4): 465-9
3. Kveton JF, Friedman CD, Piepmeier JM, Costantino PD. Reconstruction of suboccipital craniectomy defects with hydroxyapatite cement: A preliminary report. *Laryngoscope* 1995; 105 (2): 156-9.
4. Kveton JF, Coelho DH. Hydroxyapatite cement in temporal bone surgery: A 10 year experience. *Laryngoscope* 2004; 114 (1): 33-7.
5. Matic D, Phillips JH. A contraindication for the use of hydroxyapatite cement in the pediatric population. *Plast Reconstr Surg* 2002; 110 (1): 1-5.

6. Moreira-Gonzalez A, Jackson IT, Miyawaki T, et al. Clinical outcome in cranioplasty: Critical review in long-term follow-up. *J Craniofac Surg* 2003; 14 (2): 144-53.
7. Ridenour JS, Poe DS, Roberson DW. Complications with hydroxyapatite cement in mastoid cavity obliteration. *Otolaryngol Head Neck Surg* 2008; 139 (5): 641-5.

Ear Nose Throat J. 2009 November;88(11):E1