

UC Davis

Dermatology Online Journal

Title

Elastolytic giant cell granuloma: clinic-pathologic review of twenty cases

Permalink

<https://escholarship.org/uc/item/80q2b8gb>

Journal

Dermatology Online Journal, 19(10)

Authors

Gutierrez-Gonzalez, Enrique
Gomez-Bernal, Silvia
Alvarez-Perez, Adriana
et al.

Publication Date

2013

DOI

10.5070/D31910020019

Copyright Information

Copyright 2013 by the author(s). This work is made available under the terms of a Creative Commons Attribution-NonCommercial-NoDerivatives License, available at <https://creativecommons.org/licenses/by-nc-nd/4.0/>

Peer reviewed

Case Report

Elastolytic giant cell granuloma: clinic-pathologic review of twenty cases

Enrique Gutierrez-Gonzalez MD, Silvia Gomez-Bernal MD, Adriana Alvarez-Perez MD, Dolores Sanchez-Aguilar PhD, Jaime Toribio PhD

Dermatology Online Journal 19 (10): 3

Department of Dermatology, Complejo Hospitalario Universitario. Faculty of Medicine. Santiago de Compostela, La Coruna, Spain

Correspondence:

Enrique Gutierrez-Gonzalez, MD
Department of Dermatology, Complejo Hospitalario Universitario
Faculty of Medicine, Santiago de Compostela

ABSTRACT

Background: O'Brien described four histopathological patterns of actinic granuloma (AG). Since then, only single cases and a few series have been reported in the literature, most corresponding to cases of the giant cell type.

Methods: We reviewed all the cases diagnosed as AG or elastolytic giant cell granuloma (EGCG) in our department from 1988 until 2010. The biopsies were classified into the four patterns previously described.

Results: Giant cell pattern was found to be the most frequent (70% of the cases). In four cases, the biopsies showed more than one histopathologic pattern. All the lesions were located on sun-exposed areas or were related to chronic heat exposure. Diabetes mellitus was associated in 40 % of the cases.

Conclusions: The giant cell pattern of EGCG is the most frequent. Some cases may share histopathologic features of more than one variant and thus, we consider they may be categorized as mixed patterns. Diabetes mellitus is the most common associated disease and should always be ruled out.

Key words: Actinic granuloma, elastolytic giant cell granuloma, elastophagocytosis, elastosis, diabetes mellitus.

INTRODUCTION

O'Brien first introduced the term actinic granuloma (AG) in 1975 [1]. It referred to annular or ring-shaped skin lesions, which appear on photoexposed areas that particularly involve the face, neck, upper extremities, and upper part of the trunk. The biopsies of AG/elastolytic giant cell granuloma (EGCG) typically show a prominent infiltrate of foreign-body giant cells that display *elastophagocytosis* – giant cells phagocytizing basophilic elastic fibers. Ten years after the initial description, O'Brien described three new histopathological variants of AG (vascular or necrobiotic, histiocytic and sarcoid) that were less frequent than the classic giant cell pattern [2].

MATERIALS AND METHODS

We reviewed all the cases diagnosed as AG or EGCG in our department from 1988 until 2010. Twenty patients with a total number of 25 biopsies were included. All these patients had clinical and laboratory data available for review and the biopsy specimens fulfilled the histopathologic criteria previously defined [2]. An individual examination of the biopsies of each case as well as the clinical records of the patients was conducted. All the biopsies were examined by two of us (JT, EGG).

For tissue management, we used the standard fixation process with 10% neutral buffered formaldehyde. Afterwards, the pieces were embedded in paraffin and cut in sections of 3-4 µm. Besides the routine hematoxylin-eosin (H-E) stain, an orcein stain was also done in every case.

RESULTS

The mean age at the time of diagnosis was 58 years, with an age range of 32-78 years. However, 90% of the cases were over 50 years. Women represented 55% of the cases (11/20) (Table 1).

Table 1. Clinical data of the patients included in the series.

Patient	Variant	Sex	Age	Local.	Time	Number	Clinical diagnosis	Comorbidities	Symptoms.	N. biop
1	GC	F	61	LE	5 months	2	AG	HyperCa.	No	1
2	GC	M	52	Hands	1 year	Several	GA/AG LPA	AH/DM DLP	No	1
3	NB-SRC	M	59	Forearms	20 years	Several	SRD/AG	DM/AH	No	2
4	HIS	M	66	Hands	3 years	1	AG/GA	DM	No	1
5	GC	M	67	Neck	6 months	1	GA/LPA	DLP/BPH	Pruritus	1
6	GC-NB	F	55	Forearm	2 years	1	GA	DM	No	1
7	GC	F	52	Neck	3 months	2	AG	Anxiety	Pruritus	1
8	GC	M	54	Hands	6 months	2	GA	DLP psoriasis	No	1
9	NB	F	59	Hands LE	2 years	Several	GA AG	DM	No	1
10	GC-NB	F	66	Hands	1 year	1	GA	DM DLP	No	1
11	GC	F	78	Forearms LE	2 years	Several	GA	No	No	1
12	NB	M	32	LE	16 years	1	NBS	No	No	1
13	NB	F	51	LE	1 year	Several	AG NBS	DM	Pruritus	3
14	HIS	M	75	Hand	1 year	1	AG	AH BPH	No	1
15	GC	M	54	Hands	4 years	Several	AG	AH	No	1
16	GC	M	67	Hands Forearms	6 years	Several	AG	No	Pruritus	1
17	GC	F	57	LE	3 years	Several	NBS	No	No	1
18	GC	F	53	Neck	4 years	1	AG	No	No	1
19	GC	F	60	Hands	1 year	Several	GA	DM	Pruritus	2
20	GC-NB	F	49	Hands	1 year	Several	GA	Hepat.	Pruritus	2

Local=localization; N. biop= number of biopsies; GC=giant cell; NB=necrobiotic; SRC= sarcoid; HIS=histiocytic; M= Male; F= female; LE= lower extremities; AG=actinic granuloma; GA: granuloma annulare; NBS=necrobiosis; LPA: lichen planus annularis; SRD= sarcoidosis; DM=Diabetes mellitus; AH; arterial hypertension; DLP= dyslipidemia; HyperCa= hypercalcemia; Hepat=hepatopathy; BPH= benign prostatic hiperplasia.

The time interval between the onset of the lesions and the biopsy varied between 1 month and 20 years, but in 65% of the cases it was less than 1 year and in 80% less than 2 years. Clinically, most of the patients presented with annular plaques, with erythematous border and central clearing. Some of them demonstrated slight atrophy (Figure 1). Only 30% of the patients complained of pruritus or burning sensation.

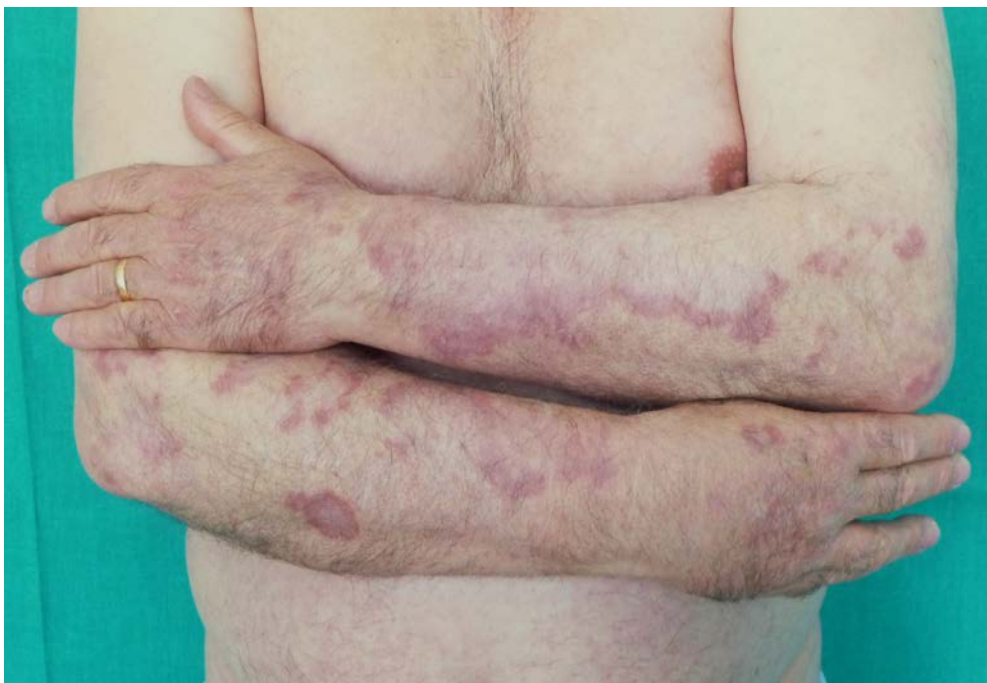

Figure 1. Annular plaques with erythematous border and central clearing on the dorsal aspect of the forearms and hands.

The most common location of the lesions was the dorsum of the hands (50%), followed by the lower extremities (30%). Other common sites were the forearms (20%) and the neck (15%). In four patients (20%), the lesions appeared in more than one location. No mucosal or ocular involvement was observed in any patient. We found that 13 of the 20 patients (65%) showed two or more lesions, whereas 35% presented with a single lesion at the time of diagnosis.

The most frequent associated condition was diabetes mellitus (DM), appearing in 8 of the patients (40%). In 20% of the cases arterial hypertension and dyslipidemia were significant in the medical history, respectively. None of the cases showed systemic signs of sarcoidosis.

All the biopsies were sent by dermatologists. The most frequent clinical diagnosis was AG/EGCG (50%), followed by granuloma annulare (GA). Other diagnoses were necrobiosis lipoidica, sarcoidosis, or annular lichen planus.

The biopsies were reviewed and classified into the four patterns previously described [2]. In 80% of the cases histopathologic findings could be classified into one of the variants. The most frequent was the giant cell pattern, found in 14 patients (70%)(Figure 2). It consisted of an interstitial granulomatous infiltrate, located in the mid dermis, mainly constituted by foreign body giant cells. Some of the giant cells had elastotic fibers inside, proceeding to the phagocytosis and elimination of these damaged fibers. This was also accompanied by a superficial perivascular infiltrate of lymphocytes and histiocytes. In the adjacent zone to the granuloma, there were many broken elastic fibers. The necrobiotic or vascular pattern was found in 7 of the cases (35%)(Figure 3). One of the more relevant findings in this group was the presence of foci of necrobiosis located in the upper reticular dermis, with a variable number of giant cells around them. In some of the cases, and not exclusively in this pattern, the actinic damage (damaged elastic fibers and elastosis) could also be seen in the fibers of the elastic layer of the vessels in deep dermis. This finding was easily seen with the orcein stain. The histiocytic variant was present in 2 patients (10%) (Figure 4), consisting of a dense inflammatory infiltrate mainly constituted by histiocytes and scarce giant cells, in a dermis with a high grade of solar elastosis. The sarcoidal pattern was only found in one patient (5%) (Figure 5). In this case the infiltrates adopted the aspect of sarcoidal granulomas, with the presence of a lymphocytic halo. Occasionally a giant cell could be seen, with the phenomenon of phagocytosis. With the orcein stain, an absence or reduction of elastic fibers in the residual zone could be seen in all the variants.

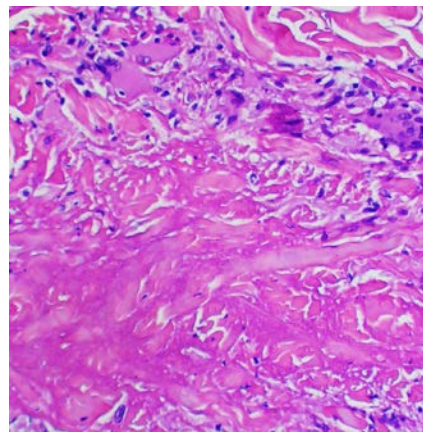
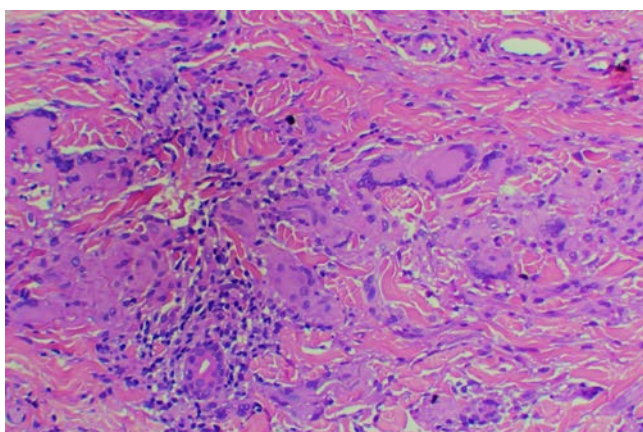


Figure 2. Foreign body giant cell infiltrate in the mid-dermis (Hematoxylin and eosin, original magnification x 100).

Figure 3. Focus of necrobiosis surrounded by a lympho-histiocytic infiltrate. (Hematoxylin and eosin, original magnification x 100).

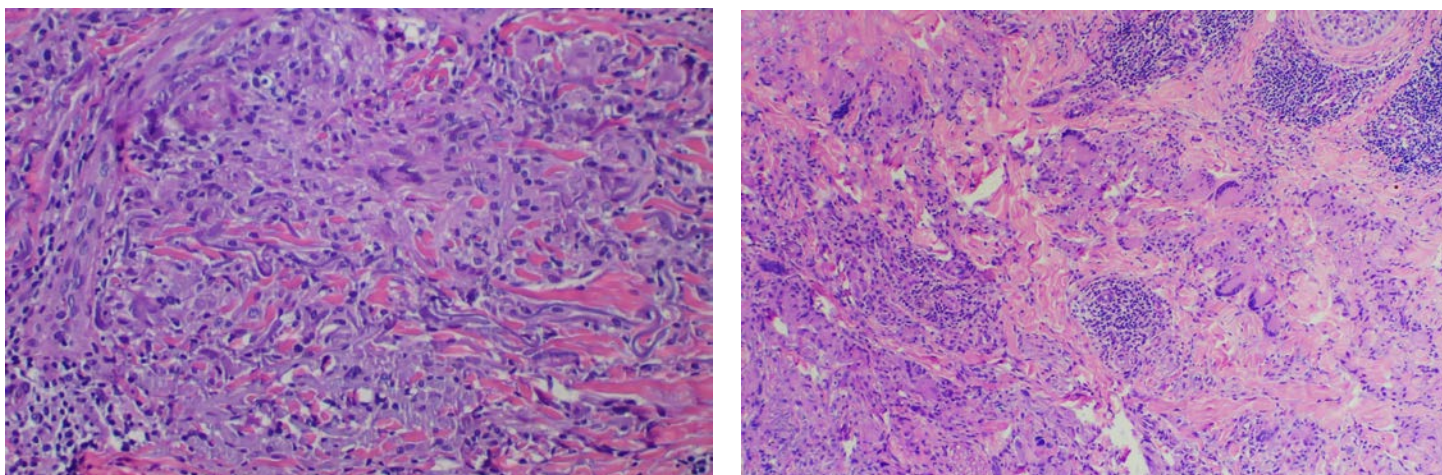


Figure 4. Intense histiocytic infiltrate scattered among the elastotic fibers. (Hematoxylin and eosin, original magnification x 100).

Figure 5. Giant cells and sarcoid-appearing infiltrates in mid dermis (Hematoxylin and eosin, original magnification x 40)

However, four cases presented two different patterns on the biopsy specimens, without prevalence of one of either. Among these cases with mixed patterns, three of them showed characteristics of the giant cell and the necrobiotic pattern. The other one had findings of the sarcoid and necrobiotic variant. Seventy per cent of the patients with the necrobiotic pattern had diabetes mellitus. However, considering the patients of the giant cell group, only 35% suffered from diabetes (Table 2).

Table 2. Correlation between the different histopathologic patterns with sex, age and presence of diabetes mellitus.

Pattern	Age: Range (Mean)	Sex (M/F)	DM	Total
GC	49-78 (58,9)	5/9	5	14
NB	32-66 (53)	2/5	5	7
HIS	66-75 (70,5)	2/0	1	2
SRC	59 (59)	1/0	1	1
Total Cases	32-78 (58)	9/11	8/20	20

M= male F=Female DM= Diabetes mellitus

GC=giant cell NB=necrobiotic HIS=Histiocytic SRC=sarcoid

DISCUSSION

AG, as initially described by O'Brien [1], is a condition that usually begins as small skin-colored or pink papules that progressively evolve into annular plaques. The border of the lesion extends slowly at the periphery while the center returns to a normal or slightly atrophic appearance. The lesions are usually asymptomatic and can last for years until spontaneous resolution occurs. The mean age of the patients is between 30 and 40 years and the condition affects men and women equally [1].

The most characteristic histopathological finding is an infiltrate of foreign-body giant cells, which phagocytize the degenerated elastic fibers (Figure 6). O'Brien postulated that actinic-damaged elastic fibers are the antigenic stimuli that trigger the inflammatory process. He considered this condition a means of reparation of sun and heat-damaged connective tissue [1,2].

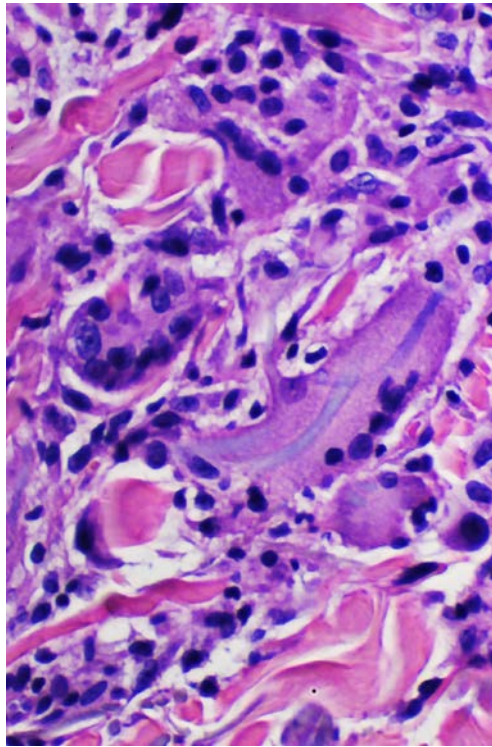


Figure 6. Giant cell phagocytizing an elastotic fiber. (Hematoxylin and eosin, original magnification x 200)

When the biopsy is performed appropriately, three different zones can be seen: a) the normal appearing skin located around the ring where actinic elastosis can be observed; b) the erythematous raised border with an infiltrate of histiocytes and giant cells; c) the central zone characterized by a scant number or absence of elastic fibers [1].

The skin surrounding the lesions often shows degeneration of the connective tissue, actinic elastosis or solar elastosis. In the upper dermis, although sometimes it may be found deeper, these elastic fibers appear thickened, curved, and clustered. In hematoxylin and eosin preparations these elastotic fibers appear as a purple-bluish color, whereas in the normal skin they appear red. Owing to these changes, this has been named basophilic degeneration of the dermis.

In 1978, Toribio et al. reported new cases of this entity [3]. One year later, Hanke et al. suggested the term giant cell elastolytic granuloma (EGCG). For these authors, the concurrence of solar elastosis and the granuloma does not imply a cause-effect relationship. Hanke admitted the elastolysis but not its actinic etiology. He also included under this concept other entities like Miescher's granuloma or atypical necrobiosis of the face [4]. This same year, Ragaz and Ackerman rejected AG as a specific entity and asserted that AG is a form of GA on sun-exposed areas [5].

O'Brien also theorized on the fact that solar elastosis does not affect only the elastic fibers of the skin, but also can affect the internal elastic lamina of the arterioles of the skin and subcutaneous tissue. He designated these changes as actinic arteriopathy, with subsequent ischemia [2]. More recently, O'Brien and Regan highlighted the importance of solar elastosis in AG, but also in other diseases such as giant cell arteritis or temporal arteritis [6].

Currently, the concept introduced by Hanke is almost universally accepted and many authors recognize AG/EGCG as a unique entity, different from GA [7,8]. Generally, it is accepted that AG is a variant, the best known, of EGCG [9,10,11] and we also share this opinion. Afterwards, several authors have confirmed the existence of this entity and published similar cases in photoexposed areas, [3,8,12] but also on areas not exposed to sunlight [9,13,14].

Most of the patients in our series admitted to having received intense and frequent solar exposure because of their jobs. In one of the cases the cause was attributed to chronic heat damage owing to repeated burns on the skin [10]. In the literature, chronic actinic damage, and in some cases excessive acute sun exposure, are described as the main etiologic factor [1,5-7,12]. Cases of AG related to drug phototoxicity have also been reported [15]. It has been postulated that UVA radiation, because of its longer wavelength and deeper penetration, is responsible for these changes [12]. However, it has not been possible to reproduce AG by phototesting [16].

In our series there is a similar proportion of men and women, with a ratio of 1.2:1. In previously published series it varies between 1.2: 1 [1,5] and 1.5:1 [7]. The age range is variable, mainly between 40 and 70 years of age. In our series, the youngest patient was 32 years old and the oldest was 78, but 85% were between 50 and 70 years old, similar to other series [5,7]. The youngest patient reported in the literature was an 8-month baby and the oldest an 83 year-old woman [17,18].

We found a high association of DM with EGCG, appearing in 40% of the cases. Limas, in a series of 20 patients, also noted this association, but found a lower percentage (20%) [7]. A similar percentage to ours has also been reported [3,19]. We consider that it may be a real association, owing to a higher prevalence than expected in the general population [20].

The percentage of patients in our series with DM was higher in the necrobiotic pattern compared with the giant cell group. This may be explained by the fact that the damage to small vessels (microangiopathy) related to the hyperglycemia, together with the actinic damage of the vessels, may contribute to the ischemia of connective tissue and the appearance of foci of necrobiosis [2,6]. It may be difficult to distinguish between necrobiosis lipoidica and the necrobiotic variant of AG. Both entities appear more often in diabetic patients and histopathologically they can also resemble each other. The presence of giant cells and the absence of elastic fibers in and around the foci of necrobiosis can favor the diagnosis of the necrobiotic variant of AG.

Arterial hypertension was observed in 20% of the patients. We have considered it not to be of significance owing to the similar prevalence in the general population [21]. One of the cases in our series suffered from alcoholic hepatopathy. There is a similar case in the literature, but the role of this disease in the etiology of EGCG remains unclear [19]. There have also been reported cases of EGCG associated with leukemias and lymphomas, usually following a parallel course to the disease [22,23].

Seven of the twenty patients in our series (35%) consulted with a dermatologist more than one year after the appearance of the first lesions, which highlights the slow growth of the lesions and the usual lack of symptoms, as has been found in other series [7]. Clinically, the lesions often appear as annular plaques with peripheral spreading and central clearing. However, cases with papular lesions exclusively that have been interpreted as very early forms have also been reported [9,13,24].

We classified our cases into the four patterns described by O'Brien [2]. The most frequent pattern was the giant cell one, in 70% of the cases. This percentage is higher than in the O'Brien study (50%). The necrobiotic pattern was found in 35% of the cases, a similar proportion to the O'Brien series (27%). The histiocytic pattern represented 10% of the cases (the same as in O'Brien's) and the sarcoidal pattern was only found in one patient (5%). These differences found between our series and O'Brien's may be explained by the smaller number of cases in our series and because we considered some cases to be mixed patterns.

Some authors believe that AG is a variant of GA on sun-exposed areas [4,25]. Al-Hoqail et al. reviewed cases of AG and compared it with cases of GA, concluding that these are different entities that can easily be distinguished by histopathologic study. They found several characteristics that help to differentiate both diseases: the presence of giant cells, the absence of mucin deposition, the involvement of the superficial dermis, elastophagocytosis and the absence of elastic fibers as well as the formation of sarcoidal or interstitial granulomas in the absence of palisading. The presence of one or more of these factors favors the diagnosis of AG and permits it to be distinguished from GA [8].

Many hypotheses about the pathogenesis of EGCG have been proposed, but none of them has been universally approved. In the particular case of AG, O'Brien's theory of actinic damage and solar elastosis is still accepted [2]. Some authors have reported cases of EGCG on non photoexposed areas or in a generalized fashion, which supports the idea that solar elastosis is not a "sine qua non" condition for the diagnosis [9,13,14].

A case of a generalized EGCG limited to the zone of a previous burn that had no elastic fibers has been reported. This case adds further evidence to the idea that the inflammatory response is targeted to these fibers and in the absence of elastic fibers this process is not possible [26]. A case with extracutaneous involvement, including the lymphatic and digestive systems, suggested that EGCG and sarcoidosis may be related entities [27]. In the same way, it has been postulated that an individual predisposition to an immunological response against damaged elastic fibers may exist [7].

Elastophagocytosis and elastolysis are not pathognomonic for EGCG and may be found in other diseases such as leprosy and mid-dermal elastolysis, respectively. It has been suggested that both are the final result of different immune-mediated processes [7,9]. Some authors, like Müller et al. have also proposed that EGCG may precede mid-dermal elastolysis [28].

EGCG has a chronic course, sometimes resolving spontaneously. Many treatments have been tried but none of them has proven to be more effective than the others. Among these treatments are topical, intralesional and systemic corticosteroids [3,10,28], chloroquine [14,26,29], hydroxychloroquine [18], tranilast, topical pimecrolimus [16], cyclosporine [30], and UVB and UVA sunscreens [18]. Recently, the use of fumaric acid esters have been reported to be effective, with few adverse effects [31,32].

In conclusion, we believe that the term AG refers to a specific etiology, whereas the term EGCG seems to be more correct, because it includes also those cases which fulfill the histopathologic criteria but are not related to actinic damage. The giant cell variant is the most frequent variant of EGCG. The finding of giant cells in the granulomatous area and the absence of elastic fibers in the residual zone are features that can help to distinguish the different variants of EGCG from other entities that may exhibit similar histopathological characteristics. As we have described, some cases may show histopathologic

features of more than one variant and should be considered as mixed patterns. Diabetes mellitus is commonly associated with this entity and thus it should be always be looked for in patients with EGCG.

REFERENCES

1. O'Brien JP. Actinic granuloma. An annular connective tissue disorder affecting sun and heat damaged (elastotic) skin. *Arch Dermatol* 1975 Apr; 111(4): 460-466. [PMID:1122146]
2. O'Brien JP. Actinic granuloma: the expanding significance. An analysis of its origin in elastotic ("aging") skin and a definition of necrobiotic (vascular), histiocytic and sarcoid variants. *Int J Dermatol* 1985 Oct; 24(8): 473-490. [PMID:2415473]
3. Toribio J, Quiñones PA, Pérez-Oliva N. Granuloma actínico. *Actas Dermosifiliogr* 1978 Sep-Oct; 69(9-10):289-294. [PMID:742453]
4. Hanke CW, Bailin PL, Roenigk HH. Annular elastolytic giant cell granuloma. A clinicopathologic study of five cases and a review of similar entities. *J Am Acad Dermatol* 1979 Nov; 1(5): 413-421. [PMID:512085]
5. Ragaz A, Ackerman AB. Is actinic granuloma a specific condition? *Am J Dermatopathol* 1979 Spring; 1(1): 43-50. [PMID:398673]
6. O'Brien JP, Regan W. Actinically degenerated elastic tissue is the likely antigenic basis of actinic granuloma of the skin and of temporal arteritis. *J Am Acad Dermatol* 1999 Feb; 40 (2 Pt 1): 214-222. [PMID:10025748]
7. Limas C. The spectrum of primary cutaneous elastolytic granulomas and their distinction from granuloma annulare: a clinicopathological analysis. *Histopathology* 2004 Mar; 44(3): 277-282. [PMID:14987232]
8. Al-Hoqail IA, Al-Ghamdi AM, Martinka M, Crawford RI. Actinic granuloma is a unique entity. A comparative study with granuloma annulare. *Am J Dermatopathol* 2002 Jun; 24(3):209-212. [PMID:12140436]
9. Pock L, Blazková J, Caloudová H, Varjassyová I, Konkolová R, Hercogová J. Annular elastolytic giant cell granuloma causes an irreversible disappearance of the elastic fibers. *J Eur Acad Dermatol Venereol* 2004 May; 18(3): 365-368. [PMID:15096158]
10. Pestoni C, Pereiro M Jr, Toribio J. Annular elastolytic giant cell granuloma produced on an old burn scar and spreading after a mechanical trauma. *Acta Derm Venereol* 2003; 83(4):312-313. [PMID:12926814]
11. Doulaveri G, Tsagrani E, Giannadaki M et al. Annular elastolytic giant cell granuloma in a 70-year old woman. *Int J Dermatol* 2003 Apr; 42(4): 290-291. [PMID:12694495]
12. Davies MG, Newman P. Actinic granulomata in a young woman following prolonged sunbed usage. *Br J Dermatol* 1997 May; 136(5): 797-798. [PMID:9205526]
13. Campos-Muñoz L, Díaz-Díaz RM, Quesada-Cortés A et al. Granuloma elastolítico anular de células gigantes: a propósito de un caso localizado en áreas no fotoexpuestas. *Actas Dermosifiliogr* 2006 Oct; 97 (8): 533-535. [PMID:17067534]
14. Klemke CD, Siebold D, Dippel E, Hildenbrand R, Bleyl U, Goerdt S. Generalized annular elastolytic giant cell granuloma. *Dermatology* 2003; 207 (4): 420-422. [PMID:14657644]
15. Lim DS, Triscott J. O'Brien's actinic granuloma in association with prolonged doxycycline phototoxicity. *Australas J Dermatol* 2003 Feb; 44(1):67-70. [PMID:12581086]
16. Kiken DA, Shupack JL, Soter NA, Cohen DE. A provocative case: phototesting does not reproduce the lesions of actinic granuloma. *Photodermatol Photoimmunol Photomed* 2002 Dec; 18(6): 315-316. [PMID:12535030]
17. Lee HW, Lee MW, Choi JH, Moon KC, Koh JK. Annular elastolytic giant cell granuloma in an infant: improvement after treatment with oral tranilast and topical pimecrolimus. *J Am Acad Dermatol* 2005 Nov; 53(5 Suppl 1): S244-246. [PMID:16227100]
18. Sina B, Wood C, Rudo K. Generalized elastophagocytic granuloma. *Cutis* 1992 May; 49(5): 355-357. [PMID:1521496]
19. Aso Y, Izaki S, Teraki Y. Annular elastolytic giant cell granuloma associated with diabetes mellitus: a case report and review of the Japanese literature. *Clin Exp Derm* 2011 Dec;36(8):917-919. [PMID:21623881]
20. Wild S, Roglic G, Green A, et al. Global prevalence of diabetes: estimates for the year 2000 and projections for 2030. *Diabetes Care* 2004 May;27(5):1047-53. [PMID:15111519]
21. Pappas G, Gergen PJ, Carroll M. Hypertension prevalence and the status of awareness, treatment, and control in the Hispanic Health and Nutrition Examination Survey (HHANES) 1982-84. *Am J Public Health* 1990 Dec; 80(12):1413-6. [PMID:2240325]
22. Racz I, Berecz M, Harsing J. Actinic granuloma in alcoholic liver disease. *Cutis* 1992 Jun; 49(6): 417-419. [PMID:1628509]
23. Garg A, Kundu RV, Plotkin O, Aronson IK. Annular elastolytic giant cell granuloma heralding onset and recurrence of acute myelogenous leukemia. *Arch Dermatol* 2006 Apr; 142(4): 532-533. [PMID:16618887]
24. Boussault P, Tucker ML, Weschler J et al. Primary cutaneous CD4+ small/medium-sized pleomorphic T-cell lymphoma associated with an annular elastolytic giant cell granuloma. *Br J Dermatol* 2009 May; 160(5): 1126-1128. [PMID:19292715]
25. Fujimura T, Terui T, Tagami H. Disseminated papular interstitial giant cell granuloma. *Acta Derm Venereol* 2003; 83(3): 234-235. [PMID:12816168]
26. Revenga F, Rovira I, Pimentel J, Alejo M. Annular elastolytic giant cell granuloma – actinic granuloma? *Clin Exp Dermatol* 1996 Jan; 21(1): 51-53. [PMID:8689771]
27. Kurose N, Nakagawa H, Iozumi K, Nogita T, Furue M, Ishibashi Y. Systemic elastolytic granulomatosis with cutaneous, ocular, lymph nodal and intestinal involvement. Spectrum of annular elastolytic giant cell granuloma and sarcoidosis. *J Am Acad Dermatol* 1992 Feb; 26 (2 Pt 2): 359-363. [PMID:1569259]

28. Müller FB, Groth W. Annular elastolytic giant cell granuloma: a prodromal stage of mid-dermal elastolysis? *Br J Dermatol* 2007 Jun; 156(6): 1377-1379. [PMID:17459032]
29. Tock CL, Cohen PR. Annular elastolytic giant cell granuloma. *Cutis* 1998 Oct; 62(4): 181-187. [PMID:9798106]
30. Ventura F, Vilarinho C, Duarte ML, Pardal F, Brito C. Two cases of annular elastolytic giant cell granuloma: different response to the treatment. *Dermatol Online J* 2010 Mar; 16 (3): 11. [PMID:20233568]
31. Gutzmer R, Breuer K, Kiehl P, Kapp A, Werfel T. Successful therapy of annular elastolytic giant cell granuloma with fumaric acid esters. *Dermatology* 2002; 205(4): 421-424. [PMID:12444347]
32. Breuer K, Gutzmer R, Volker B, Kapp A, Werfel T. Therapy of noninfectious granulomatous skin diseases with acid fumaric esters. *Br J Dermatol* 2005 Jun; 152(6): 1290-1295. [PMID:15948995]