

# UC Davis

## Dermatology Online Journal

### Title

Skin infection caused by *Scedosporium apiospermum* in immunocompromised patients.  
Report of two cases

### Permalink

<https://escholarship.org/uc/item/8085s7w4>

### Journal

Dermatology Online Journal, 19(10)

### Authors

Valenzuela Salas, I  
Martinez Peinado, C  
Fernandez Miralbell, A  
et al.

### Publication Date

2013

### DOI

10.5070/D31910020022

### Copyright Information

Copyright 2013 by the author(s). This work is made available under the terms of a Creative Commons Attribution-NonCommercial-NoDerivatives License, available at <https://creativecommons.org/licenses/by-nc-nd/4.0/>

Peer reviewed

## Case Report

### Skin infection caused by *Scedosporium apiospermum* in immunocompromised patients. Report of two cases

Valenzuela Salas I.<sup>1</sup>, Martínez Peinado C.<sup>1</sup>, Fernández Miralbell A.<sup>2</sup>, Soto Díaz Agustín.<sup>1</sup>, Nogueras Morillas P.<sup>1</sup>, Martín Castro A.<sup>3</sup>, Tercedor Sánchez J.<sup>1</sup>, García Mellado V.<sup>1</sup>

Dermatology Online Journal 19 (10): 6

Departments of Dermatology<sup>1</sup>, Internal Medicine<sup>2</sup>, and Pathology<sup>3</sup>; Hospital Universitario Virgen de las Nieves, Granada, Spain

#### Correspondence:

Ignacio Valenzuela Salas  
Department of Dermatology  
Hospital Universitario Virgen de las Nieves  
Avenida de las Fuerzas Armadas, 2;  
(18014) Granada, Spain  
ivalensa@gmail.com

## Introduction

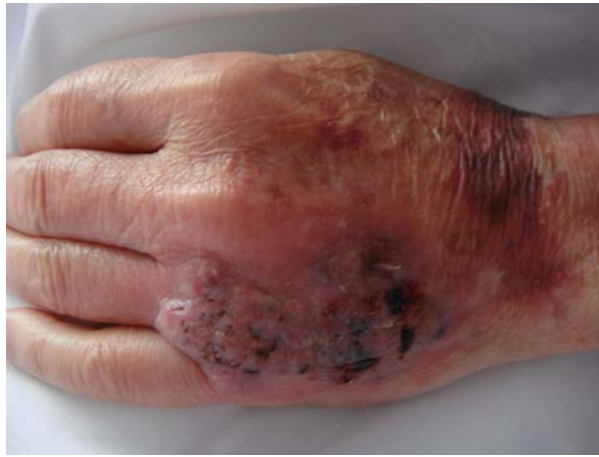*Scedosporium apiospermum* is a filamentous fungus that can cause cutaneous or extracutaneous disease. A large number of cases have been published over the last decades, mainly in patients immunocompromised as a result of their disease or treatment. These kinds of infections can progress rapidly and become disseminated, leading to very serious or even fatal complications. We report two new cases of skin infection by *Scedosporium apiospermum* from our hospital.

**Keywords:** *Scedosporium apiospermum*, skin infection, micoses, immunocompromised

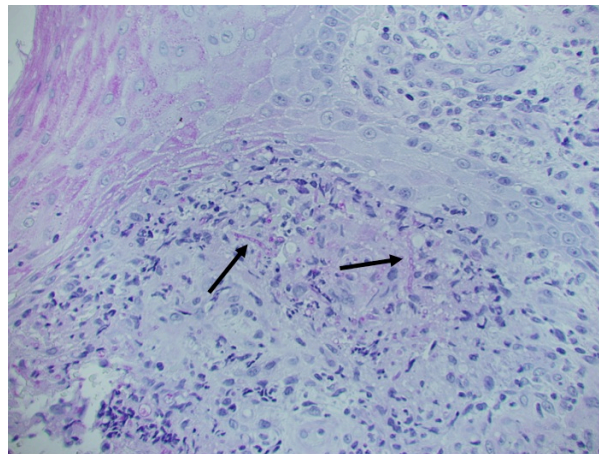
## Case n°1

A 68-year-old male underwent liver transplantation one year earlier for cryptogenic hepatic cirrhosis and diabetes mellitus type 2. His medications include deflazacort, mycophenolate mofetil, tacrolimus, cotrimoxazole, insulin, iron, and omeprazole. Two months earlier he developed a painful, raised plaque on an area of injury in the back of his left hand. A skin biopsy at this time showed epidermal hyperplasia and chronic inflammation. No organisms were seen with PAS, Giemsa, and Ziehl Neelsen staining. *Enterococcus faecalis*, cultured from lesional exudate was considered to be a contaminant. During the following days, the patient's condition deteriorated, with fatigue and difficult ambulation. On physical examination an infiltrated crusty, erythematous 6 cm plaque with foci of necrosis was present on the back of the left hand (figure 1). There were no other remarkable findings. Additional evaluation showed a peripheral blood count with pancytopenia of 1920 leukocytes/mm<sup>3</sup>, 72.9% neutrophils, hemoglobin 10.7 g/dl, 87000 platelets/mm<sup>3</sup>, and a glucose level of 218 mg/dL.

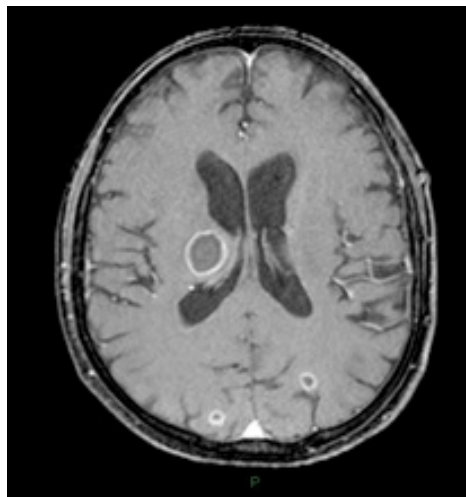
A skin biopsy of the lesion showed pseudoepitheliomatous hyperplasia, a dermal inflammatory lymphohistiocytic infiltrate with multinucleated giant cells of foreign body type, and neutrophils. PAS and methenamine silver staining helped to identify numerous fungal structures with septate hyphae and branches at 45 degrees in the stratum corneum, the stratum spinosum, and the dermis (figure 2). *Scedosporium apiospermum*, sensitive to voriconazole, grew from the tissue fungal culture. Bacterial and viral cultures were negative. A cranial computed tomography showed four rounded hypodense lesions with ring contrast enhancement and perilesional edema in the right thalamus (24 mm) and the right cerebellar hemisphere (14 mm). There was also cortico-subcortical connections from both occipital hemispheres (8 mm) compatible with abscesses. These findings were also visible on nuclear magnetic resonance imaging (MRI) (figure 3). Voriconazole 200 mg every 12 hours was started, with progressive improvement of the lesion in the left hand until its complete disappearance. Successive image studies demonstrated a decrease in the size of brain lesions. However, the patient's course was complicated by the appearance of neutropenia, probably of toxic etiology, that required the administration of granulocyte colony-stimulating factor (G-CSF). The patient died of multiple organ failure two months later.



**Figure 1.** Infiltrated crusted erythematous plaque on the back of the left hand.



**Figure 2.** PAS stain showing fungal structures with septate hyphae with branches in 45 degrees over the stratum corneum, the stratum spinosum, and the dermis.

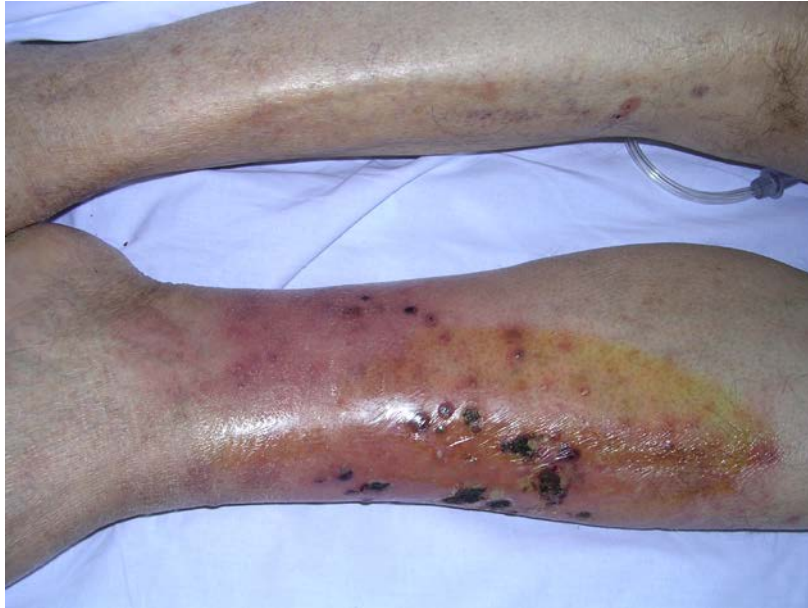

**Figure 3.** Cranial nuclear magnetic resonance showing rounded cerebral lesions compatible with abscesses.

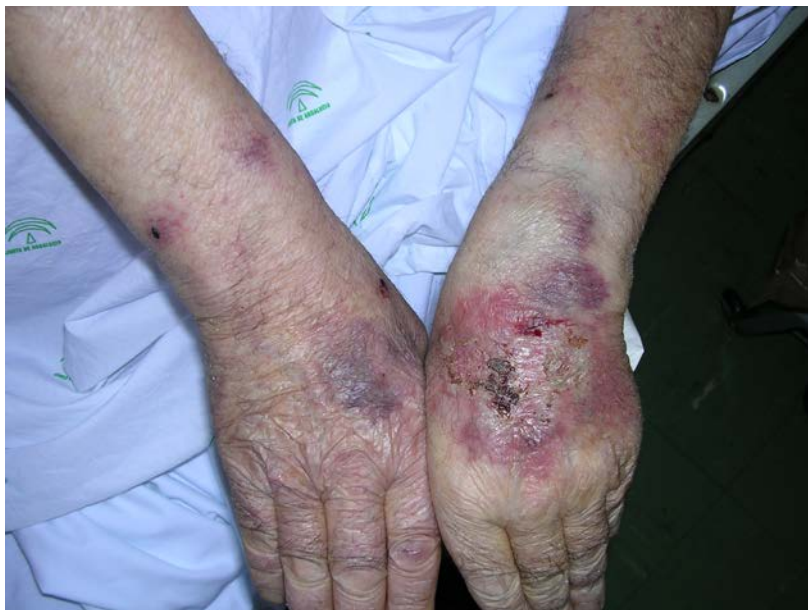## Case n°2

A 75-year-old male with a history of severe COPD requiring home oxygen therapy and oral prednisone for a long period of time was admitted to the internal medicine ward because of global decompensated respiratory failure, which later became complicated by pneumococcal pneumonia. He also had a history of hypertension, cor pulmonale, intolerance to carbohydrates, and benign prostatic hyperplasia. Other treatments consisted of aerosolized salmeterol and fluticasone, tiotropium bromide, torasemide, ramipril, and tamsulosin. The patient developed an acute onset of inflammatory pustules on his left pretibial region and the back of his left hand (Figures 4 and 5), along with numerous serosanguinous scabs on numerous lesions that were painful to touch. The culture of lesional exudate grew *S. apiospermum* sensitive to voriconazole. A biopsy from a typical lesion showed identical findings to the first case (figure 6). Despite voriconazole 200 mg every 12 hours, the cutaneous findings progressed resulting in indurated purplish plaques and ulcerated nodules with pustules and crusted ulcers in the left pretibial region (figure 7). In addition, there were two rounded nodules with purple halos in the left thigh, which on MRI

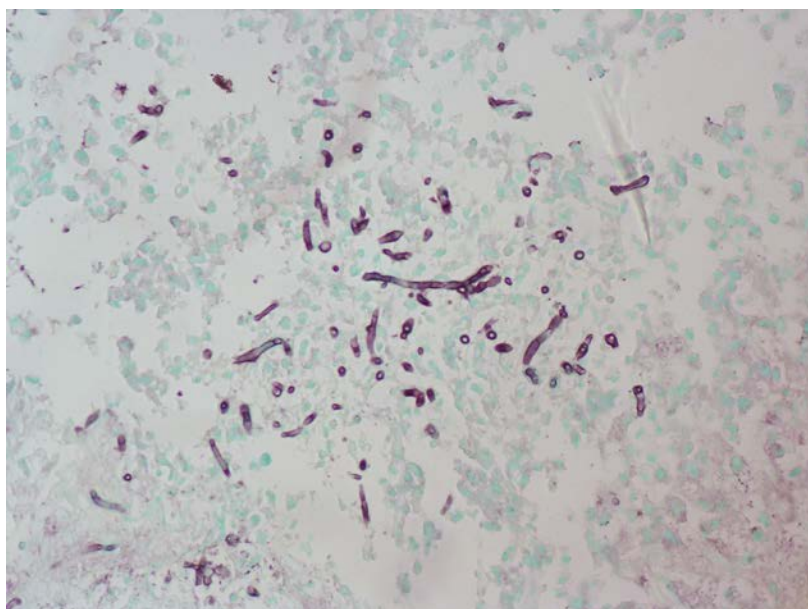
evaluation were compatible with abscesses. The patient required treatment with increasing doses of voriconazole at 400 mg every 12 hours and terbinafine 250 mg every 12 hours. After ten days of treatment, the eruption improved with disappearance of most lesions. However there was no improvement of the thigh lesions and surgical excision was performed. Therapy with voriconazole and terbinafine was maintained for a period of 8 weeks. Six months later, he was asymptomatic.



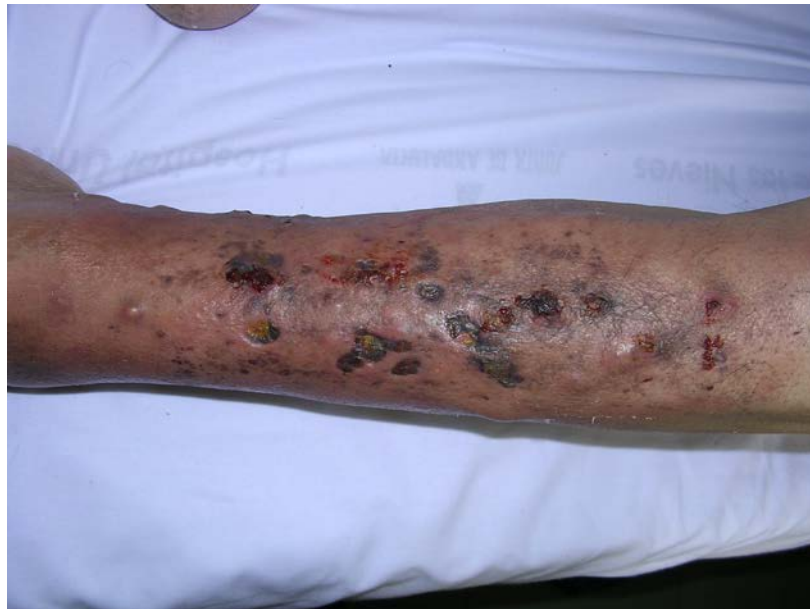**Figure 4.** Pustules and crusts over the left pretibial area.



**Figure 5.** Similar lesions over the dorsum of the left hand.



**Figure 6.** PAS stain showing septate hyphae within the dermis



**Figure 7.** Ulcerated plaques and nodules with pustules and crusts in the left pretibial region.

## Discussion

*Scedosporium apiospermum*, the asexual or anamorphic form of *Pseudallescheria boydii* [1, 2], is a saprophytic fungus of global distribution that can be found in soil and stagnant water or wastewater. In immunocompetent hosts, it causes infections usually after trauma or surgery. In temperate climates it is the most frequent cause of eumycetoma [3]. However, in immunosuppressed patients, the fungus is an opportunistic pathogen that spreads by hematogenous spread and causes infection of the skin and subcutaneous tissue, sinuses, ears, eyes, lungs, and nervous system [4].

The most common skin manifestations are subcutaneous nodules often associated with necrosis, fistulas, and exudate of purulent material [5, 6]. The lower extremities are the most common location. There are reports of sporotrichoid pattern in injuries [7, 8].

Over the last decades, the incidence of opportunistic fungal infections, such as *Scedosporium* [9], has increased. The vast majority of cases in the medical literature describe infection in immunosuppressed patients owing to organ transplantation, hematologic or autoimmune diseases, or treatment with corticosteroids or other immunosuppressive agents, as well as broad spectrum antibiotics.

Treatment of this fungus is not well standardized. *Scedosporium apiospermum* has shown resistance to antifungals such as amphotericin B or 5-flucytosine [10]. The imidazoles, particularly voriconazole, have shown a greater efficacy in the treatment of these infections, although the optimal therapeutic regimen has not been determined. Overall response rates of 57% and 91% have been reported in cases of cutaneous or subcutaneous infections [11]. We obtained a satisfactory response when we used a dose of 200 mg every 12 hours for case 1, although case 2 required elevation of the dose to 400 mg every 12 hours and the addition of terbinafine because of the low initial response. Side effects of voriconazole include visual disturbances, hepatitis, photosensitivity, pseudoporphyria, lymphadenopathy, and pancytopenia [5, 10, 11]. A recently published case of *Scedosporium apiospermum* skin infection responded well to intralesional injection of voriconazole [12]. Surgical debridement and drainage of lesions has also proven beneficial [9, 13].

The prognosis for these patients is often poor owing to complications that include pneumonia or brain abscess [14, 15, 16]. Opportunistic fungal infections with *Scedosporium* are more frequently reported and require prompt diagnosis and treatment.

## References

1. Tadros S, Workowski K, Siegel R, Hunter S, Schwartz D. Pathology of hyalohyphomycosis caused by *Scedosporium apiospermum* (*Pseudallescheria boydii*) An Emerging Mycosis. *Human Pathol* 1998; 29(11): 1266 –1272. [PMID: 9824105]
2. Shinohara MM, George E. *Scedosporium apiospermum*: an emerging opportunistic pathogen that must be distinguished from *Aspergillus* and other hyalohyphomycetes. *J Cutan Pathol*. 2009 Oct;36 Suppl 1:39-41 [PMID: 19775393]
3. Bower CP, Oxley JD, Campbell CK, Archer CB. Cutaneous *Scedosporium apiospermum* infection in an immunocompromised patient. *J Clin Pathol*. 1999 Nov;52(11):846-8. [PMID: 10690177]

4. Chaveiro MA, Vieira R, Cardoso J, Afonso A. Cutaneous infection due to *Scedosporium apiospermum* in an immunosuppressed patient. *J Eur Acad Dermatol Venereol*. 2003 Jan;17(1):47-9. [PMID: 12602968]
5. Stur-Hofmann K, Stos S, Saxa-Enenkel M, Rappersberger K. Primary cutaneous infection with *Scedosporium apiospermum* successfully treated with voriconazole. *Mycoses*. 2011 Jul;54(4):e201-4. [PMID: 19925568]
6. Harrison MK, Hiatt KH, Smoller BR, Cheung WL. A case of cutaneous *Scedosporium* infection in an immunocompromised patient. *J Cutan Pathol*. 2011 Oct 28. [PMID: 22032175]
7. Hagari Y, Ishioka S, Ohyama F, Mihara M. Cutaneous infection showing sporotrichoid spread caused by *Pseudallescheria boydii* (*Scedosporium apiospermum*): successful detection of fungal DNA in formalin-fixed, paraffin-embedded sections by seminested PCR. *Arch Dermatol*. 2002 Feb;138(2):271-2. [PMID: 11843660]
8. Török L, Simon G, Csornai A, et al. *Scedosporium apiospermum* infection imitating lymphocutaneous sporotrichosis in a patient with myeloblastic-monocytic leukemia. *Br J Dermatol* 1995; 133(5): 805 – 809. [PMID: 8555041]
9. Uenotsuchi T, Moroi Y, Urabe K, Tsuji G, Koga T, Matsuda T, Furue M. Cutaneous *Scedosporium apiospermum* infection in an immunocompromised patient and a review of the literature. *Acta Derm Venereol*. 2005;85(2):156-9. [PMID: 15823912]
10. Matsumoto Y, Oh-I T, Nagai A, Ohyama F, Ooishi T, Tsuboi R. Case of cutaneous *Scedosporium apiospermum* infection successfully treated with voriconazole. *J Dermatol*. 2009 Feb;36(2):98-102. [PMID: 19284454]
11. Troke P, Aguirrebengoa K, Arteaga C et al. Treatment of *Scedosporiosis* with voriconazole: Clinical experience with 107 patients. *Antimicrob Agents Chemother* 2008; 52: 1743–1750. [PMID: 18212110]
12. Azofra MM, Somovilla JL, Porrás MC, Carrillo LH, Pérez RD. Use of intralesional voriconazole for the treatment of cutaneous *Scedosporium apiospermum* infection. *Clin Infect Dis*. 2010 Jul 15;51(2):255-7. [PMID: 20560740]
13. Ruxin TA, Steck WD, Helm TN, Bergfeld WF, Bolwell BJ. *Pseudallescheria boydii* in an immunocompromised host. Successful treatment with debridement and itraconazole. *Arch Dermatol* 1996; 132: 382–384. [PMID: 8629840]
14. Gelabert González M, Llovo Taboada J, Reyes Santías R, Arcos Algaba A, Serramito García R, Peñalver Barral MD, García Allut A. *Scedosporium apiospermum* brain abscess. Report of one case with literature review. *Neurocirugia (Astur)*. 2010 Apr;21(2):125-31. [PMID: 20442975]
15. Montejó M, Muñoz ML, Zárraga S, Aguirrebengoa K, Amenabar JJ, López-Soria L, Gonzalez R. Case Reports. Infection due to *Scedosporium apiospermum* in renal transplant recipients: a report of two cases and literature review of central nervous system and cutaneous infections by *Pseudallescheria boydii*/*Sc. apiospermum*. *Mycoses*. 2002 Nov;45(9-10):418-27. [PMID: 12421295]
16. Makino K, Fukushima S, Maruo K, Egawa K, Nishimoto K, Ihn H. Cutaneous hyalohyphomycosis by *Scedosporium apiospermum* in an immunocompromised patient. *Mycoses*. 2011 May;54(3):259-61. [PMID: 19889175]