

## **UC Irvine**

### **Journal of Education and Teaching in Emergency Medicine**

#### **Title**

Bedside Ultrasound for the Diagnosis of Retinal Detachment

#### **Permalink**

<https://escholarship.org/uc/item/7zq56175>

#### **Journal**

Journal of Education and Teaching in Emergency Medicine, 3(3)

#### **Authors**

San Gabriel, Rami  
Alvarado, Maili  
Han, Vy

#### **Publication Date**

2018

#### **DOI**

10.5070/M533039851

#### **Copyright Information**

Copyright 2018 by the author(s). This work is made available under the terms of a Creative Commons Attribution License, available at <https://creativecommons.org/licenses/by/4.0/>

Peer reviewed

## Bedside Ultrasound for the Diagnosis of Retinal Detachment

Rami San Gabriel, BS\*, Maili Alvarado, MD\* and Vy Han, MD\*

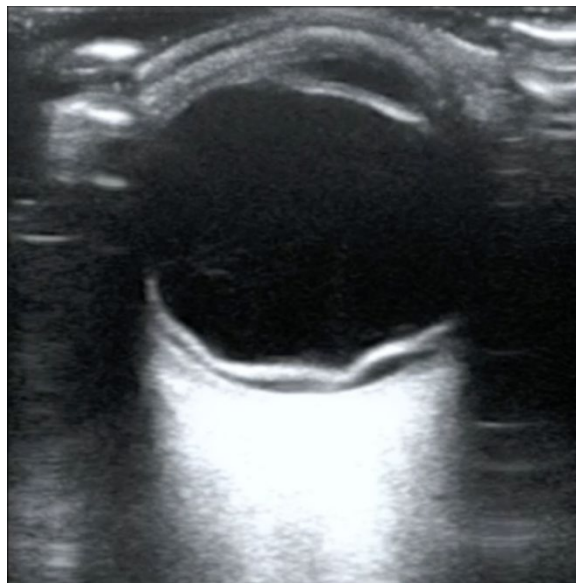
\*University of California, Irvine, Department of Emergency Medicine, Orange, CA

Correspondence should be addressed to Rami San Gabriel, BS at [ramisg@uci.edu](mailto:ramisg@uci.edu)

Submitted: May 30, 2017; Accepted: September 15, 2017; Electronically Published: July 15, 2018; <https://doi.org/10.21980/J80W6T>

Copyright: © 2018 San Gabriel, et al. This is an open access article distributed in accordance with the terms of the Creative Commons Attribution (CC BY 4.0) License.

See: <http://creativecommons.org/licenses/by/4.0/>



Video Link: <https://youtu.be/FfucF2Vl6S4>

**History of present illness:** A 19-year-old male with no significant past medical history presented to the Emergency Department with progressively worsening vision loss in his right eye after blunt trauma to the right orbit. The patient endorsed floaters and described his vision as being “cloudy,” but denied any photophobia, foreign body sensation, pain or ocular discharge. He did not use corrective lenses and his visual acuity was 20/100 OD and 20/30 OS. On exam, the patient had non-injected conjunctiva and normal intraocular pressures. Bedside ultrasound was performed and showed evidence of a right-sided retinal detachment and vitreous hemorrhage. Ophthalmology was emergently consulted and took the patient to the operating room for cryopexy.

**Significant findings:** The ocular point of care ultrasound (POCUS) utilizing a high frequency linear probe shows a retinal detachment (RD) with a thick, hyperechoic undulating membrane in the vitreous humor that is anchored at the ora serrata anteriorly and the optic disc posteriorly. Note that the retina is detached all

the way to the optic disc making it "mac off." The macula, and more specifically the fovea, is located in the central retina and contains a high concentration of cone photoreceptors responsible for central, high resolution, color vision. In a "mac on" RD, the retina detaches in the periphery but remains intact centrally. This is an ophthalmologic emergency and timely diagnosis and intervention can be vision saving. This patient also has evidence of a posterior vitreous hemorrhage which has a characteristic swirling appearance with kinetic exam on real-time imaging. The detached vitreous body is not as well defined and is not anchored posteriorly to the optic disc.

**Discussion:** There are many causes of sudden unilateral vision loss: acute angle closure glaucoma, vitreous hemorrhage, retinal detachment, vitreous detachment, retinal artery occlusion, retinal vein occlusion, optic neuritis, and ischemic optic neuropathy.<sup>1</sup> Many of these cases require emergent intervention if the patient's vision is to be preserved. In this case, the patient's history of "floaters" is highly suggestive of a retinal etiology. Classically, patients with RD can also present with the perception of a "dark curtain" coming over their field of vision.<sup>2</sup> In a review of 78 articles, ocular ultrasound had a sensitivity and specificity that ranged from 97% to 100% and 83% to 100%, respectively, in the diagnosis of RD,<sup>3</sup> demonstrating its strength as a rapid diagnostic tool in accurately diagnosing RD.

**Topics:** Ultrasound, ophthalmology, retina.

**References:**

1. Bagheri N, Mehta S. Acute vision loss. *Prim Care Clin Office Pract.* 2015;42(3):347-361. doi: 10.1016/j.pop.2015.05.010
2. Fledge N, Walter P. Rhegmatogenous Retinal Detachment—an ophthalmologic emergency. *Deutsches Ärzteblatt International.* 2014;111(1-2):12-22. doi: 10.3238/arztebl.2014.0012
3. Vrablik ME, Snead GR, Minnigan HJ, Kirschner JM, Emmett TW, Seupaul RA. The diagnostic accuracy of bedside ocular ultrasonography for the diagnosis of retinal detachment: A systematic review and meta-analysis. *Ann Emerg Med.* 2015;65(2):199-203.e1. doi: 10.1016/j.annemergmed.2014.02.020