

UC Irvine

UC Irvine Previously Published Works

Title

Ovarian Thecoma with Virilizing Manifestations

Permalink

<https://escholarship.org/uc/item/7w6039rb>

Journal

Yonsei Medical Journal, 50(1)

ISSN

0513-5796

Authors

Lee, Mun-Hwi
Moon, Young-Jin
Ha, Chang-Won
[et al.](#)

Publication Date

2009

DOI

10.3349/ymj.2009.50.1.169

Peer reviewed

Ovarian Thecoma with Virilizing Manifestations

Mun-Hwi Lee,¹ Young-Jin Moon,¹ Chang-Won Ha,² and Jeong-Kyu Hoh³

Departments of ¹Obstetric and Gynecology and ²Pathology, Halla General Hospital, Jeju, Korea; ³Department of Obstetrics and Gynecology, University of California, Irvine, College of Medicine, Irvine, CA, USA.

A 29-year-old woman presented with secondary amenorrhea, primary infertility, and virilization, which had developed over the past 2 years was suspected to have a virilizing tumor at her left ovary. Her serum testosterone level was markedly elevated (380 ng/dL). Left salpingoophorectomy was performed, and histopathological examination revealed a thecoma of the left ovary. The postoperative serum testosterone level returned to 65 ng/dL. The patient did not have regression of virilism soon. However, the patient had a normal menstruation 29 days after surgery and gave birth to a baby 13 months after surgery.

Key Words: Virilism, thecoma, testosterone

INTRODUCTION

Virilizing ovarian tumors are a rare cause of hyperandrogenism in women, and account for less than 5% of all ovarian neoplasms and those that are malignant for less than 10% of all ovarian cancers.¹⁻⁴ In most cases the hormonal abnormalities present in patients with virilizing ovarian tumors include increased serum testosterone levels in the presence of normal levels of serum dehydroepiandrosterone-sulfate.⁵ Most hormonally active ovarian tumors belong to the gonadal stroma category.³ Ovarian thecoma is a rare benign tumor of stromal cell origin, and represents less than 1% of all ovarian tumors. It occurs most often in perimenopausal and postmenopausal women.⁶ Typical thecomas are almost always estrogenic; the luteinized forms are virilizing in about 10% of cases.² We report the case of a 29-year-old woman with a left

ovarian virilizing thecoma who gave birth to a baby 13 months after surgery.

CASE REPORT

A 29-year-old woman (gravida 0, para 0) who had complained of secondary amenorrhea, primary infertility, and progressive virilization; hirsutism, deepening voice, acne, enlargement of the clitoris admitted to our hospital in July 2004 with the suspicion of a virilizing ovary tumor. The virilizing manifestations were progressive from June 2003. She had no special past medical history and family history. She had regular menstruation of 28 days cycle starting at 14, however the menstruation ceased in December 2002. She had never been pregnant in 18 months of her married life.

Physical examination showed hirsutism of her face and body, a deep voice, acne on her face, and enlargement of the clitoris. However, she had no features suspected Cushing syndrome. Breasts and muscles were normal but left adnexal mass about 5 cm was palpated on gynecological examination. Her blood pressure was 120/80 mmHg.

Hemoglobin, hematocrit, fasting blood glucose, serum electrolytes, cholesterol, triglyceride, calcium, phosphorus, and renal and liver function tests were normal. Tumor marker levels in the serum of CA 125, CA 19-9, and AFP were normal. Her chest X-ray and EKG detected no abnormalities.

Endocrine evaluation revealed a markedly increased serum testosterone concentration (380 ng/dL), while the concentrations of dehydroepiandrosterone-sulfate was within normal range (180 µg/dL). Serum prolactin and thyroid stimulating hormone (TSH) were normal. Serum luteinizing

Received April 10, 2007
Accepted July 14, 2007

Reprint address: requests to Dr. Jeong-Kyu Hoh, Department of Obstetrics and Gynecology, University of California, Irvine, College of Medicine, Irvine, CA 92679, USA. Tel: 1-949-824-2409, Fax: 1-949-824-2403, E-mail: regularey@gmail.com

hormone (LH; 14.7 mIU/mL), follicle stimulating hormone (FSH; 2.0 mIU/mL), and estradiol (55.0 pg/mL) concentrations were within normal range.

Transvaginal ultrasound examination suggested the presence of a solid, movable, and homogenous-echoic mass (6.3 × 4.1 cm) originated in the left ovary. No pathologic findings within right ovary and uterus were found. No ascites was detected. Abdominal and pelvic computed tomography (CT) scans demonstrated a left ovarian solid mass measuring 5.5 cm in diameter. The mass was well-demarcated, round, homogenous and well-enhanced. No pathologic findings of other pelvic organs, ascites, and lymphatic enlargements were detected (Fig. 1).

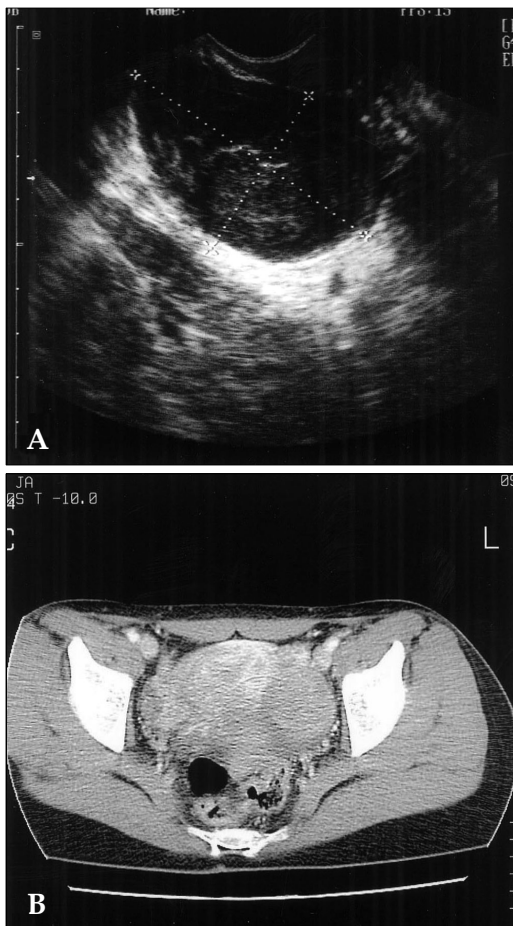


Fig. 1. Transvaginal ultrasonography of a homogenous-echoic mass originated in the left ovary (A), and abdominal and pelvic computed tomography (CT) scans of a left ovarian solid mass which was well-demarcated, round, homogenous and well-enhanced. No pathologic findings of other pelvic organs, ascites, and lymphatic enlargements were detected (B).

At laparotomy, a smooth-surfaced, yellowish, solid, and movable tumor was found to originate in the left ovary, and measured 7 × 5 cm (Fig. 2). The uterus and right ovary were macroscopically normal. No pelvic adhesion, ascites, and findings of dissemination from the malignant ovarian tumor were observed in the abdominal cavity. So we performed left salpingo-oophorectomy.

Histopathological examination of the left ovarian tumor revealed a thecoma consisting of spindle cells with blunt ended nuclei and ill defined cytoplasm. The solid mass was consisted of fascicles of stromal cells, and some were vacuolated (Fig. 3). Masson trichrome staining shows very little collagen deposition in focal stromal pattern supposed to be a fibroma component (Fig. 4). There were no other tumor components such as granulosa cell tumor, or fibrosarcoma in this tumor.

The postoperative course was uncomplicated. She was discharged from hospital without any complications on the 4th day after surgery. Fourteen days after the surgery, serum testosterone level was reduced to 65 ng/dL. She had a normal menstruation 29 days after the surgery, and after that menstruation she was pregnant. On 10 June 2005 (38 weeks and 5 days of gestation), she gave birth to a male baby, 3,560 gm in weight and Apgar score 8/9 by cesarean section due to breech presentation. On 29 September 2006, she gave birth to the second baby boy, 3,020 gm in weight (Apgar score 8/9) by cesarean section.

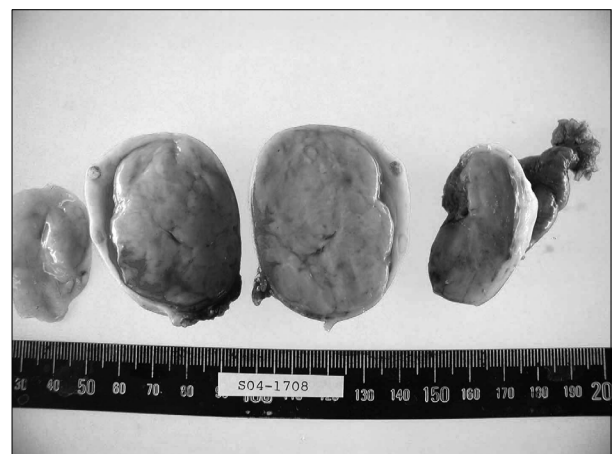

Fig. 2. A smooth-surfaced, yellowish, solid, and movable tumor was found to originate in the left ovary, measured 7 × 5 cm.

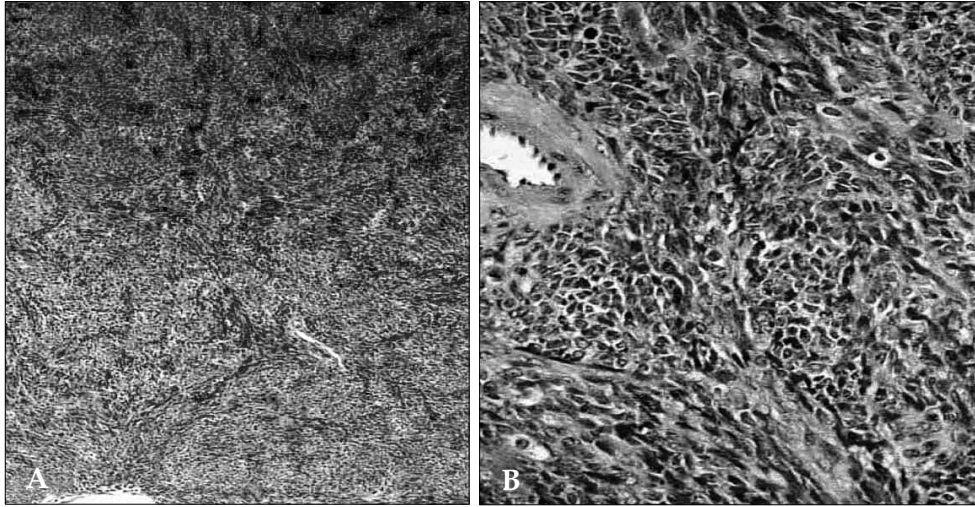


Fig. 3. A thecoma consisting of spindle cells with blunt ended nuclei and ill defined cytoplasm. The solid mass was consisted of fascicles of stromal cells, and some were vacuolated (H & E, (A) $\times 100$, (B) $\times 400$).




Fig. 4. Masson trichrome staining shows very little collagen deposition in focal stromal pattern (arrow) ((A) $\times 100$, (B) $\times 400$).

DISCUSSION

Ovarian thecoma, which is classified as a germinal cord interstitial ovarian tumor, is very rare, accounting for about 1% of solid ovarian tumors.⁴ The incidence of this tumor is reported to be highest among pre- and postmenopausal women of 50 - 60 years of age.⁷ Most thecomas range within 5 - 10 cm in size and are bilateral in 3% of cases.⁸ It is generally agreed that thecomas are benign although most of them are solid. Non-malignant disorders usually follow a more slowly progressive benign course, as compared with the rapid progressive virilization seen with underlying malignancy.⁹ It has been suggested that a simple clinical assessment and a single serum testosterone

measurement may be sufficient to differentiate between benign and malignant virilizing tumors in women presenting with hirsutism and androgenic features.¹⁰ The value of measuring serum androstenedione levels has been shown to be of less benefit. A full endocrinological evaluation is usually indicated in the patients with an elevated serum testosterone level.

Ovarian stromal cell tumors may secrete large amounts of testosterone, which may produce rapidly progressing androgenic effects.¹¹ Theca cell tumors may secrete also cause hyperandrogenism,¹² although these tumors usually appear to be estrogenic.¹ Androgen secretion of an ovarian tumor before menarche results in heterosexual precocity, with virilizing manifestation and accelerated

somatic growth.¹³ During reproductive age the typical picture of androgen secretion is oligomenorrhea, defeminization and progressive masculinization (hirsutism, temporal balding, enlargement of the clitoris, deepening of the voice and muscular development).⁴ In the case of a 24-year-old woman described by Takeuchi and colleagues,¹⁴ masculinization developed over a few months. Symptoms of defeminization and masculinization may appear simultaneously but signs of defeminization usually show before those of masculinization.¹⁵

A post-menopausal woman occasionally has a history of long-standing mild virilism. The patients with ovarian thecoma and concomitant post-menopausal bleeding, endometrial hyperplasia, endometrial carcinoma were reported in post-menopausal women.¹⁶ Our patient presented virilizing features developed over 13 months, progressive from June 2003.

Surgery is the primary treatment of virilizing thecoma. Wedge resection of ovarian lesions suffices for patients who need to preserve fertility, but oophorectomy is performed more commonly because patients sometimes have thecoma mixed with granulosa cell tumor which has low malignant potential. Hysterectomy can be performed on patients who don't need to keep their uterus because patients with thecoma may have endometrial hyperplasia or endometrial carcinoma.¹⁷

After surgery, symptoms of defeminization may disappear. Four months after the surgery, menstruation begins and other symptoms disappear in the order of their appearance but enlargement of clitoris may last for 20 years.¹⁸ This patient began her menstruation 29 days after the surgery. The prognosis of our patient was good and we have not observed relapse during follow-up.

In our case, we also performed left salpingo-oophorectomy. Fourteen days after the surgery, serum testosterone level was reduced to normal range. She had a normal menstruation 4 weeks after the surgery, and after that menstruation she was pregnant. Also, she gave birth to a baby boy without any complications. Ovarian virilizing tumors are an uncommon cause of common clinical problems. Our patient was treated by unilateral oophorectomy, a curative therapy for ovarian thecoma, which resulted in a favorable obstetric

outcome.

REFERENCES

1. Fox H. Sex cord-stromal tumours of the ovary. *J Pathol* 1985;145:127-48.
2. Keeney GL. Ovarian tumors with endocrine manifestations. In: De Groot LJ, editor. *Endocrinology*. 4th ed. Philadelphia (PA): WB Saunders Company; 2001. p.2172.
3. Stegner HE, Löning T. Endocrine-active tumors of the ovary. *Pathologie* 2003;24:314-22.
4. Siekierska-Hellmann M, Sworczyk K, Babińska A, Wojtylak S. Ovarian thecoma with androgenic manifestations in a postmenopausal woman. *Gynecol Endocrinol* 2006;22:405-8.
5. Shenker Y, Malozowski SN, Ayers J, Grekin RJ, Barkan AL. Steroid secretion by a virilizing lipoid cell ovarian tumor: origins of dehydroepiandrosterone sulfate. *Obstet Gynecol* 1989;74:502-6.
6. Takemori M, Nishimura R, Hasegawa K. Ovarian thecoma with ascites and high serum levels of CA 125. *Arch Gynecol Obstet* 2000;264:42-4.
7. Wu L, Zhang W, Li H, Li L, Kong W, Lin L. Clinical analysis of 74 cases with ovarian thecoma. *Zhonghua Fu Chan Ke Za Zhi* 2002;37:101-3.
8. Duun S. Bilateral virilizing hilus (Leydig) cell tumors of the ovary. *Acta Obstet Gynecol Scand* 1994;73:76-7.
9. Leedman PJ, Bierre AR, Martin FI. Virilizing nodular ovarian stromal hyperthecosis, diabetes mellitus and insulin resistance in a postmenopausal woman. Case report. *Br J Obstet Gynaecol* 1989;96:1095-8.
10. O'Driscoll JB, Mamtara H, Higginson J, Pollock A, Kane J, Anderson DC. A prospective study of the prevalence of clear-cut endocrine disorders and polycystic ovaries in 350 patients presenting with hirsutism or androgenic alopecia. *Clin Endocrinol (Oxf)* 1994;41:231-6.
11. Loh KC, Lo JC, Zaloudek CJ, Fitzgerald PA. Occult virilizing ovarian tumours in postmenopausal women: problems in evaluation with reference to a case. *Ann Acad Med Singapore* 1998;27:712-6.
12. Nokes JM, Claiborne HA Jr, Reingold WN. Thecoma with associated virilization. *Am J Obstet Gynecol* 1959;78:722-9.
13. Scully RE. Ovarian tumors with endocrine manifestations. In: Fauci AS, Braunwald E, Isselbacher KJ, Wilson JD, Martin JB, Kasper DL, Hauser SL, et al., editors. *Harrison's principles of internal medicine*. 14th ed. New York: McGraw-Hill; 1998. p.2113-27.
14. Takeuchi S, Ishihara N, Ohbayashi C, Itoh H, Maruo T. Stromal Leydig cell tumor of the ovary. Case report and literature review. *Int J Gynecol Pathol* 1999;18:178-82.
15. Lee CH, Moon WS, Hong KE, Choi YK, Nam KH, Lee KH, et al. A case of hyperthecosis associated with virilization in the premenopausal woman. *Korean J*

- Obstet Gynecol 1992;35:150-6.
16. Aboud E. A review of granulosa cell tumours and thecomas of the ovary. Arch Gynecol Obstet 1997;259: 161-5.
 17. Joe Y, Jung YH, Ro ES, Kim YP, Kwon SU. Two cases of theca cell tumor of the ovary. Korean J Obstet Gynecol 1992;35:451-5.
 18. Piver MS. Ovarian malignancies: diagnostic and therapeutic advances. Edinburgh: Churchill Livingstone; 1987. p.251-71.