

UCSF

UC San Francisco Previously Published Works

Title

A Bipedicled Flap for Closure of the Anterolateral Thigh Flap Donor Site.

Permalink

<https://escholarship.org/uc/item/7tk2z3z1>

Journal

Plastic and reconstructive surgery. Global open, 8(8)

ISSN

2169-7574

Authors

Piper, Merisa L
Stranix, John T
Bast, John H
et al.

Publication Date

2020-08-01

DOI

10.1097/gox.0000000000002770

Peer reviewed

A Bipedicled Flap for Closure of the Anterolateral Thigh Flap Donor Site

Merisa L. Piper, MD*
 John T. Stranix, MD†
 John H. Bast, MD‡
 Stephen J. Kovach, MD‡

Summary: Anterolateral thigh (ALT) free flaps have become reliable options for head-to-toe reconstruction. Although perforator anatomy is fairly predictable, in cases of eccentric perforator location, we proposed shifting the entire flap laterally and preserving a medial bipedicled flap between the original incision and the new medial flap margin. This facilitates primary donor site closure instead of harvesting a flap larger than anticipated. We conducted a retrospective chart review of ALT flaps performed between 2007 and 2019 and identified patients who underwent bipedicled closure of the donor site. Demographics, flap characteristics, and surgical technique were evaluated. Six patients had bipedicled donor site closure related to primary perforators located lateral to the original flap design. The mean defect size was 91 cm², and bipedicled flap width ranged from 4 to 6 cm. All donor sites were closed primarily. Five of the donor thigh sites healed without complications, and 1 patient had superficial delayed healing of the medial bipedicled incision, which healed with local wound care. The ALT has become an invaluable flap in microsurgical reconstruction, yet it is not without limitations. Primary donor site closure is generally not feasible for larger flaps, thus necessitating skin grafting of the donor site and/or prolonged wound care. Our technique facilitates primary closure of the donor site in patients who otherwise would have required harvest of a larger than necessary flap based on eccentric perforator anatomy. The medial bipedicled flap is straightforward, reproducible, and allows for modifications of the original flap design to better fit the defect. (*Plast Reconstr Surg Glob Open* 2020;8:e2770; doi: [10.1097/GOX.0000000000002770](https://doi.org/10.1097/GOX.0000000000002770); Published online 14 August 2020.)

INTRODUCTION

The anterolateral thigh (ALT) perforator flap has become a workhorse in microsurgical reconstruction. This flap has the potential to provide ample soft tissue with reliable perforator anatomy, a consistently long pedicle length, and minimal donor site morbidity.¹⁻⁶ The anatomic landmarks for the flap have been well described, with the longitudinal axis of the flap centered over a line drawn from the anterior superior iliac spine to the superolateral patella that approximates the location of the

intermuscular septum between vastus lateralis and rectus femoris.^{7,8} The perforators are typically found within a 4-cm diameter circle around the midpoint of this line and are typically used for flap perfusion.⁹

Despite the reliability of these markings, there are occasional instances where the perforator of interest is located more laterally than expected when the flap is elevated. This may be due to a significant intramuscular course resulting in a more lateral perforator location, or if the markings were made without internal rotation of the foot, a medial displacement of the flap design. In this scenario, the surgeon must decide among 3 options: (1) harvesting a flap that is wider than anticipated to center the flap over the perforator, which may preclude primary donor site closure; (2) elevate the flap with an eccentrically located perforator along the lateral margin of the flap, which may compromise flap perfusion; or (3) change the perforator to an adjacent, less-desirable perforator.¹⁰

Considering that none of these options are ideal, the senior author has developed a technique that shifts the ALT flap design laterally so that it is centered over the perforator of interest. This preserves a medial bipedicled

From the *Division of Plastic and Reconstructive Surgery, University of California, San Francisco, San Francisco, Calif.; †Department of Plastic and Reconstructive Surgery, University of Virginia, Charlottesville, Va.; and ‡Division of Plastic and Reconstructive Surgery, University of Pennsylvania, Philadelphia, Pa.

Received for publication August 23, 2019; accepted February 19, 2020.

Copyright © 2020 The Authors. Published by Wolters Kluwer Health, Inc. on behalf of The American Society of Plastic Surgeons. This is an open-access article distributed under the terms of the [Creative Commons Attribution-Non Commercial-No Derivatives License 4.0 \(CCBY-NC-ND\)](https://creativecommons.org/licenses/by-nc-nd/4.0/), where it is permissible to download and share the work provided it is properly cited. The work cannot be changed in any way or used commercially without permission from the journal.

DOI: [10.1097/GOX.0000000000002770](https://doi.org/10.1097/GOX.0000000000002770)

Disclosure: Dr. Kovach is a consultant for Bard Davol, W.L. Gore, and Integra Life Sciences. The other authors have no financial interest to declare.

flap, which permits primary donor site closure. We provide a description of the technique, as well as our experience with 6 patients.

METHODS

We reviewed all patients who underwent ALT flap reconstruction by 2 of the authors between 2007 and 2019. Patients were included if they underwent ALT free flap reconstruction with bipediced flap donor site closure (6 of 121 patients, 5%). Charts were reviewed for demographics, preoperative and operative details, and postoperative outcomes.

Surgical Technique

The ALT flap was designed according to the markings previously described and centered over the anticipated location of the B perforator based on preoperative and intraoperative handheld Doppler findings. The pinch test provides guidance for flap width. Subfascial dissection was used for flap elevation starting from the anterior margin of the flap, preserving all perforators, until the perforator of interest was identified. In all cases, the desired perforator was noted to be significantly more lateral on the undersurface of the flap than anticipated and resulted in an

eccentric location within the initial flap design. To center the perforator within the flap, the flap design was transposed laterally and remarked (Fig. 1). The anterior margin of the new flap design comprised the lateral border of the bipediced flap and was marked to preserve 4–6 cm of bipediced flap width along its length to optimize vascularity. After the ALT flap was harvested, suprafascial dissection along the entire length of the bipediced flap was performed. The bipediced flap was then closed along its entire anterior length and then its posterior length.

RESULTS

Over the 12-year period, the bipediced flap donor site closure technique was used in 6 patients. In all cases, the perforator of choice was eccentrically located from the original flap design. The decision was made to shift the flap, thereby creating a bipediced flap, to enable primary closure of the donor site.

The average age of the patients was 45.8 years (range, 22–63 years), and the average body mass index was 26.2 years (range, 18.6–35.3 years) (Table 1). Five patients were men, and 1 patient was a woman. In 5 patients, the ALT flap was a fasciocutaneous flap, and in 1 patient, a segment of the vastus lateralis was taken as part of the flap.

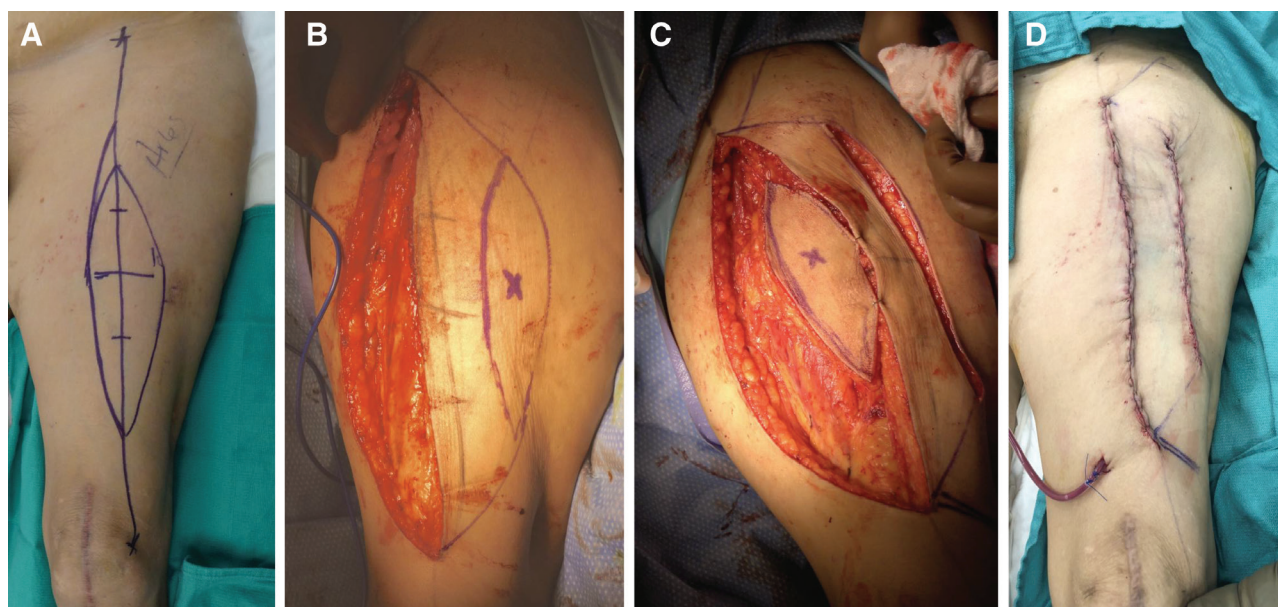


Figure 1. Photographs of a patient in whom a medial bipediced flap was used to shift the design of the ALT flap to facilitate primary closure. A, Original flap design. B, Lateral shift of flap design, creating a 6-cm bipediced flap. C, ALT flap elevated and shifted medial to the bipediced flap. D, Primary closure of the donor site.

Table 1. Patient Demographics

Patient	Age	Sex	BMI	Comorbidities	Indication for Procedure
1	49	M	27.9	CAD, HTN, MI, PVD	PVD, chronic wound
2	63	M	20.1	Alcohol abuse, HCV, PVD, seizure disorder	Necrotizing fasciitis
3	54	F	25.0	None	Chronic osteomyelitis
4	53	M	18.6	IVDU	Orbital sarcoma, previous XRT
5	34	M	35.3	None	Gustilo 3B open fracture
6	22	M	30.4	None	Gustilo 3B open fracture

BMI, body mass index; CAD, coronary artery disease; F, female; HTN, hypertension; HCV, hepatitis C virus; IVDU, intravenous drug use; M, male; MI, myocardial infarction; PVD, peripheral vascular disease; XRT, radiation therapy.

Five of the flaps were used to reconstruct defects of the lower extremity, and 1 was used for a maxillofacial defect. Indications for flap reconstruction included peripheral vascular disease, necrotizing fasciitis, chronic osteomyelitis with associated chronic wound, acute trauma with Gustilo 3B fracture, and orbital sarcoma. Average defect size was 91 cm² (range, 50–225 cm²), with ALT flap widths ranging from 6 to 8 cm. In all of the lower extremity cases, the posterior tibial vessels were used as recipient vessels, and the artery was sewn in using an end-to-side technique. In the maxillofacial reconstruction, contralateral facial vessels were used, which required interposition greater saphenous vein grafting.

The bipedicled flap enabled primary donor site closure in all patients. Five of the thigh donor sites healed without complications. One patient had delayed healing of the medial bipedicled incision, which was treated with local wound care. Five of the ALT flaps healed well, and 1 developed a small superficial wound, which was treated with local wound care.

DISCUSSION

The versatility of the ALT flap has led it to be our flap of choice when performing microsurgical reconstruction throughout all areas of the body. However, like all flaps, it has its limitations; one such being the inability to accurately predict where the dominant perforator will lie 100% of the time. Additionally, if a larger flap is taken, primary donor site closure is generally not feasible for flaps larger than 8 × 25 cm.

Traditionally, if the dominant perforator was more eccentrically or laterally located, we would have harvested a larger flap and then trimmed it down with inset. This often led to skin grafting of the donor site and/or prolonged wound care or wound vac therapy. This is not ideal for a number of reasons, one of which is that the skin grafting of the donor site has been shown to cause a decreased range of motion at the hip and knee joints, attributed to adhesions between the skin graft and the underlying muscle fascia.¹¹ Alternatively, we could have harvested a free vastus lateralis flap instead of a fasciocutaneous flap. However, we prefer the pliability of a fasciocutaneous flap and thus favor the bipedicled flap solution.

The creation of a bipedicled flap facilitates primary closure of the donor site and allows for modifications of the original flap design to better fit the defect. Our technique

is reproducible and straightforward and would be useful for every microsurgeon to have in their armamentarium. Additionally, this technique may be applicable to a number of other perforator-based fasciocutaneous flaps to facilitate closure when the perforator of interest does not correlate with the preoperative markings.

Stephen J. Kovach, MD

Division of Plastic Surgery
University of Pennsylvania
3400 Civic Center Boulevard
South Tower, 14th Floor
Philadelphia, PA 19104

E-mail: stephen.kovach@pennmed.upenn.edu

REFERENCES

1. Kuo YR, Seng-Feng J, Kuo FM, et al. Versatility of the free anterolateral thigh flap for reconstruction of soft-tissue defects: review of 140 cases. *Ann Plast Surg.* 2002;48:161–166.
2. Koshima I, Fukuda H, Utunomiya R, et al. The anterolateral thigh flap; variations in its vascular pedicle. *Br J Plast Surg.* 1989;42:260–262.
3. Kimata Y, Uchiyama K, Ebihara S, et al. Anatomic variations and technical problems of the anterolateral thigh flap: a report of 74 cases. *Plast Reconstr Surg.* 1998;102:1517–1523.
4. Koshima I, Fukuda H, Yamamoto H, Moriguchi T, Soeda S, Ohta S. Free anterolateral thigh flaps for reconstruction of head and neck defects. *Plast Reconstr Surg.* 1993;92:421–428; discussion 429–430.
5. Wei FC, Jain V, Celik N, et al. Have we found an ideal soft-tissue flap? An experience with 672 anterolateral thigh flaps. *Plast Reconstr Surg.* 2002;109:2219–2226; discussion 2227.
6. Hanasono MM, Skoracki RJ, Yu P. A prospective study of donor-site morbidity after anterolateral thigh fasciocutaneous and myocutaneous free flap harvest in 220 patients. *Plast Reconstr Surg.* 2010;125:209–214.
7. Lin SJ, Rabie A, Yu P. Designing the anterolateral thigh flap without preoperative Doppler or imaging. *J Reconstr Microsurg.* 2010;26:67–72.
8. Song YG, Chen GZ, Song YL. The free thigh flap: a new free flap concept based on the septocutaneous artery. *Br J Plast Surg.* 1984;37:149–159.
9. Yu P, Youssef A. Efficacy of the handheld Doppler in preoperative identification of the cutaneous perforators in the anterolateral thigh flap. *Plast Reconstr Surg.* 2006;118:928–933; discussion 934.
10. Hong JP, Kim EK, Kim H, et al. Alternative regional flaps when anterolateral thigh flap perforator is not feasible. *J Hand Microsurg.* 2010;2:51–57.
11. Kimata Y, Uchiyama K, Ebihara S, et al. Anterolateral thigh flap donor-site complications and morbidity. *Plast Reconstr Surg.* 2000;106:584–589.