

UC Davis

Dermatology Online Journal

Title

Pseudoxanthoma elasticum-like papillary dermal elastolysis; A report of two cases and a literature review

Permalink

<https://escholarship.org/uc/item/7t19r3gx>

Journal

Dermatology Online Journal, 30(5)

Authors

Murshidi, Rand
Bani Hamad, Salsabiela
Al-Tarawneh, Awad

Publication Date

2024

DOI

10.5070/D330564429

Copyright Information

Copyright 2024 by the author(s). This work is made available under the terms of a Creative Commons Attribution-NonCommercial-NoDerivatives License, available at <https://creativecommons.org/licenses/by-nc-nd/4.0/>

Peer reviewed

Pseudoxanthoma elasticum–like papillary dermal elastolysis; a report of two cases and a literature review

Rand Murshidi¹, Salsabiela Bani Hamad¹, Awad Al-Tarawneh²

Affiliations: ¹Division of Dermatology, Department of Medicine, School of Medicine, The University of Jordan, Amman, Jordan, ²Division of Dermatology, Department of Internal Medicine and Forensic Medicine, Faculty of Medicine, Mu'tah University, Al-Karak, Jordan

Corresponding Author: Salsabiela Bani Hamad, Division of Dermatology, Department of Medicine, School of Medicine, The University of Jordan, Queen Rania Al-Abdullah Street–Aljubeiha, PO Box 13046, Amman 11942, Jordan, Tel: 962-789569230, Email:

Salsabiela.bh@gmail.com

Abstract

Pseudoxanthoma elasticum-like papillary dermal elastolysis is a rare, benign, acquired, gradually-developing chronic elastic tissue disorder that almost exclusively affects post-menopausal women. It is essential to recognize this disease as it mimics the inherited pseudoxanthoma clinically. The pathophysiology behind this disease is multifactorial; it includes intrinsic skin aging, ultraviolet radiation exposure, and genetic components. We report two patients with pseudoxanthoma elasticum-papillary dermal elastolysis diagnosis based on clinicopathologic correlation in two post-menopausal women who presented with multiple asymptomatic papules over the neck that developed gradually without systemic involvement, and were managed conservatively. We also discuss this disease's clinical, dermoscopic, and histopathologic features.

Keywords: elastic tissue, elastolysis, fibroelastic papulosis, fibroelastolytic disorder

Introduction

Pseudoxanthoma elasticum (PXE)–like papillary dermal elastolysis (PDE) is an acquired age-related fibroelastolytic disorder that Rongioletti and Rebora first described in 1992 [1]. It is a rare but probably underestimated elastic tissue disorder; until now, around 60 cases have been reported worldwide [2].

Pseudoxanthoma elasticum–like papillary dermal elastolysis falls under the broader category of fibroelastolytic papulosis, which itself comprises two subcategories, PXE-PDE and white fibrous papulosis of the neck [3]. Clinically, it resembles inherited PXE. However, it lacks systemic manifestations, and this entity can be differentiated from PXE histologically. It is important to recognize this condition to avoid extensive investigations and referrals [2].

Case Synopsis

Case 1

A 65-year-old woman with a medical history of insulin resistance presented to the dermatology clinic concerned about the appearance of asymptomatic papules over the posterior and lateral aspects of the neck of two years' duration. Upon examination, the papules were deep-seated, palpable, of yellow color, confluent, and non-follicular; there were no other similar lesions in any other body area (**Figure 1A**).

Case 2

A 70-year-old woman with a medical history of depression presented with an approximately 5-year history of mildly itchy cobblestone-like plaques over the posterior and lateral parts of the neck (**Figure 2A**).

In both patients, there were no systemic symptoms. Ophthalmology and cardiovascular examinations

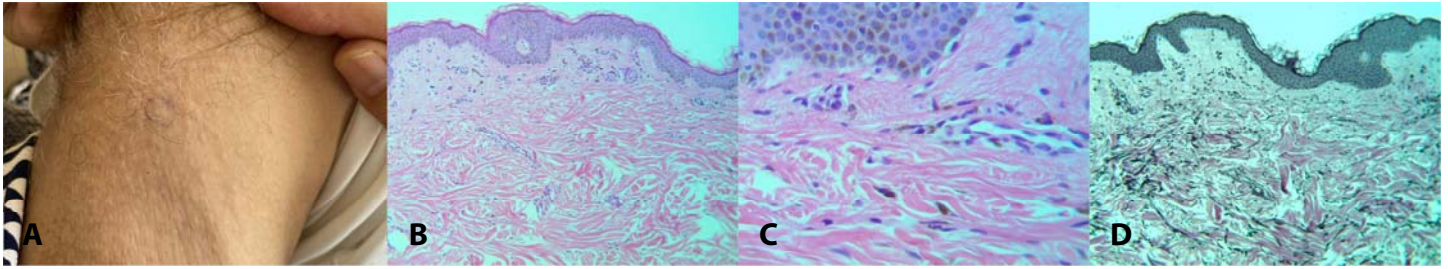


Figure 1. A) Small (2-3mm), flesh-colored, and yellow papules over the posterior and lateral aspects of the neck, with normal overlying skin. **B)** Almost normal-looking skin with subtle changes of slightly thinned epidermis, and very mild fibroblastic proliferation in the papillary dermis and normal reticular dermis. H&E, 10 \times . **C)** Focal sparse pigment deposits in the papillary dermis, very sparse lymphoid cell infiltrates, mild telangiectasia in the papillary dermis. H&E, 40 \times . **D)** Markedly decreased and focally lost elastic fibers in the papillary dermis and normal elastic fibers in the reticular dermis. H&E, 10 \times .

were done and were unremarkable. Also, there was no family history of the same complaint.

Histopathologic findings

For each patient, a four mm skin punch biopsy was taken from a papule. Biopsy sections were done and stained with H&E and also with Verhoff-van Gieson, Masson trichrome, von Kossa, Perl, and Alcian blue stains.

Histopathological findings were similar in both patients. Histological examination with H&E stain in both low (**Figure 1B**, **Figure 2B**) and high-power (**Figure 1C**, **Figure 2C**) views showed: almost normal-looking skin with subtle changes of slightly thinned epidermis, focal sparse pigment deposits in the papillary dermis, very sparse lymphoid cell infiltrate, mild telangiectasia in the papillary dermis, and very mild fibroblastic proliferation in the papillary dermis with a completely normal reticular dermis.

Histological examination with Verhoff-van Gieson and Masson trichrome collagen stain showed

markedly decreased and focally lost elastic fibers in the papillary dermis and normal elastic fibers in the reticular dermis (**Figure 1D**). The biopsy specimen was negative for Perl, von Kossa, and Alcian blue stains.

Based on clinical findings and the histopathologic correlation, both patients were diagnosed with PXE-PDE. Conservative management, including education and reassurance was recommended.

Case Discussion

PXE-PDE is an asymptomatic disorder characterized by deep-seated, soft, non-follicular, tiny (2-4 mm) papules, which range in color from normal skin tones to white-yellow, usually coalescing into plaques, which stud a background of normal skin. Usually they are symmetrically distributed at lateral aspects of the neck, but are also reported at the supraclavicular region, axillary and inframammary folds, flexural forearms, and lower part of the abdomen.

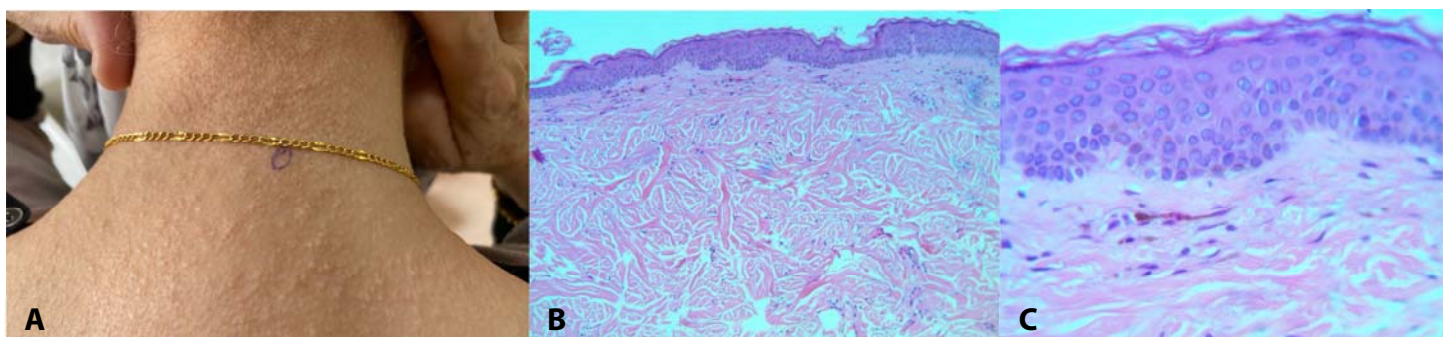


Figure 2. A) Yellowish papules and cobblestone-like plaques over the posterior and lateral parts of the neck. **B)** Mild epidermal thinning, mild fibroblastic proliferation in the papillary dermis, and normal reticular dermis. H&E, 10 \times . **C)** Minimal superficial perivascular lymphoid cell infiltrate. H&E, 40 \times .

The condition slowly develops over a few months or years. Patients mainly present at dermatology clinics with cosmetic concerns [2,4].

This condition usually affects post-menopausal females, mostly after the age of 60 [2,4]. However, there were a few reported cases of early onset [5-7]. In the clinic, using dermoscopy is useful as it usually shows non-follicular papules of white or yellow color, associated with reticular and linear vessels [8].

There are no specific findings by using H&E stain, but we may see slight epidermal thinning and a minimal perivascular lymphocytic infiltrate, plus a few melanophages in the papillary dermis without interface changes. To confirm the diagnosis, elastic fiber special stains like Verhoeff-Van Gieson and orcein stains are needed. The most characteristic change will be a loss or marked decrease in elastic fibers at the papillary dermis with normal or slightly decreased elastic fibers at the reticular dermis. Also, no calcification or fragmentation of elastic fibers is seen, which differs from PXE [2,9].

The pathogenesis is considered multifactorial. Genetic components may play a role in addition to multiple extrinsic and intrinsic factors [2,4]. Ultraviolet light can activate matrix metalloproteinases, which then lead to the destruction of elastic fibers. This is supported by the fact that the lateral aspect of the neck represents the most commonly affected site. However, most cases didn't have a significant history of sun exposure; also, sun-protected areas can be affected. Intrinsic aging

is considered an essential contributing factor because the vast majority of cases were reported after the age of 60 [2,4].

The main condition in the differential diagnosis of PXE-PDE includes inherited PXE. [Table 1](#) represents the important features that should be taken into account for distinguishing the most common diagnoses [2,3,10,11].

Patient reassurance is the most important part of management. No treatment was found to be markedly effective. Topical retinoid 0.05% was used in one patient without improvement [12]. Another patient received two sessions of intralesional triamcinolone acetonide injections with a concentration of 5 mg/ml with no change in the appearance or texture of the skin [13]. Non-ablative fractional resurfacing was used in one patient, with a 50% improvement [7].

Conclusion

PXE-PDE is a chronic benign disorder with no systemic involvement, and patients usually seek medical advice due to cosmetic concerns. Physicians need to recognize it and provide reassurance to patients to avoid excessive unnecessary workups and referrals.

Potential conflicts of interest

The authors declare no conflicts of interests.

References

1. Rongioletti F, Rebora A. Pseudoxanthoma elasticum—like papillary dermal elastolysis. *J Am Acad Dermatol*. 1992;26:648–50. [PMID: 1597557].
2. Atzori L, Ferreli C, Piloni L, Rongioletti F. Pseudoxanthoma elasticum-like papillary dermal elastolysis: A mimicker of genetic pseudoxanthoma elasticum. *Clin Dermatol*. 2021;39:206–10. [PMID: 34272011].
3. Jagdeo J, Ng C, Ronchetti IP, et al. Fibroelastolytic Papulosis. *J Am Acad Dermatol*. 2004;51:958–64. [PMID: 15583589].
4. Rongioletti F, Izakovic J, Romanelli P, Lanuti E, Miteva M. Pseudoxanthoma elasticum-like papillary dermal elastolysis: A large case series with clinicopathological correlation. *J Am Acad Dermatol*. 2012;67:128–35. [PMID: 22018757].
5. Gambichler T, Reininghhaus L, Schaller J. Early-onset pseudoxanthoma elasticum-like papillary dermal elastolysis. *J Eur Acad Dermatol Venereol*. 2014 4;30:448–9. [PMID: 25370919].
6. Byun JY, DO MO, Kim SH, Choi HY, Myung KB, Choi YW. Pseudoxanthoma elasticum-like papillary dermal elastolysis developed in early middle age. *J Dermatol*. 2007;34:709–11. [PMID: 17908144].
7. Foering K, Torbeck RL, Frank MP, Saedi N. Treatment of pseudoxanthoma elasticum-like papillary dermal elastolysis with nonablative fractional resurfacing laser resulting in clinical and histologic improvement in elastin and collagen. *J Cosmet Laser Ther*. 2018;28;20:382–4. [PMID: 28759289].
8. Fukuda H, Mukai H, Otani A, Oharaseki T, Takahashi M. Dermoscopic findings of pseudoxanthoma elasticum-like papillary dermal elastolysis. *Eur J Dermatol*. 2017;27:99–100. [PMID: 28218066].
9. Tajima S, Ohnishi Y, Akagi A, Ishibashi A, Sasaki T. Elastotic change

in the subpapillary and mid-dermal layers in pseudoxanthoma elasticum-like papillary dermal elastolysis. *Br J Dermatol*. 2000;142:586–8. [PMID: 10777279].

10. Nowicka D, Woźniak Z, Maj J, Szepietowski J. White fibrous papulosis of the neck. *Postepy Dermatol Alergol*. 2019;36:775–7. [PMID: 31998010].
11. Wang AR, Lewis K, Lewis M, Robinson-Bostom L. Papillary dermal elastosis: A unique elastic tissue disorder or an unusual manifestation of pseudoxanthoma elasticum-like papillary dermal elastolysis? *J Cutan Pathol*. 2009;36:1010–3. [PMID: 19210582].
12. Rongioletti F, Rebora A. Fibroelastolytic Patterns of Intrinsic Skin Aging: Pseudoxanthoma-elasticum-Like Papillary Dermal Elastolysis and White Fibrous Papulosis of the Neck. *Dermatology*. 1995;191:19–24. [PMID: 8589477].
13. Valbuena V, Assaad D, Yeung J. Pseudoxanthoma Elasticum-Like Papillary Dermal Elastolysis: A Single Case Report. *J Cutan Med Surg*. 2017;21:345-7. [PMID: 28282240].

Table 1. Differential diagnosis of pseudoxanthoma elasticum (PXE)-like papillary dermal elastolysis (PDE).

Disease	Age and gender	Pathophysiology	Clinical features	Histopathology
Pseudoxanthoma elasticum	Second or third decades of life Slight female predominance	Genetic disorder due to mutation of the <i>ABCC6</i> gene	Yellow or white papules that can be discrete to confluent, leading to cobblestone or chicken skin appearance. Distribution: neck, axilla, abdomen, groins, thighs. Systemic involvement, especially ocular and cardiovascular	Fragmentation, clumping, and calcification of the elastic fibers, which appear basophilic due to calcium depositions
Pseudoxanthoma elasticum-like papillary dermal elastolysis	Postmenopausal women	A subtype of fibroelastolytic papulosis. The exact etiology is unknown, but is considered multifactorial; including genetic, extrinsic and, intrinsic factors	Asymptomatic deep-seated, soft, non-follicular, tiny (2-4mm) papules, which range in color from normal skin tones to white-yellow. Distribution: lateral aspects of the neck, but also reported at the supraclavicular region, axillary and inframammary folds, flexural forearms, and lower part of the abdomen.	Loss or marked decrease in elastic fibers at the papillary dermis with normal or slightly decreased elastic fibers at the reticular dermis
White fibrous papulosis of the neck	Elderly No gender predilection	A subtype of fibroelastolytic papulosis. The exact etiology is unknown but is believed to be related to intrinsic aging, and environmental factors	Small (2-3 mm) pale, whitish, discrete, non-confluent papules. Distribution: nape of the neck and less at the lateral aspects of the neck.	Loss of the fine elastic plexus in the papillary dermis with focal fibrosis and thickening of collagen fibers in the upper portion of the reticular dermis.
Papillary dermal elastosis	Young women	Unknown	Asymptomatic white or yellow papules Distribution: the neck and the upper back	Focal clumped granular elastic fibers in the papillary dermis are alternating with focal areas of decreased concentrations of normal-looking elastic fibers. The reticular dermis looks totally normal
Mid-dermal elastolysis	Young women (type 1 and 2) Elderly men (type 3)	Not well understood. Some hypotheses include copper deficiency or abnormal metabolism, low activity of lysyl oxidase, anti-elastin antibodies formation, and high elastase activity.	Three different clinical variants: Type 1: Patches of well-circumscribed fine wrinkles distributed at the trunk and proximal part of the extremities. Type 2: Perifollicular papular protrusions located at the lateral aspects of the neck Type 3: This is rare and manifests as persistent wrinkling and reticular erythema	Loss of mid-dermal elastic fibers. Also, lymphohistiocytic infiltration with phagocytosis of elastic fibers by macrophages in the dermis might be seen