

UC Davis

Dermatology Online Journal

Title

Trichofolliculoma: a rare variant of hair follicle hamartoma

Permalink

<https://escholarship.org/uc/item/7s98d8vg>

Journal

Dermatology Online Journal, 19(8)

Authors

Gokalp, Hilal
Gurer, Mehmet Ali
Alan, Saadet

Publication Date

2013

DOI

10.5070/D3198019264

Copyright Information

Copyright 2013 by the author(s). This work is made available under the terms of a Creative Commons Attribution-NonCommercial-NoDerivatives License, available at <https://creativecommons.org/licenses/by-nc-nd/4.0/>

Peer reviewed

Case Presentation

Trichofolliculoma: a rare variant of hair follicle hamartoma

¹Hilal Gokalp MD, ²Mehmet Ali Gurer Professor, ³Saadet Alan MD

Dermatology Online Journal 19 (8): 7

¹Government Hospital of Malatya, Department of Dermatology, Malatya, Turkey

²Gazi University Faculty of Medicine, Department of Dermatology, Ankara, Turkey

³Government Hospital of Malatya, Department of Pathology, Malatya, Turkey

Correspondence:

Hilal Gokalp MD
Government Hospital of Malatya
Department of Dermatology
Malatya, Turkey
hilalgklp@gmail.com

Abstract

Trichofolliculoma is a rare hair follicle hamartoma, which is often regarded as a hair follicle tumor. Mostly, it presents as a papule or nodule, involving the skin of the face and scalp area. A central, dilated keratin plugged ostium with vellus hair(s) is often present. We report a 19-year-old woman with typical clinical and histopathological findings of trichofolliculoma.

Case synopsis

A 19-year-old woman presented with a skin-colored nodule with vellus hair on her scalp region. The lesion first appeared ten years earlier and the vellus hair has been growing slowly over time. Physical examination revealed a 0.5x0.5 cm sized skin-colored nodule with a central pore and a wool-like tuft of hairs on the vertex (Figure 1). Following informed consent, she underwent total excision of the nodule on her scalp. Histological examination demonstrated ectatic cystic follicles filled with keratin around a large number of small follicles in different stages of maturation (Figure 2). The clinical and histopathological diagnosis of trichofolliculoma was made. After excision, no complication was observed. However, recurrence at the primary site was seen 3 months later.

Discussion

Trichofolliculoma is a rare hamartoma, which presents mainly in adults as a small, solitary papule or nodule [1]. Although the precise etiology of trichofolliculoma is uncertain, it is believed to represent abortive differentiation of pluripotent skin cells toward hair follicles [2]. However, there are some case reports that demonstrate lesions on the neck, intranasal mucosa, external auditory canal, and vulvar area; it commonly involves the face and scalp [3-7]. The vast majority of lesions are 0.2 to 0.5 cm-sized papules or nodules. Owing to its lack of distinctive clinical features, the tumors are often misdiagnosed as other disorders such as milium, keratoacanthoma, molluscum contagiosum, trichoepithelioma, syringoma, dermal nevus, epidermoid cyst, sebaceous hyperplasia, and basal cell carcinoma [3,6,7]. Sometimes, a central follicular ostium or punctum may be identifiable and a small wool-like tuft of hairs may protrude from the surface, as was seen in the present case [2]. A tuft of white vellus hairs gives a distinctive morphological appearance to trichofolliculoma. On histopathologic examination, there is a dilated central follicle commonly filled with cornified cells and sometimes containing vellus hairs [8]. Numerous, smaller, secondary follicles that bud from the wall of the central follicle in a radial fashion are observed as well [4]. A study of cytokeratin expression in trichofolliculoma has revealed that trichofolliculoma mainly differentiates toward the hair bulge and the outer root sheath in the isthmus [3]. Misago et al. revealed that cytokeratin (CK) 15 expression was upregulated in the basal cells from the primary cystic structures to secondary follicles without expression of CK19 [8]. Trichofolliculoma is a benign condition, but malignant transformation with perineural invasion has been reported in a single case report [9].

However, surgical excision may be the treatment of choice, there is no need for treatment. The prognosis is excellent, although recurrence can rarely occur at the primary site [7].

In conclusion, trichofolliculoma is a rare hair follicle hamartoma and a tuft of hair protruding from the center makes it even clinically diagnosable as was seen in the present case.

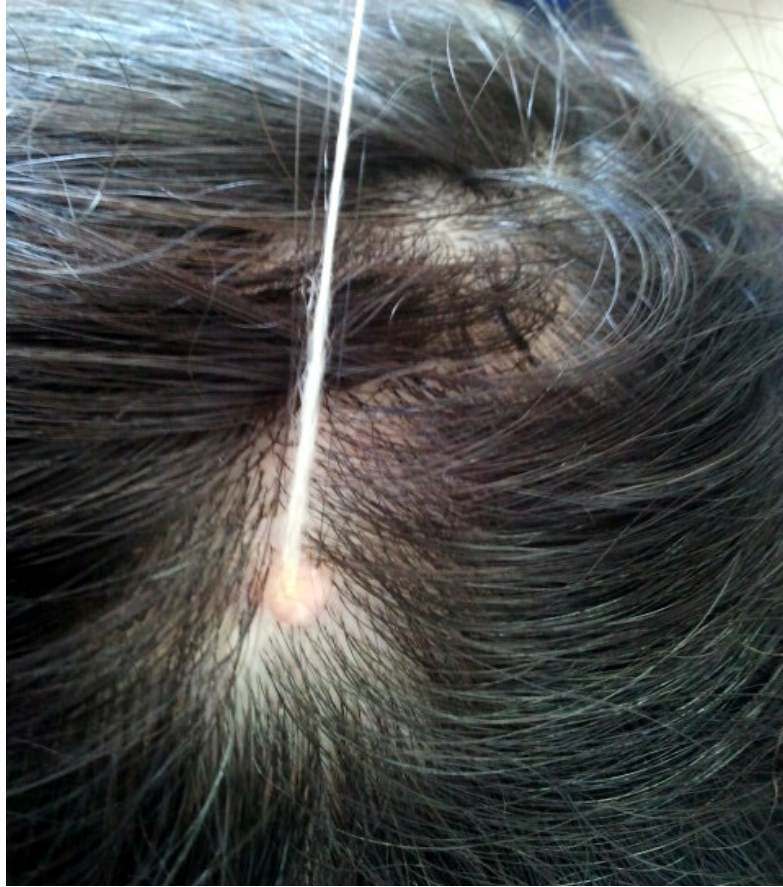

Figure 1: Skin-colored nodule with a central pore and wool-like tuft of hairs on the vertex

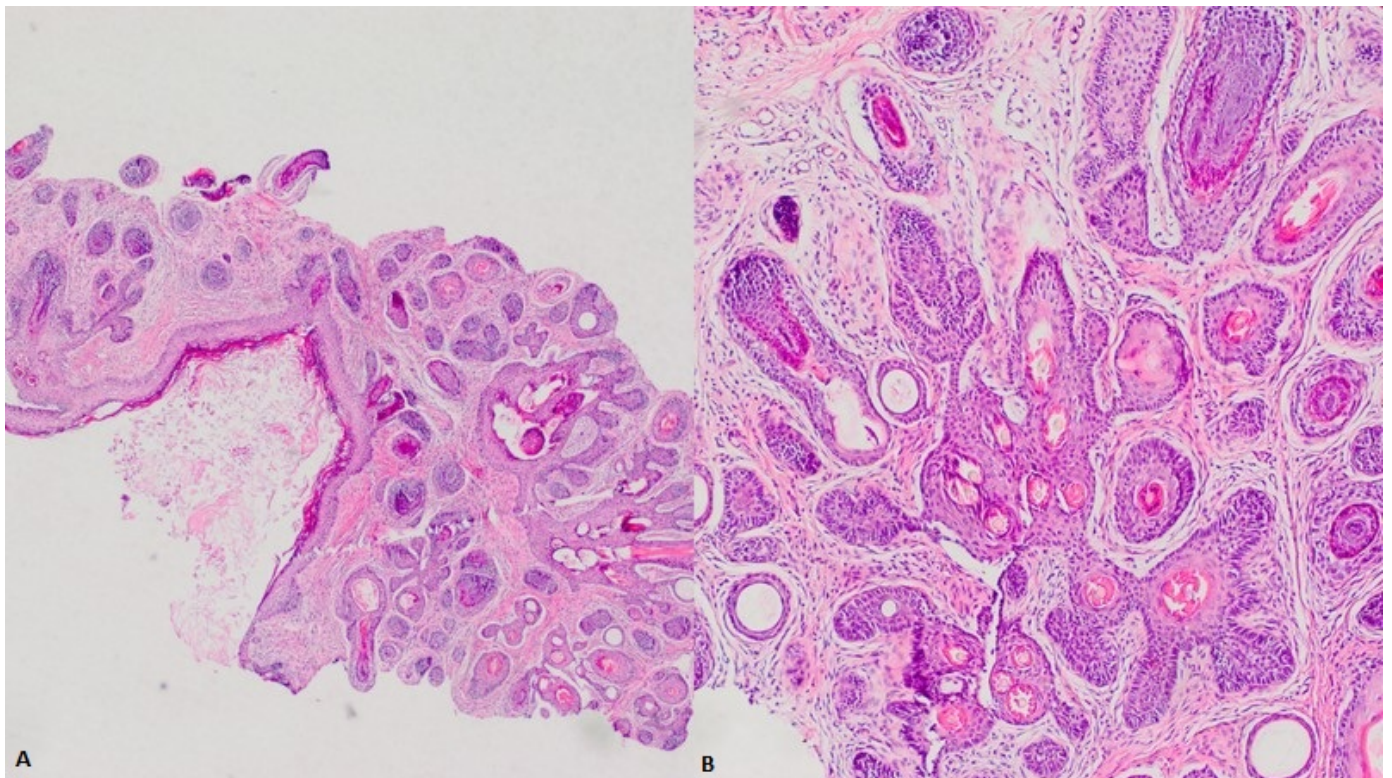


Figure 2: Histologic findings. A) Ectatic cystic follicles filled with keratin around a large number of small follicles in different stages of maturation (H&Ex40 magnification). B) At higher magnification the morphology of small follicles (H&Ex100 magnification) is shown.

References

1. Kurokawa I, Kusumoto K, Sensaki H, et al. Trichofolliculoma: Case report with immunohistochemical study of cytokeratins. *Br J Dermatol* 2003;148(3):597-8. PMID: 12653763 [PubMed]
2. Schulz T, Hartschuh W. The trichofolliculoma undergoes changes corresponding to the regressing normal hair follicle in its cycle. *J Cutan Pathol* 1998;25(7):341-53. PMID: 9765019 [PubMed]
3. Gür G, Yalçın B, Tamer E, et al. Trichofolliculoma: An Uncommon Hair Follicle Hamartoma. *Turkiye Klinikleri J Dermatol* 2006;16(2):69-71
4. Arias P, Gutierrez O, Hasson Nisis A, et al. [Intranasal trichofolliculoma]. *Med Cutan Ibero Lat Am* 1990;18(3):159-61. PMID: 2263091 [PubMed]
5. O'Mahony JJ. Trichofolliculoma of the external auditory meatus. Report of a case and a review of the literature. *J Laryngol Otol* 1981;95(6):623-5. PMID: 7252340 [PubMed]
6. Peterdy GA, Huettner PC, Rajaram V, et al. Trichofolliculoma of the vulva associated with vulvar intraepithelial neoplasia: Report of three cases and review of literature. *Int J Gynecol Pathol* 2002;21(3):224-30. PMID: 12068167 [PubMed]
7. Ghosh SK, Bandyopadhyay D, Barma KD. Perifollicular nodule on the face of a young man. *Indian J Dermatol Venereol Leprol* 2011;77(4):531-3. PMID: 21727710 [PubMed]
8. Misago N, Kimura T, Toda S, et al. A reevaluation of trichofolliculoma: the histopathological and immunohistochemical features. *Am J Dermatopathol* 2010;32(1):35-43. PMID: 19730084 [PubMed]
9. Stern JB, Stout DA. Trichofolliculoma showing perineural invasion. Trichofolliculocarcinoma? *Arch Dermatol* 1979;115(8):1003-4. PMID: 464613 [PubMed]