

**UCLA**

**Proceedings of UCLA Health**

**Title**

Ramsay Hunt Syndrome with a Cranial Nerve Polyneuropathy

**Permalink**

<https://escholarship.org/uc/item/7pw8q3kr>

**Journal**

Proceedings of UCLA Health, 21(1)

**Authors**

Sellars, MacLean C.

Pessegueiro, Antonio

**Publication Date**

2017-06-06

## CLINICAL VIGNETTE

# Ramsay Hunt Syndrome with a Cranial Nerve Polyneuropathy

MacLean C. Sellars, M.D., Ph.D., and Antonio M. Pessegueiro, M.D.

### Introduction

Ramsay Hunt Syndrome is a cranial nerve (CN) neuropathy associated with varicella-zoster virus (VZV) reactivation in the geniculate ganglion of CN VII. This results in a classic triad of ipsilateral facial palsy, otalgia, and vesicular lesions in the auditory canal.<sup>1</sup>

### Case Presentation

A 61-year-old male with a history of central nervous system (CNS) lymphoma, status post autologous stem cell transplant, oral herpes simplex virus (HSV) infection, and adrenal insufficiency presented with one week of throat and mouth pain. Three days prior to admission, he noted pain and decreased hearing in the left ear. Two days prior to admission, he developed difficulty walking, lurching and falling to the left. The day prior to admission he noted dysuria, increasing fatigue, and dysphagia. Vital signs on admission were notable for fever and tachycardia. Physical examination revealed 1-2 mm vesicles and ulcerations on an erythematous base on the left soft palate (Figure 1A), dysarthria, and moderate left facial droop. Neurological examination was otherwise unremarkable and examination of the ears revealed only cerumen. MRI brain was negative for acute processes or findings suggestive of CNS lymphoma. Urinalysis revealed pyuria and bacteria. He was started on broad-spectrum antibiotics for a presumed urinary tract infection and valacyclovir for presumed HSV re-activation and possible Bell's Palsy.

On hospital day 3, the patient developed significantly diminished hearing on the left, altered taste on the left side of his tongue, worsening facial droop (Figure 1B), and new crusted lesions on the left upper lip (Figure 1C). Otalgia and dysphagia persisted. Audiogram revealed profound hearing loss on the left. MRI of the intra-auditory canal demonstrated enhancement of the left CN VII consistent with inflammation/infection (Figure 2); lymphomatous infiltration secondary to CNS lymphoma was not excluded. A modified barium swallow study (MBSS) showed reduced pharyngeal sensation, laryngeal elevation, tongue base contraction, and tongue leftward range of motion. These were new compared to MBSS 5 months prior.

With these findings, Ramsay Hunt Syndrome was considered and the patient was transitioned to IV acyclovir and started on daily prednisone 60mg based on established guidelines.<sup>2-4</sup> Lumbar puncture (LP) on hospital day 5 revealed pleocytosis (112 WBC/cm<sup>2</sup>, 83% lymphocytes) and VZV PCR testing of

the CSF was positive. CSF review by pathology did not suggest lymphoma. HSV PCR testing of blood, CSF, and his oral lesions were negative. While VZV PCR testing of blood and one of his oral lesions was negative, the clinical picture and CSF studies were most consistent with VZV reactivation and Ramsay Hunt Syndrome. The patient was treated with prednisone for 7 days and IV acyclovir for 10 days. Repeat LP on hospital day 15 (after 10 days of acyclovir) demonstrated decreasing pleocytosis and a negative VZV PCR.

Six months after discharge, the patient reported a persistent hearing deficit. His dysphagia and dysarthria improved, and his facial palsy largely resolved.

### Discussion

Initially described in 1910, Ramsay Hunt Syndrome results from VZV reactivation in the geniculate nucleus of the facial nerve.<sup>1,5</sup> CN VII palsy is the cardinal symptom, characterized by weakness of the upper and lower face and inability to close the eye. CN VII also supplies sensory innervation to the auditory canal, which underlies the otalgia and auditory canal vesicular VZV lesions that complete the classic triad. Our patient exhibited facial nerve palsy and otalgia.

Among the less appreciated signs and symptoms of Ramsay Hunt Syndrome are complications of the other sensory fibers of CN VII. These include somatic sensory to the posterior ear/mastoid process, special sensory innervation to the anterior two-thirds of the tongue via the chorda tympani, and vestigial somatic sensory innervation of the soft palate.<sup>5</sup> Involvement of these fibers can cause deficiencies in taste, as well as vesicular lesions behind the ear, on the tongue, and on the soft palate. In our case, vestigial somatic sensory fibers appear to have been involved, resulting in herpetic lesions on the soft palate.

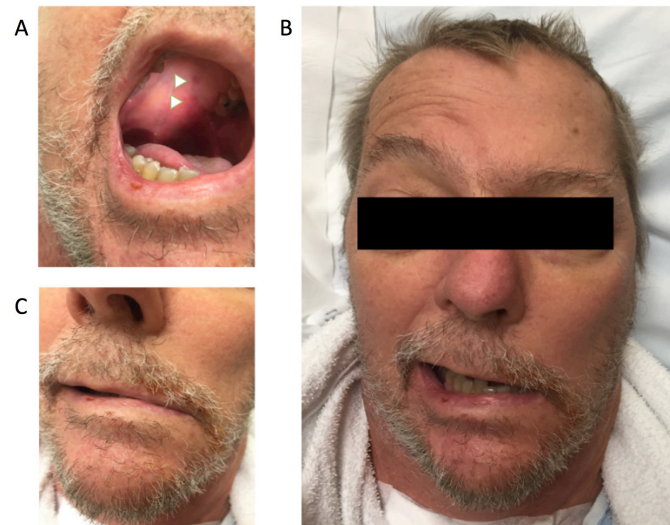Ramsay Hunt Syndrome sometimes presents as a cranial nerve polyneuropathy. CN VIII is the second most commonly affected cranial nerve, likely due to inflammation spreading from the adjacent CN VII. Complaints include hearing loss (as in this patient), as well as nausea, vomiting, and vertigo. Other affected nerves include CN IX-XII (consistent with this patient's dysphagia, dysarthria, and tongue weakness). At least two mechanisms may underlie the involvement of these cranial nerves in Ramsay Hunt Syndrome associated polyneuropathy: (a) spreading of inflammation to contiguous ganglia;<sup>1</sup> and (b)

ischemic neuropathy due to VZV infection of the endothelia of common small blood vessels.<sup>6</sup>

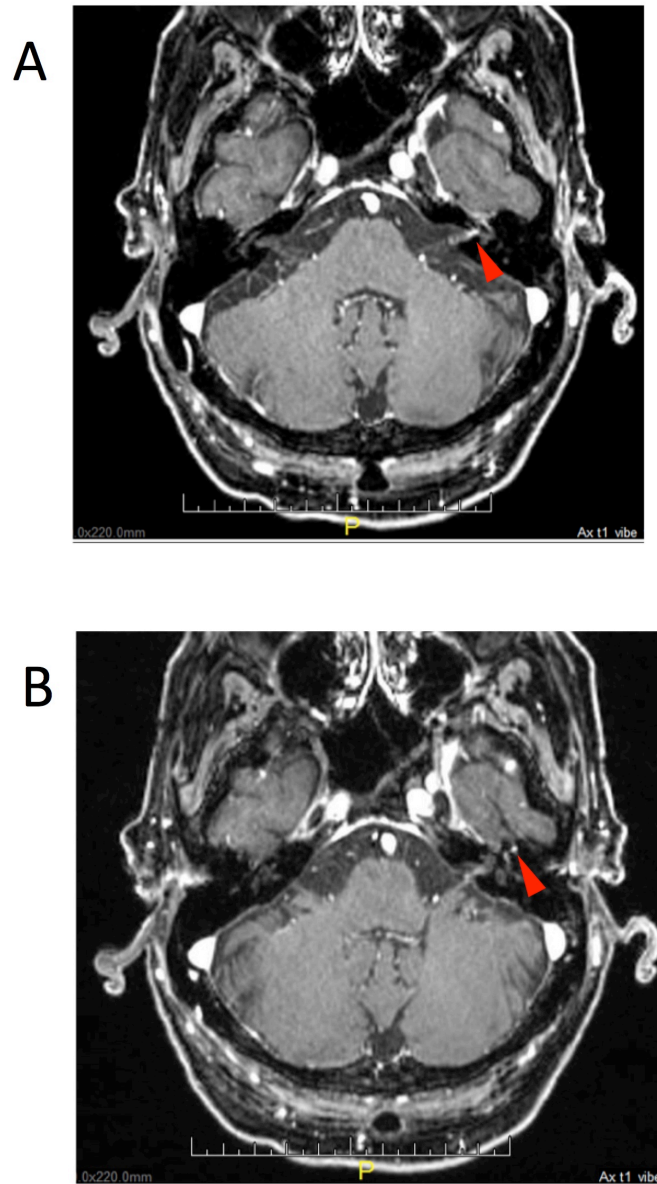
Finally, our patient exhibited some atypical symptoms: perioral lesions in a V2 distribution, poor balance (cerebellum), and confusion. Considering he was hypogamma-globulinemic during admission, we speculate that hematogenous and/or CSF spread may account for these symptoms, as CSF was positive for VZV.

Herpes zoster is a dangerous complication of Stem Cell Transplantation. Prior to acyclovir prophylaxis and treatment, up to half of transplant patients would suffer outbreaks within 6 months with significant associated mortality.<sup>7</sup> Today, transplant patients routinely receive early acyclovir prophylaxis and allogenic stem cell transplant recipients receive it for up to a year following transplant.<sup>8</sup> Our patient received prophylaxis for only 3 weeks following transplant. The zoster vaccine is a live-attenuated vaccine and is therefore contraindicated in immunosuppressed patients. A recombinant vaccine has recently been shown effective in older adults<sup>9</sup> and, as our patient highlights, this may be an important advance.

**Figure 1:** Signs of Ramsay Hunt Syndrome. (A). Soft palate ulcerations (white arrowheads) on hospital day 2, which had evolved from vesicular lesions on presentation. (B). Left cranial nerve VII palsy as evidenced by upper and lower facial droop. (C). Ulcerations and crusting on the upper lip noted on hospital day 3.



**Figure 2:** MR intra-auditory canals. On T2 imaging, increased enhancement (indicated by red arrowheads) was noted in the left CN VII (A), as well as the left geniculate ganglion (B).



## REFERENCES

1. **Sweeney CJ, Gilden DH.** Ramsay Hunt syndrome. *J Neurol Neurosurg Psychiatry.* 2001 Aug;71(2):149-54. Review. PubMed PMID: 11459884; PubMed Central PMCID:PMC1737523.
2. **Baugh RF, Basura GJ, Ishii LE, Schwartz SR, Drumheller CM, Burkholder R, Deckard NA, Dawson C, Driscoll C, Gillespie MB, Gurgel RK, Halperin J, Khalid AN, Kumar KA, Micco A, Munsell D, Rosenbaum S, Vaughan W.** Clinical practice guideline: Bell's palsy. *Otolaryngol Head Neck Surg.* 2013 Nov;149(3 Suppl):S1-27. doi: 10.1177/0194599813505967. PubMed PMID: 24189771.
3. **Peitersen E.** Bell's palsy: the spontaneous course of 2,500 peripheral facial nerve palsies of different etiologies. *Acta Otolaryngol Suppl.* 2002;(549):4-30. Review. PubMed PMID: 12482166.

4. **Kinishi M, Amatsu M, Mohri M, Saito M, Hasegawa T, Hasegawa S.** Acyclovir improves recovery rate of facial nerve palsy in Ramsay Hunt syndrome. *Auris Nasus Larynx*. 2001 Aug;28(3):223-6. PubMed PMID: 11489365.
5. **Hunt JR.** The sensory field of the facial nerve: a further contribution to the symptomatology of the geniculate ganglion. *Brain: A Journal of Neurology*. 1915;38:418-46.
6. **Lapresle J, Lasjaunias P.** Cranial nerve ischaemic arterial syndromes. A review. *Brain*. 1986 Feb;109 ( Pt 1):207-16. PubMed PMID: 3942855.
7. **Atkinson K, Meyers JD, Storb R, Prentice RL, Thomas ED.** Varicella-zoster virus infection after marrow transplantation for aplastic anemia or leukemia. *Transplantation*. 1980;29(1):47-50. PubMed PMID: 6245486.
8. **Styczynski J, Reusser P, Einsele H, de la Camara R, Cordonnier C, Ward KN, Ljungman P, Engelhard D; Second European Conference on Infections in Leukemia.** Management of HSV, VZV and EBV infections in patients with hematological malignancies and after SCT: guidelines from the Second European Conference on Infections in Leukemia. *Bone Marrow Transplant*. 2009 May;43(10):757-70. doi:10.1038/bmt.2008.386. Epub 2008 Dec 1. PubMed PMID: 19043458.
9. **Lal H, Cunningham AL, Godeaux O, Chlibek R, Diez-Domingo J, Hwang SJ, Levin MJ, McElhaney JE, Poder A, Puig-Barberà J, Vesikari T, Watanabe D, Weckx L, Zahaf T, Heineman TC; ZOE-50 Study Group.** Efficacy of an adjuvanted herpes zoster subunit vaccine in older adults. *N Engl J Med*. 2015 May 28;372(22):2087-96. doi: 10.1056/NEJMoa1501184. Epub 2015 Apr 28. PubMed PMID: 25916341.

Submitted June 6, 2017