

# UCSF

## UC San Francisco Previously Published Works

### Title

Onyx embolization of an enlarging arterioportal pancreatic AVM using a balloon-occlusion microcatheter

### Permalink

<https://escholarship.org/uc/item/7pq8n0ms>

### Journal

Diagnostic and Interventional Radiology, 27(3)

### ISSN

0998-433X

### Authors

Kohlbrenner, Ryan

Division of Vascular and Interventional Radiology, Department of Radiology and Biomedical Imaging

Fidelman, Nicholas

et al.

### Publication Date

2021-05-01

### DOI

10.5152/dir.2020.20416

Peer reviewed

## Onyx embolization of an enlarging arterioportal pancreatic AVM using a balloon-occlusion microcatheter

Ryan Kohlbrenner <sup>ID</sup>  
 Nicholas Fidelman <sup>ID</sup>  
 Maureen P. Kohi <sup>ID</sup>  
 Vishal Kumar <sup>ID</sup>  
 K. Pallav Kolli <sup>ID</sup>

From the Division of Vascular and Interventional Radiology (R.K. ✉ [ryan.kohlbrenner@ucsf.edu](mailto:ryan.kohlbrenner@ucsf.edu), N.F., V.K., P.K., M.P.K.), Department of Radiology and Biomedical Imaging, University of California, San Francisco, USA.

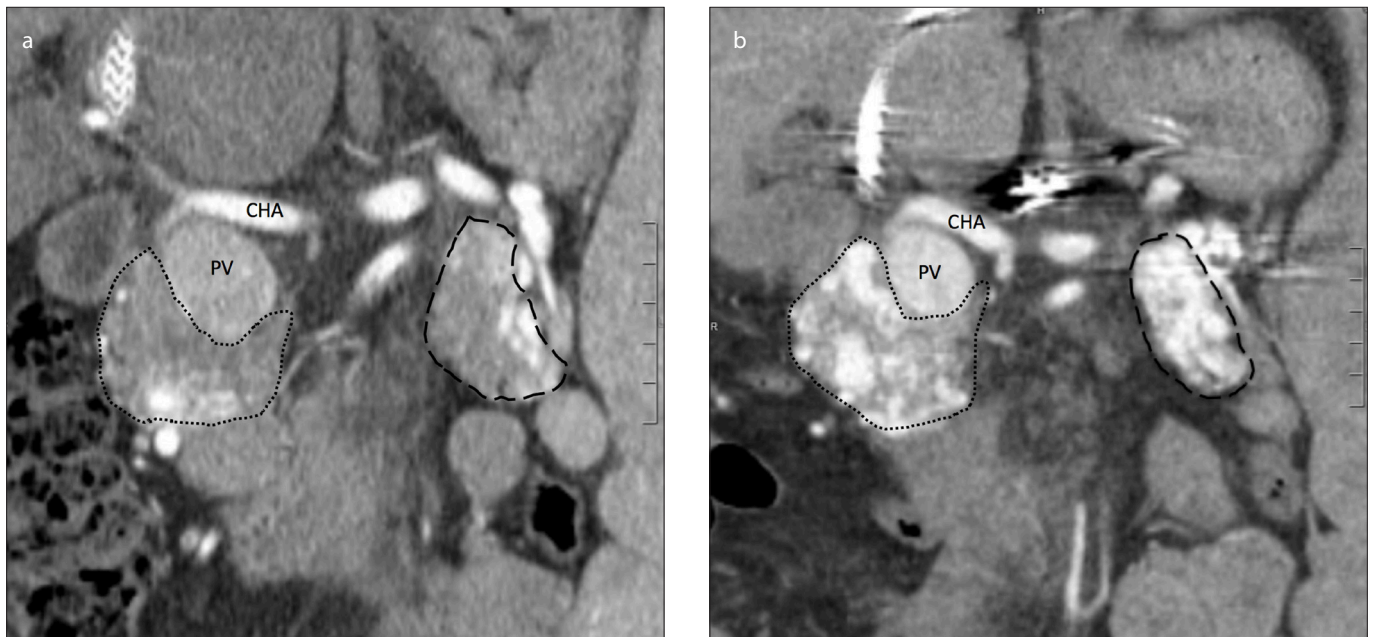
Dear Editor,

Pancreatic arteriovenous malformations (AVMs) are rare lesions of the gastrointestinal system, with approximately 100 reported in the medical literature to date. The case presented herein describes a patient with an arterioportal AVM of the pancreas that, after portal decompression, progressively enlarged over an 8-year period. A compliant balloon-occlusion microcatheter was used to embolize the lesion to control the recurrent portal hypertension and bleeding that ensued.

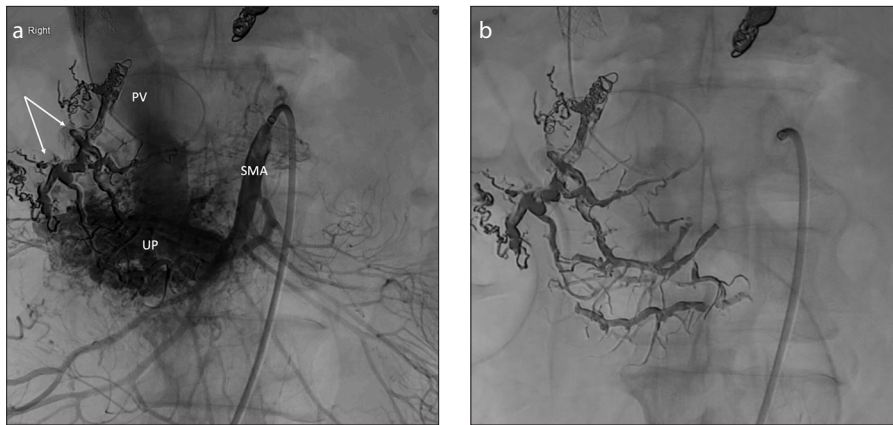
This case study was IRB-exempt at the reporting institution. The patient is a 57-year-old Hispanic male with hepatitis C cirrhosis and portal hypertension, who initially presented to an outside institution at age 49 with gastroesophageal variceal bleeding, requiring urgent transjugular intrahepatic portosys-

temic shunt (TIPS) placement in the setting of a small, unrecognized pancreatic AVM. Due to a delay in diagnosis, multiple endoscopic and portal venous interventions were performed in the years that followed to control the patient’s persistent portal hypertension. The patient was subsequently referred to the authors’ institution for liver transplant evaluation. A multiphase CT of the abdomen in the setting of a gastrointestinal (GI) bleed performed 8 years after TIPS demonstrated arterial phase opacification of the portal vein through a large Yakes type IV pancreatic AVM involving the entire gland. When compared with the scan from 8 years prior using similar technique, the lesion had shown significant enlargement (Fig. 1).

Embolotherapy was thought to be the appropriate treatment for this high-flow lesion after multidisciplinary discussion. The potential benefits were two-fold: to reduce the risk of further variceal bleeding by decreasing arterioportal shunting; and to prevent direct lesional bleeding into the duodenum, for which there was suspicion endoscopically. A 6 F Flexor sheath (Cook Medical) was first advanced into the common hepatic artery, through which a 2.4 F Progreat microcatheter (Terumo) was placed. The proximal right gastroepiploic artery was accessed and coil embolized to prevent flow of liquid embolic into the vessel. Ethylene vinyl alcohol copolymer (EVOH) (Onyx 18, Medtronic) was then infused into the anterior and posterior superior pancreaticoduodenal and gastroduodenal arteries through 2.1 F Scepter C compliant balloon-occlusion microcatheters (Microvention). Sequential, selective catheterizations were used to ensure distal penetration of the embolic. A similar technique was used to embolize the greater pancreatic artery and, through the superior mesenteric artery, the inferior pancreaticoduodenal ar-



**Figure 1.** a, b. Initial post-TIPS arterial phase coronal CT scan (a) demonstrates small abnormal draining veins in the periphery of the pancreatic head/uncinate (short-dashed line) and the pancreatic tail (long-dashed line). Arterial phase coronal CT scan obtained 8 years later (b) shows replacement of the pancreatic head/uncinate and tail by feeding arteries, hypervascular parenchyma, and early-draining veins. CHA, common hepatic artery; PV, portal vein.



**Figure 2. a, b.** Image (a) from superior mesenteric artery (SMA) angiogram demonstrates multiple inferior pancreaticoduodenal branches supplying the component of the AVM within the uncinus process (UP). Rapid filling of the portal vein (PV) is noted, which has been accessed with a guidewire through the existing TIPS. EVOH and coils from the initial (celiac side) embolization are present (arrows). Single spot image (b) shows midline upper abdomen after extensive embolization of the pancreaticoduodenal arcades with EVOH.

cares (Fig. 2). The portosystemic gradient decreased from 20 mmHg (prior to embolization) to 16 mmHg. The patient required no subsequent blood transfusions and demonstrated no evidence of bowel ischemia or pancreatitis prior to his discharge 3 days post-embolization.

Endoscopy performed 6 months post-embolization in the setting of recurrent GI bleeding demonstrated a periampullary ulcer, small gastric varices, and small esophageal varices. As the etiology of the rebleeding could not be discerned, empiric embolization of additional feeding arteries was subsequently performed to further reduce arterioportal shunting, in conjunction with endoscopic sclerosis of several gastric varices. The patient was initiated on monthly octreotide injections

9 months after the initial embolization, and no further GI bleeding episodes were reported at 18-month follow-up.

While many pancreatic AVMs are thought to be congenital, these rare lesions may also develop in the setting of a prior injury, such as pancreatitis. Bleeding is the most common presenting symptom, and surgery may be pursued for appropriate candidates (1). Few cases treated with liquid embolics have been reported (2, 3). Unique to this report is the growth of the pancreatic AVM over several years in the setting of a TIPS. As the favorable hemodynamics after TIPS could facilitate additional shunting through an arterioportal lesion, an AVM should be considered a rare cause of recurrent or persistent portal hypertension in the setting of prior portal

decompression. Embolization with liquid EVOH, which may be more efficacious in high-flow lesions than n-butyl cyanoacrylate (4), enabled distal occlusion of the feeding vessels. In addition, administration through a balloon-occlusion microcatheter facilitated controlled, expeditious delivery of the agent into the lesion, preventing the embolic from escaping into the portal circulation.

#### Conflict of interest disclosure

The authors declared no conflicts of interest.

#### References

1. Chou SC, Shyr YM, Wang SE. Pancreatic arteriovenous malformation. *J Gastrointest Surg* 2013; 17:1240–1246. [\[Crossref\]](#)
2. Cassinotto C, Lapuyade B. Pancreatic arteriovenous malformation embolization with onyx. *J Vasc Interv Radiol* 2015; 26:442–444. [\[Crossref\]](#)
3. Grasso RF, Cazzato RL, Luppi G, et al. Pancreatic arteriovenous malformation involving the duodenum embolized with ethylene-vinyl alcohol copolymer (Onyx). *Cardiovasc Intervent Radiol* 2012; 35:958–962. [\[Crossref\]](#)
4. Elsenousi A, Aletich VA, Alaraj A. Neurological outcomes and cure rates of embolization of brain arteriovenous malformations with n-butyl cyanoacrylate or Onyx: a meta-analysis. *J Neurointerv Surg* 2016; 8:265–272. [\[Crossref\]](#)

Received 3 June 2020; revision requested 29 June 2020; last revision received 27 July 2020; accepted 10 August 2020.

Published online 28 September 2020.

DOI 10.5152/dir.2020.20416

You may cite this article as: Kohlbrenner R, Fidelman N, Kohi MP, Kumar V, Kolli KP. Onyx embolization of an enlarging arterioportal pancreatic AVM using a balloon-occlusion microcatheter. *Diagn Interv Radiol* 2021; 27:458–459