

UC Irvine

UC Irvine Previously Published Works

Title

Alopecia and Associated Toxic Agents: A Systematic Review

Permalink

<https://escholarship.org/uc/item/7p86g2pk>

Journal

Skin Appendage Disorders, 4(4)

ISSN

2296-9195

Authors

Yu, Vicky
Juhász, Margit
Chiang, Audris
[et al.](#)

Publication Date

2018

DOI

10.1159/000485749

Peer reviewed

Alopecia and Associated Toxic Agents: A Systematic Review

Vicky Yu^a Margit Juhász^b Audris Chiang^b Natasha Atanaskova Mesinkovska^b

^aUniversity of Cincinnati, College of Medicine, Cincinnati, OH, USA; ^bUniversity of California, Irvine, Department of Dermatology, Irvine, CA, USA

Keywords

Hair loss · Alopecia · Toxin/toxicity · Poison/poisoning

Abstract

Importance/Objective: There are a number of toxic agents that can cause alopecia. In this review we summarize the known substances that cause alopecia as one of the clinical signs of overdose or toxicity. **Evidence Review:** A search was conducted using PubMed, EMBASE, and Cochrane for studies describing hair loss of any type as a result of exposure to or ingestion of a toxic agent. The search yielded 856 articles, with 47 studies included in this review. **Findings:** Agents with the strongest evidence of association to alopecia include thallium, mercury, selenium, and colchicine. Agents with described incidents include boric acid, arsenic, vitamin A, botulinum toxin, *Podostroma cornu-damae*, and the synthetic opioid MT-45. **Conclusions and Relevance:** Numerous toxic agents have been implicated in alopecia, and the strength of evidence behind each agent varies. Toxic levels of thallium and colchicine have long been established to cause alopecia, as compared to agents such as botulinum toxin A and synthetic recreational drugs which have less literature describing their links to alopecia and will need further investigation to characterize their relationships to hair

loss. Knowledge of typical presentations of hair loss will aid in the development of a differential diagnosis for patients presenting with alopecia.

© 2018 S. Karger AG, Basel

Introduction

Historically, the literature linking the overdose of certain toxins to hair loss has been heavily focused on heavy metals. In the last decade, the literature still discusses heavy metals, such as thallium and mercury, but now also includes a number of non-metal toxins that are also associated with alopecia. These toxins range from dietary supplements, such as selenium, to prescription drugs, such as colchicine, to fungi, such as *Podostroma cornu-damae*. In the first review of its kind, we evaluate the evidence behind toxic causes of alopecia and summarize common presentations, as well as associated signs and symptoms of toxicity. Recognition of toxic agents as a possible cause of alopecia, awareness of onset and characteristic patterns of hair loss, and familiarity with common clinical signs will aid in a clinician's differential diagnosis.

Alopecia is the loss of hair from areas of the body where hair would normally grow, which may occur via

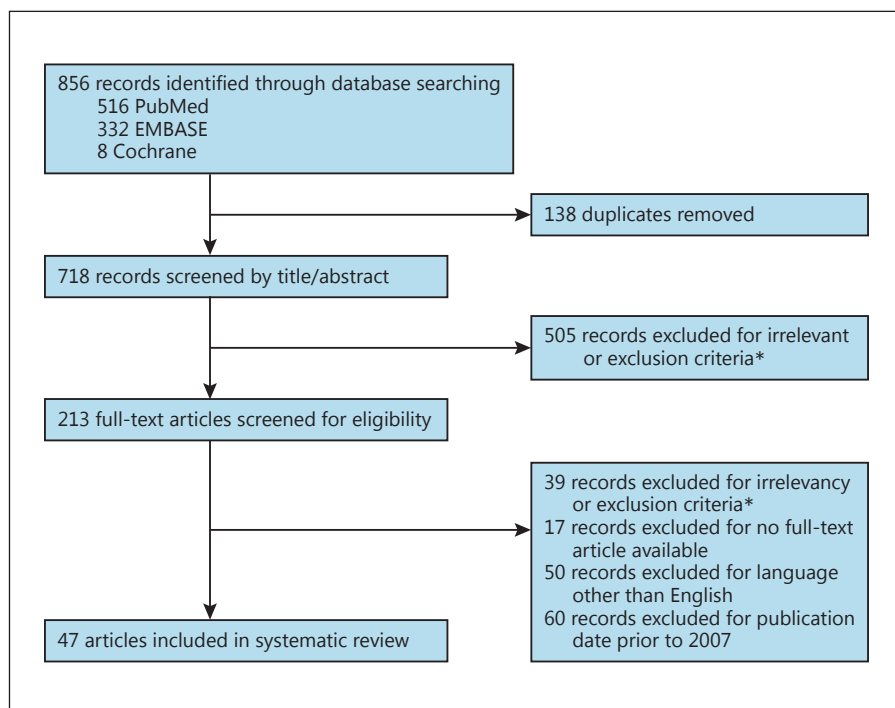


Fig. 1. An outline of the PRISMA guidelines used to conduct this systematic review. * Exclusion criteria included: animal studies, chemotherapies, arthropod-induced alopecia, and exclusive discussion of treatment methods of overdose or poisoning.

natural processes or be an indicator of pathology. Exposure to toxins is one of many etiological mechanisms that may cause alopecia, particularly in acute-onset alopecia associated with generalized symptoms, such as nausea, vomiting, diarrhea, fatigue, as well as skin and nail changes. This review defines alopecia as hair loss from any part of the scalp, face, or body, including madarosis (loss of eyebrows or eyelashes).

There are a number of compounds identified that cause alopecia when taken at toxic levels, either accidentally or intentionally. These agents include heavy metals, such as thallium and mercury, for which industrial and mechanical workers are at most risk for exposure, dietary supplements, such as vitamin A, and insecticides, such as boric acid. Other reported causes of alopecia include colchicine, arsenic, selenium, botulinum toxin, *Podostroma cornu-damae*, and the synthetic opioid MT-45. This review summarizes published data primarily in the form of reports or series on patients presenting with any form of hair loss following a confirmed ingestion or exposure to a toxic agent.

Methods/Literature Search

This systematic review was conducted according to PRISMA guidelines (Fig. 1). The entry “(alopecia OR hair loss) AND (toxin OR poison*)” was used to search PubMed, EMBASE, and Cochrane. Eligible articles were screened by title and abstract after re-

moval of duplicates. Articles were included if they described any form of hair loss following exposure to a toxic agent. The remaining articles were then read in full text to confirm eligibility. Exclusion criteria for articles included: no full text electronically available, publication in a language other than English, publication prior to 2007, animal studies, chemotherapies, arthropod-induced alopecia, and exclusive discussion of treatment methods of overdose or poisoning.

Data from included articles were extracted and recorded on a standardized electronic data collection sheet. Using a modified Oxford Centre for Evidence-Based Medicine Scale (defined as level 1, systematic reviews with or without meta-analysis; level 2, prospective comparative cohort trials; level 3, case-control studies and retrospective cohort studies; level 4, case series and cross-sectional studies; level 5, case reports and opinions of respected authorities), the quality of articles was rated after joint article review and discussion [1].

Results

The search yielded 856 articles. Of those, 47 articles from PubMed and EMBASE remained after filtering for relevancy and exclusion criteria, with no relevant articles from Cochrane. The remaining articles consisted of 5 reviews, 1 patient handout, 1 case-control study, 1 cross-sectional observational study, 19 case series, and 20 case reports published between 2007 and 2017. The toxic agents found to be associated with alopecia included:

thallium, mercury, selenium, colchicine, boric acid, arsenic, vitamin A, botulinum toxin, *Podostroma cornu-damae*, and the synthetic opioid MT-45 (Table 1). We will discuss the aforementioned toxins in order of decreasing evidence and frequency of reported toxicity.

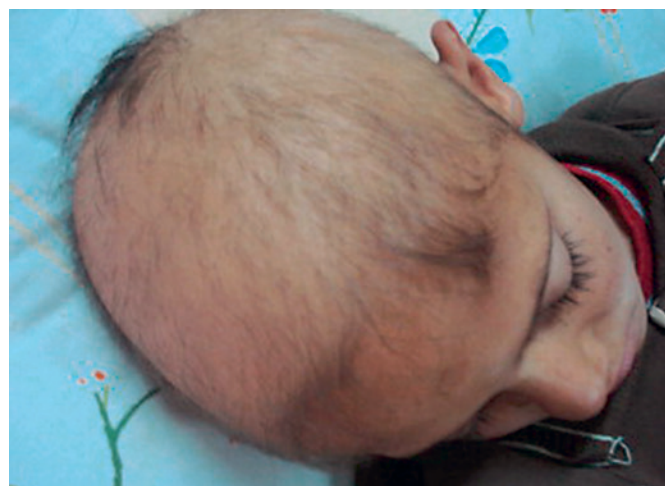Thallium

Thallium is a heavy metal whose salt form is tasteless, odorless, colorless, and dissolves completely in liquids. These properties have made thallium an ideal choice for criminal poisonings. The estimated half-life of thallium in humans ranges widely from 1 to 30 days, depending on the dose of thallium [2]. The average lethal dose for thallium sulfate has been reported as 10–15 mg/kg [3]. Polyneuropathy and gastrointestinal symptoms such as diarrhea, nausea, and vomiting are the hallmark symptoms of thallium poisoning, as well as the presence of Mees' lines roughly 1 month after poisoning [4–8].

Thallium was widely used as a rodenticide and insecticide until it was banned in the US in 1972 due to environmental concerns and extreme toxicity [4]. However, cases of both accidental and intentional (malicious or suicidal) poisoning continue to be reported worldwide. Common occupational exposure occurs due to thallium use in the manufacture of certain electronics, semiconductor materials, and alloys [9].

Thallium reportedly causes hair loss by binding to the sulphhydryl group of hair keratins, thus disrupting formation of the hair shaft [10]. Thallium poisoning specifically results in anagen effluvium, defined as active hair loss >100 hairs/day over a period of 2–4 weeks, often presenting as diffuse alopecia 2–3 weeks after toxic thallium exposure (Fig. 2). Less commonly, hair loss following thallium exposure may occur over a shorter time course. For example, Li et al. [5] reported the start of hair loss in a 49-year-old female 7 days after the onset of polyneuropathy following malicious thallium poisoning. Namba et al. [11] also reported hair loss 1 week after the ingestion of thallium in 3 out of 5 patients. In addition to anagen effluvium, thallium toxicity can supposedly cause ciliary madarosis, although the authors found no cases reporting the loss of eyelashes [12, 13]. However, 4 cases reported loss of eyebrows in thallium-poisoned patients, as well as scalp alopecia [4, 6, 7, 14]. With the exception of 3 case reports, body hair, such as axillary and pubic hair, was spared or not noted [2, 7, 15].

Thallium and other heavy metals have been added to black market opiates by drug dealers as a way to surreptitiously increase the product weight. Cases of suspected thallium poisoning in heroin users have been reported



Color version available online

Fig. 2. Diffuse alopecia from thallium poisoning in a young boy [2]. This is a case of diffuse alopecia following ingestion of an unknown amount of thallium via malicious poisoning.

[16]. In a case-control study by Ghaderi et al. [17], 20 out of 100 patients using street opiates had detectable levels of thallium in their urine, with 45 patients reporting scalp hair loss.

Mercury

Mercury is another heavy metal implicated in alopecia; like thallium, mercury binds to the sulphhydryl group of keratins in hair and can result in anagen effluvium [10]. At toxic levels, mercury causes free-radical damage, resulting in symptoms such as fatigue, depression, insomnia, irritability, memory loss, recurrent infections, tremors, and hair loss [18]. French et al. [19] reported a case of a 39-year-old female who intentionally injected herself subcutaneously with mercury to obtain worker's compensation benefits, presenting with rash, hair loss, myalgias, and photosensitivity. Given this patient's presentation, it is unclear whether her symptoms were fictional or influenced by her objective to pursue worker's compensation. Wu et al. [20] described a 51-year-old man presenting with hair loss, fever, dizziness, rash, anorexia, and weakness of extremities after using a topical homeopathic traditional Chinese mineral mixture to treat anal fistulas; analysis of this mixture revealed that it contained mercury and arsenic.

Arsenic

Arsenic is a metalloid naturally occurring in soil, water, and seafood, and used industrially in pesticides, animal feed additives, and metal alloys. The link between

Table 1. A summary of all included articles [2, 4–8, 10–15, 17–31, 33, 37, 41–43, 51, 52, 56, 64–74] with evidence rating as determined by the modified Oxford Centre for Evidence-Based Medicine scale [1]

Authors [Ref.]; Title	Type of Study	Patient(s)	Toxin	Method of toxin absorption; reason	Amount of toxin taken	Toxin level	Onset and description of alopecia	Other symptoms	Evidence rating
Kanwar and Narang [10]: Anagen effluvium	Review		Thallium, mercury, colchicine, boric acid				Thallium, mercury, and colchicine: anagen effluvium		1
Sachdeva and Prasher [12]: Madarosis: a dermatological marker	Review		Thallium, botulinum A, boric acid, arsenic, vitamin A				Botulinum A: unilateral madarosis and facial alopecia All others: ciliary madarosis		1
Velez et al. [13]: Eyebrow loss	Review		Thallium, vitamin A				Thallium: anagen hair loss in second or third week in the lateral regions of the eyebrow and occasionally the eyelashes, scalp, limbs, and axilla Vitamin A: thinning of eyebrows		1
Apostolova et al. [67]: Criminal thallium poisoning: a case series	Case series	61-year-old female	Thallium	Unknown; malicious poisoning	Unknown	240 ng/mL (serum)	Diffuse scalp alopecia (progressing over a period of 2 weeks after the beginning of symptoms)	Diffuse myalgia, muscle weakness, ataxia, paresthesiae, stomatitis, eczematous lesions around the mouth, abdominal pain, constipation, headache, insomnia, depression, fluctuating pulse and serum pressure, hypohidrosis	4
Campbell et al. [65]: Anagen effluvium caused by thallium poisoning	Case report	25-year-old male	Thallium	Unknown	Unknown	>100 µg/L (serum) (upper limit of normal: 2 µg/L)	Diffuse, n onscarring, noninflammatory alopecia with anagen hairs	Hypertension, tachycardia, weight loss, peripheral neuropathy, fatigue	5
Curto-Barredo et al. [64]: Anagen effluvium due to thallium poisoning derived from the intake of Chinese herbal medicine and rodenticide containing thallium salts	Case series	39-year-old female	Thallium	Ingestion; malicious poisoning	Unknown	Unknown	Diffuse noninflammatory alopecia	Pain in lower extremities	4
Center for Disease Control and Prevention (CDC) [68]: Thallium poisoning from eating contaminated cake	Case series	12-year-old female	Thallium	Ingestion; malicious poisoning	Unknown	Unknown	3 weeks after initial gastrointestinal symptoms; diffuse anagen alopecia with tapered pigmented hair bulb	Gastrointestinal symptoms, pain and hyperesthesia in lower extremities, confusion	4
Ghadiri et al. [17]: Thallium exists in opioid poisoned patients	Case-control	10 patients	Thallium	Ingestion; malicious poisoning	Unknown	Median serum thallium level 289 µg/L (range: 53–1,408 µg/L; reference level expected: <2 µg/L)	By 30 days after poisoning, all 8 surviving patients had experienced hair loss, which had begun within 7 days of poisoning	Abdominal pain, vomiting, dysphagia, pain and muscle weakness in lower extremities, spasticity	4
Kuroda et al. [8]: Tardily accelerated neurologic deterioration in two-step thallium intoxication	Case report	16-year-old male	Thallium	Ingestion; malicious poisoning	Estimated dosages: 800 mg and 400 mg of thallium sulfate	Range <50 to 400 µg/L (urine) (negative considered as <50 µg/L)	16 days after poisoning	$n = 100$: scalp hair loss (45%), dry skin (36%), acne (8%), rashes (6%), body hair loss (5%)	5

Table 1 (continued)

Authors [Ref.]; Title	Type of Study	Patient(s)	Toxin	Method of toxin absorption; reason	Amount of toxin taken	Toxin level	Onset and description of alopecia	Other symptoms	Evidence rating
Li et al. [5]; Human fatality due to thallium poisoning: autopsy, microscopy, and mass spectrometry assays	Case series	49-year-old female	Thallium	Ingestion; malicious poisoning	Unknown	8.8 µg/L (urine) (reference value: 0 µg/L)	7 days after initial symptoms of numbness/tingling; scanning EM showed a tapered, distorted root with atrophy of hair bulb	Numbness and tingling in extremities, allodynia, hyperesthesia, weakness, perioral dermatitis, stomatitis, Mees' lines	4
		50-year-old male	Thallium	Ingestion; malicious poisoning	Unknown	4.3 µg/L (urine)		Numbness and tingling in extremities, allodynia, hyperesthesia, weakness, perioral dermatitis, Mees' lines	
Liu et al. [4]; Optic nerve atrophy and hair loss in a young man	Case report	Young male	Thallium	Unknown; possible occupational exposure	Unknown	> 100 µg/L (serum) (reference limit: <5 µg/L)	Alopecia and loss of lateral half of eyebrows	Acquired color blindness, vision loss, confusion, memory loss, vomiting, diarrhea, facial rash, peripheral neuropathy in feet, Mees' lines	5
Lu et al. [6]; Short-term thallium intoxication: dermatological findings correlated with thallium concentration	Case series	52-year-old male	Thallium	Ingestion; malicious poisoning	Unknown	950 ng/g (serum); 22,650 µg/d (24-h urine) (reference range: 0–3 µg/d)	Hair loss started in the third week – mild alopecia of scalp and eyebrow, eyelashes and pubic hair spared	Nausea, vomiting, muscle aches, numbness of tongue and mouth, paresthesia and dysesthesia in extremities, Mees' lines	4
		48-year-old female	Thallium	Ingestion; malicious poisoning	Unknown	2,056 ng/g (serum); 29,040 µg/d (24-h urine)	Hair loss started in the third week – marked alopecia of scalp and eyebrow, eyelashes and pubic hair spared; light microscopy showed tapered, pigmented, dystrophic anagen hairs		
Namba et al. [11]; Thallium group poisoning incident	Case series	5 patients	Thallium	Ingestion; malicious poisoning	Unknown	Unknown	3 patients experienced profound hair loss 1 week after ingestion	Lower extremity numbness and pain	5
Ostapenko et al. [69]; Case of mass thallium poisoning in a factory	Case series	8 patients, aged 19–66 years	Thallium	Inhalation/skin contact; possible occupational exposure	Unknown	Range 0–2,440 µg/L (urine) (safe thallium level: <1.7 µg/L)	5 patients experienced alopecia	Abdominal pain and weakness, numbness of lower limbs, joint pain, encephalopathy, loss of appetite	4
Pelclova et al. [66]; International co-operation in treatment of suicidal thallium intoxication	Case report	24-year-old male	Thallium	Ingestion; suicide attempt	1.4 mg/kg	1,460 µg/L (urine) (normal: <5 µg/L)	Alopecia areata	Paresthesia and pain in limbs, delirium, cheilitis, optic nerve atrophy	5
Pelclova et al. [15]; Two-year follow-up of two patients after severe thallium intoxication	Case series	44-year-old female	Thallium	Ingestion; malicious poisoning	Unknown	0.3 µg/L (serum) (reference range: 0.018–2.00 µg/L); 8.5 µg/L (urine) (reference range: 0.049–23.3 µg/L)	"Lost all her hair" within 5 days of initial symptoms of lower limb pain	Pain and paresthesia in lower extremities, blurry vision	4
		22-year-old female	Thallium	Ingestion; malicious poisoning	Unknown	770 µg/L (serum); 2,800 µg/L (urine)	Diffuse alopecia in the fourth week of symptoms; eyebrows and eyelashes spared; body hair rare and thin; light microscopy showed a distorted, tapered, pigmented bulb with gaseous inclusions		
Sharquie et al. [2]; Outbreak of thallium poisoning among Iraqi patients	Case series	5 male patients, aged 10–32 years (mean age 24 years)	Thallium	Ingestion; malicious poisoning	Unknown	Unknown	Diffuse and patchy severe hair loss from scalp and body	Nausea, vomiting, diarrhea, mental and peripheral neurological complaints, muscular weakness	4

Table 1 (continued)

Authors [Ref.]; Title	Type of Study	Patient(s)	Toxin	Method of toxin absorption; reason	Amount of toxin taken	Toxin level	Onset and description of alopecia	Other symptoms	Evidence rating
Sojakova et al. [70]; Thallium intoxication	Case report	24-year-old male	Thallium	Ingestion; suicide attempt	100 mg thallium monobromide	1,450 µg/L (urine)	Diffuse alopecia	Painful paresthesia of the legs, partial atrophy of optic nerve, cheilitis	5
Sun et al. [14]; Management of thallium poisoning in patients with delayed hospital admission	Case series	7 males and 7 females, median age 36 years	Thallium	Ingestion; malicious poisoning	Unknown	Range: 956–11,285 µg/L (urine) (reference range <5 µg/L)	All 14 patients reported scalp hair loss a few days after onset of limb and abdominal pain, and loss of lateral eyebrows; eyelashes, axillae, pubic hair spared	Most common: nausea, vomiting, abdominal distention, gastrointestinal pain, pain and numbness in extremities, dizziness, headache, fatigue	4
Yumoto et al. [71]; A successfully treated case of criminal thallium poisoning	Case report	23-year-old female	Thallium	Ingestion; malicious poisoning	Unknown	223 µg/L (serum); 351 µg/L (urine)	Hair loss in temporal and parietal regions starting in the second week after initial symptoms	Fatigue, muscle pain, plantar numbness, nausea, abdominal pain	5
Zhao et al. [7]; Clinical manifestations and management of acute thallium poisoning	Case series	37-year-old male	Thallium	Ingestion; malicious poisoning	Unknown	303.8 ng/mL (serum) (normal: <8 ng/mL); 2,359 ng/mL (urine) (normal <5 ng/mL) 180 ng/mL (serum)	Severe alopecia 20 days after onset of initial symptoms of pain and numbness	All 3 patients had severe pain in lower limbs and abdomen, diffuse alopecia, hepatic dysfunction, Mees' lines, paresthesia of all limbs	4
		27-year-old female	Thallium	Ingestion; malicious poisoning	Unknown	<5 ng/mL (serum)	Severe alopecia 20 days after onset of initial symptoms of pain and numbness	Severe alopecia, affecting the scalp, eyebrow and limbs	
		31-year-old male	Thallium	Ingestion; malicious poisoning	Unknown	90.9 ng/mL (serum)			
French et al. [19]; Metal for money: factitious occupational mercury exposure	Case report	39-year-old female	Mercury	Subcutaneous injection; malingering	Unknown	1,030 µg/L (urine)	Unknown	Rash, myalgia, fatigue, photosensitivity	5
Neustadt and Pieczenik [18]; Toxic-metal contamination: mercury	Patient handout		Mercury					Fatigue, depression, insomnia, irritability, memory loss, recurrent infections, tremors	5
Wu et al. [20]; Lead, mercury, and arsenic poisoning due to topical use of traditional Chinese medicines	Case report	51-year-old male	Mercury and arsenic	Topical application	Unknown	Arsenic (urine): 541 µg/g creatinine (normal: <100 µg/g creatinine) Mercury: 5.8 µg/L (normal <5 µg/L)	Hair loss	Fever, dizziness, rash, anorexia, weakness of extremities, muscle atrophy, anemia	5
Amster et al. [24]; Potential arsenic toxicosis secondary to herbal kelp supplement	Case report	54-year-old female	Arsenic	Ingestion; kelp supplements	Unknown	83.6 µg/g creatinine (urine) (reference range: <50 µg/g creatinine)	2-year history of worsening alopecia, "within a few months" of starting kelp supplements	Memory loss, rash, fatigue, nausea, vomiting, diarrhea	5
Das et al. [22]; Papillon-Lefevre syndrome-like presentation in chronic arsenicosis: a rare mimicry	Case report	20-year-old female	Arsenic	Unknown	Unknown	Unknown	Hair was sparse, fine, lusterless, brittle; decreased body hair and sparse or absent eyebrows and eyelashes	Xerostomia, xerophthalmia, conjunctivitis, pyogenic skin lesions, palmar-plantar hyperkeratosis, frequent dental caries and falling out of teeth	5
Ghosh [21]; Evaluation of chronic arsenic poisoning due to consumption of contaminated ground water in West Bengal, India	Cross-sectional observational study	73 cases	Arsenic	Consuming water containing arsenic ≥50 µg/L	Unknown	Hair and nail arsenic level >0.6 µg/L	8 out of 73 cases had alopecia	Mucocutaneous and nail lesions, hepatomegaly, and restrictive change in spirometry	4

Table 1 (continued)

Authors [Ref.]; Title	Type of Study	Patient(s)	Toxin	Method of toxin absorption; reason	Amount of toxin taken	Toxin level	Onset and description of alopecia	Other symptoms	Evidence rating
Tandon and Infield [23]: Immunocompromise due to seaweed consumption (a form of arsenic poisoning)	Case report	54-year-old female	Arsenic	Ingestion; seaweed	Seaweed consumed contained 83,400 ppb (or 83.4 mg/L) which is 8,000 times the EPA's safe range	Urine arsenic levels >200 µg/g creatinine (reference range: <50 µg/g creatinine)	Unknown; alopecia not otherwise characterized	Weakness, weight loss, scaly erythematous skin, thickened and yellow nails	5
Webb et al. [25]: Boric acid ingestion clinically mimicking toxic epidermal necrolysis	Case report	56-year-old male	Boric acid	Intentional ingestion; possible suicide attempt	2 cups roach killer containing boric acid	34 mg/L (serum) (normal <100 µg/L)	Alopecia totals	Altered mental status, fever, stiffness, diffuse erythematous skin eruption, bilateral palmar erythema	5
Agarwal et al. [31]: Selenium toxicity: a rare diagnosis	Case report	35-year-old male	Selenium	Ingestion; possible malicious poisoning	Unknown	27 µg/g (nail) (normal: 0.809 µg/g) 35 µg/g (hair) (normal: 0.36 µg/g)	Hair loss and fragility of hair all over the body, including scalp (most prominent in occipital area), beard, axillary, and pubic hair; microscopy showed shrunken, pigmented anagen hair bulbs	Brittle nails and nail dystrophy/discoloration	5
Aldosary et al. [29]: Case series of selenium toxicity from a nutritional supplement	Case series	38-year-old male 37-year-old female 15-year-old male 57-year-old male 56-year-old female 43-year-old female 49-year-old male 46-year-old female 57-year-old male	Selenium Selenium Selenium Selenium Selenium Selenium Selenium Selenium Selenium	Ingestion; supplement Ingestion; supplement Ingestion; supplement Ingestion; supplement Ingestion; supplement Ingestion; supplement Ingestion; supplement Ingestion; supplement Ingestion; supplement	979.2 mg (total cumulative dose) 979.2 mg (total cumulative dose) 979.2 mg (total cumulative dose) 1,917.6 mg (total cumulative dose) 1,917.6 mg (total cumulative dose) 1,876.8 mg (total cumulative dose) 734.4 mg (total cumulative dose) 408 mg (total cumulative dose) 2,448 mg (total cumulative dose)	41 µg/g creatinine (urine) (reference: <25 µg/g creatinine) 97 µg/g creatinine (urine) 56 µg/g creatinine (urine) 110 µg/g creatinine (urine) 220 µg/g creatinine (urine) 69 µg/g creatinine (urine) 120 µg/g creatinine (urine) 110 µg/g creatinine (urine) 120 µg/g creatinine (urine)	4 out of 9 patients experienced hair loss in the first week Eventually, all had hair loss, with 2 patients experiencing alopecia universalis	Severe myalgia in lower extremities, diarrhea Nail changes after 2 weeks of consumption, numbness/tingling in lower limbs Weak/brittle nails, myalgias Diarrhea, arthralgia, memory difficulty, fingernail changes Diarrhea, arthralgias, concentration problems Joint pain, constipation, nausea, nail changes Malaise, arthralgia, myalgia, nail changes, memory difficulty, diarrhea Painful rash on scalp, metallic taste, garlicky odor from breath, memory difficulty, myalgia, fatigue Myalgia, difficulty with memory, tinnitus	4

Table 1 (continued)

Authors [Ref.]; Title	Type of Study	Patient(s)	Toxin	Method of toxin absorption; reason	Amount of toxin taken	Toxin level	Onset and description of alopecia	Other symptoms	Evidence rating
Dosary et al. [30]; Subacute selenium toxicity from a nutritional supplement	Case series	40-year-old male	Selenium	Ingestion; supplement	576 mg (estimated cumulative dose)	732 µg/L (serum)	Alopecia, some point after 7 days	Muscle aches, diarrhea, abdominal pain, onycholysis, memory and sensory abnormalities	4
		38-year-old female	Selenium	Ingestion; supplement	576 mg (estimated cumulative dose)	313 µg/L (serum)	Alopecia/general hair loss on the 7th day	Diarrhea, abdominal pain, onycholysis, memory and sensory abnormalities	
		16-year-old male	Selenium	Ingestion; supplement	576 mg (estimated cumulative dose)	391 µg/L (serum)	Alopecia, some point after 7 days	Nail changes, diarrhea, onycholysis, memory and sensory abnormalities	
		59-year-old male	Selenium	Ingestion; supplement	1,441 mg (estimated cumulative dose)	300 µg/L (serum)	Alopecia, some point after 7 days	Diarrhea, onycholysis, memory changes	
		56-year-old female	Selenium	Ingestion; supplement	1,441 mg (estimated cumulative dose)	524 µg/L (serum)	General hair loss, some point after 7 days	Diarrhea, onycholysis, memory changes	
		45-year-old female	Selenium	Ingestion; supplement	1,153 mg (estimated cumulative dose)	150 µg/L (serum)	Alopecia within the first week	Nausea, constipation, onycholysis	
		51-year-old male	Selenium	Ingestion; supplement	432 mg (estimated cumulative dose)	660 µg/L (serum)	Alopecia, some point after 7 days	Diarrhea, abdominal pain, onycholysis, memory changes	
		48-year-old female	Selenium	Ingestion; supplement	240 mg (estimated cumulative dose)	264 µg/L (serum)	Alopecia on the 7th day	Foul breath, metallic taste, onycholysis, memory changes	
Lenz and Lens [27]; The essential toxin: the changing perception of selenium in environmental sciences	Review		Selenium				Hair loss	Nausea, vomiting, diarrhea, cardiovascular symptoms, defective nails and skin, unsteady gait and paralysis	1
MacFarquhar et al. [28]; Acute selenium toxicity associated with a dietary supplement	Case series	80 male and 121 female patients, aged 4–92 years (median age 54 years)	Selenium	Ingestion; supplement	Unknown	Mean initial serum selenium concentration of 8 patients was 751 µg/L (reference range: ≤125 µg/L)	70% (140 out of 201) patients had hair loss 14 patients reported complete loss of scalp hair 1 patient reported total body hair loss	Diarrhea, fatigue, joint pain, nail changes, nausea	4
Manzanares and Hardy [72]; Can dietary selenium intake increase the risk of toxicity in healthy children?	Review		Selenium				Hair loss	Brittle nails	1

Table 1 (continued)

Authors [Ref.]; Title	Type of Study	Patient(s)	Toxin	Method of toxin absorption; reason	Amount of toxin taken	Toxin level	Onset and description of alopecia	Other symptoms	Evidence rating
Müller and Desel [33]: Acute selenium poisoning by paradise nuts (<i>Lecythis ollaria</i>)	Case series	46-year-old female	Selenium	Ingestion	A "handful" of <i>Lecythis ollaria</i> nuts	479 µg/L (serum) (reference range: 74–139 µg/L)	"Substantial hair loss" starting 2 weeks after ingestion; trichogram showed alopecia diffusa with dystrophic follicles	Nausea, vomiting, dizziness, itching skin lesions on scalp, greyish discoloration of nails	4
Sutter et al. [73]: Selenium toxicity: a case of selenosis caused by a nutritional supplement	Case report	38-year-old female	Selenium	Ingestion	A "handful" of <i>Lecythis ollaria</i> nuts	300 µg/L (serum)	"Substantial hair loss" starting 12 days after ingestion; noninflammatory decrease in number of hair follicles	Muscle cramps, joint pain, fatigue, concentration difficulties, diarrhea, Mees' lines	5
Webb and Kerns [26]: What is the origin of these nail changes in an otherwise healthy young patient?	Case report	55-year-old female	Selenium	Ingestion; supplement	for 7 weeks, daily selenium intake was approximately 24 mg	534 µg/L (serum) (reference range: 80–150 µg/L)	Hair loss of scalp progressing to axillae, genitalia, and extremities, 3 weeks after starting supplements	Muscle cramps, joint pain, fatigue, concentration difficulties, diarrhea, Mees' lines	5
Alaygat et al. [41]: Assessment of 17 pediatric cases with colchicine poisoning in a 2-year period	Case report	Female	Selenium	Ingestion; supplement	Unknown	233 µg/L (serum) (reference range: 110–160 µg/L)	Hair loss "in handfuls" roughly 2 weeks after starting supplements	Myalgia, arthralgia, nausea, anorexia, fatigue, weight loss, memory impairment, Mees' lines	5
Alaygat et al. [41]: Assessment of 17 pediatric cases with colchicine poisoning in a 2-year period	Case series	17 children with colchicine poisoning aged 0–18 years, only 1 with alopecia (16-year-old female)	Colchicine	Ingestion; suicide attempt	0.88 mg/kg	Unknown	Total alopecia	Diarrhea, vomiting, abdominal pain, leukocytosis	4
Biçer et al. [43]: Acute colchicine intoxication in a child	Case report	3-year-old female	Colchicine	Ingestion; accidental poisoning	0.7 mg/kg	Unknown	Alopecia seen in the second week	Vomiting, hypoaactive deep tendon reflexes, weak pulse, 13 on Glasgow Coma scale	5
Combaila et al. [42]: Anagen effluvium following acute colchicine poisoning	Case report	17-year-old female	Colchicine	Ingestion; suicide attempt	40 mg	Unknown	7 days after poisoning, sudden anagen effluvium from scalp; trichoscopy showed anagen hairs with pigmented long roots covered by root sheath	Pancreatitis, bicytopenia	5
Kande Vidanalage et al. [74]: A rare case of attempted homicide with <i>Gloriosa superba</i> seeds	Case report	27-year-old male	Colchicine	Ingestion; malicious poisoning	unknown	Unknown	Massive generalized alopecia 10 days after poisoning	Diarrhea, abdominal pain, dysuria, fever, thrombocytopenia, renal impairment	5
Senthilkumar et al. [37]: Hard facts about loose stools – massive alopecia in <i>Gloriosa superba</i> poisoning	Case report	26-year-old male	Colchicine	Intentional ingestion; suicide attempt	Two tubers of <i>Gloriosa superba</i>	Unknown	"Started to lose his hair on day 9, totally alopecic by day 14" Photo suggests axillary hair loss as well	Fever, confusion, hematuria, aggressive behavior, vomiting, diarrhea, fever, bleeding gums	5
Senthilkumar et al. [37]: Hard facts about loose stools – massive alopecia in <i>Gloriosa superba</i> poisoning	Case report	20-year-old male	Colchicine	Intentional ingestion; instructed by traditional practitioner	Some amount of <i>Gloriosa superba</i> tuber	Unknown	Diffuse scalp hair loss 6 days after poisoning; trichogram showed anagen hairs with dystrophic follicles	Serum diarrhea, vomiting, abdominal pain, pancytopenia	5

Table 1 (continued)

Authors [Ref.]; Title	Type of Study	Patient(s)	Toxin	Method of toxin absorption; reason	Amount of toxin taken	Toxin level	Onset and description of alopecia	Other symptoms	Evidence rating
Di Pietro and Piracchini [51]; Frontal alopecia after repeated botulinum toxin type A injections for forehead wrinkles: an underestimated entity?	Case series	5 female patients aged 45–58 years (mean age 52.7 years)	Botulinum toxin A	Injection; cosmetic	Unknown	Unknown	Frontal alopecia; mean distance between hairline and glabella >6 cm; trichoscopy showed evident follicular ostia with vellus, with no inflammation, scarring, or atrophy	Memory loss, rash, fatigue, nausea, vomiting, diarrhea	4
Kim et al. [52]; Two cases of incidental <i>Podostroma cornu-damae</i> poisoning	Case series	2 patients, 1 with alopecia (62-year-old female)	<i>Podostroma cornu-damae</i>	Ingestion; accidental poisoning	Unknown	Unknown	5 days after ingestion (had been ingesting for previous 12 days)	Fever, weakness, abdominal discomfort, desquamation of hands and feet, neutropenia	5
Helander et al. [56]; Acute skin and hair symptoms followed by severe, delayed eye complications in subjects using the synthetic opioid MT-45	Case series	23-year-old male 34-year-old male 30-year-old male	MT-45 MT-45 MT-45	Unknown; recreational drug use Unknown; recreational drug use Unknown; recreational drug use	280 ng/mL (serum) 112 ng/mL (serum) 22 ng/mL (serum)	Unknown Unknown Unknown	"Loss of scalp hair – total alopecia"; histopathology showed follicular destruction with marked neutrophilic inflammation Scalp hair, eyebrows and eyelashes stopped growing, thinned and depigmented Hair loss, depigmentation of scalp hair, eyebrows, and eyelashes about 10 days after using MT-45	Hair depigmentation, hair loss, widespread folliculitis and dermatitis, painful intertriginous dermatitis, dry eyes, and elevated liver enzymes 2 patients with Mees' lines	4

arsenic and alopecia is not as well delineated as with heavy metals. A cross-sectional observational study performed in West Bengal reported that alopecia was present in 8 out of 73 individuals consuming water containing $\geq 50 \mu\text{g/L}$ of arsenic; analysis of the hair and nails revealed arsenic levels of $>0.6 \mu\text{g/L}$. Skin and mucosal lesions, as well as hepatomegaly, were more frequently reported symptoms [21]. Arsenic has also been reported to cause ciliary madarosis. A 20-year-old female from a South Bengal village with confirmed chronic arsenicosis was reported to have symptoms including xerostomia, xerophthalmia, conjunctivitis, pyogenic skin lesions, palmar-plantar hyperkeratosis, dental caries, and chronic alopecia since childhood (including body hair, eyebrows, and eyelashes) [22].

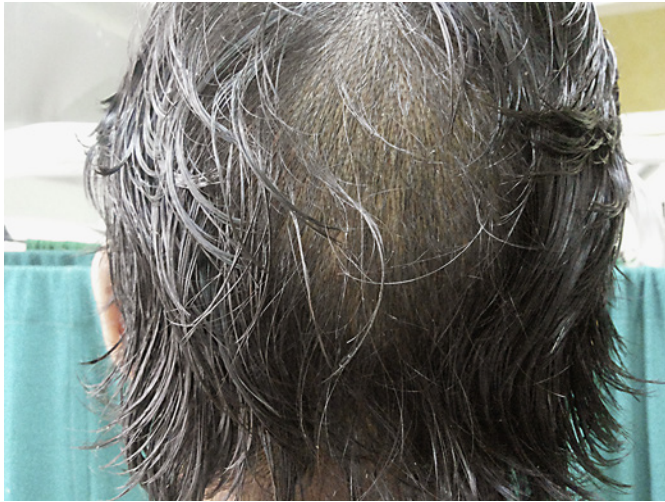Seaweed may also contain potentially toxic levels of arsenic. Tandon and Infeld [23] described a case of a 54-year-old female presenting with alopecia, weakness, weight loss, scaly erythematous skin, and nail changes. Her diet consisted mainly of seaweed soup, with the seaweed containing 83.4 mg/L of arsenic, 8,000 times the Environmental Protection Agency's (EPA's) designated safe levels. Her urine arsenic level was $>200 \mu\text{g/g}$ creatinine (Cr), with the reference range $<50 \mu\text{g/g}$ Cr [23]. Amster et al. [24] described a similar case of a 54-year-old female with alopecia starting a few months after beginning kelp supplements. Other symptoms included memory loss, rash, fatigue, nausea, vomiting, and diarrhea; her urine arsenic level was $83.6 \mu\text{g/g}$ Cr [24]

Boric Acid

Boric acid, or hydrogen borate, is the weak acid of boron found ubiquitously in nature and used by the enamel, glass, and metal industries [25]. It is also found in insecticides, food preservatives, antiseptics, and flame retardants. Current research reports that boric acid toxicity causes anagen effluvium and eyelash loss [10, 12]. In a separate case report, a 56-year-old male presented with alopecia totalis after intentionally ingesting roach killer containing boric acid. Other symptoms included fever, altered mental status, stiffness, diffuse erythematous skin eruption, and bilateral palmar erythema [25].

Selenium

Although selenium is characterized as a non-metal, the symptoms of selenium toxicity can resemble that of heavy metal poisoning, including hair loss and Mees' lines [26]. Other symptoms from acute selenium poisoning include nausea, vomiting, diarrhea, and progression to neurological problems such as unsteady gait and paralysis [27]. A proposed mechanism for the dermatologi-



Color version available online

Fig. 3. Patchy hair loss from selenium toxicity [31]. A 35-year-old male patient ingested toxic levels of selenium, resulting in patchy hair loss concentrated in the occipital scalp.

cal symptoms of selenosis involves selenium substituting for sulfur in keratin proteins, thus leading to the loss of disulfide bridges, and abnormal development of hair and nail protein structure [26]

Of the 7 case reports or series of selenosis resulting in alopecia included in this review, 5 resulted from the patients' intake of dietary supplements containing selenium, 1 resulted from ingestion of *Lecythis ollaria* (paradise nuts), and 1 after ingestion from an unknown source. MacFarquhar et al. [28] described a case in which a dietary supplement company misformulated one of their supplements containing selenium. The supplement contained 700 times the recommended daily allowance (RDA), resulting in 201 confirmed cases of adverse events, with 140 patients reporting hair loss [28]. In a case series of patients taking selenium ($n = 9$), 4 patients developed hair loss within the first week, and eventually, all patients experienced hair loss and 2 patients had alopecia universalis. Symptoms also included diarrhea, myalgia, fatigue, and nail changes [29]. Dosary et al. [30] described another 8 patients who took selenium, who experienced alopecia as early as 1 week. Agarwal et al. [31] described the patchy hair loss, most pronounced in the occipital area, in a patient with selenosis from an unknown source (Fig. 3).

Selenium is also found in high concentrations in *Lecythis ollaria* nuts (paradise nuts) as seleno-cystathionine; the concentration of selenium can be as high as 7–12 g/kg of dried nuts [32]. Müller and Desel [33] described 2 pa-

tients who ingested “a handful” of nuts: one, a 46-year-old female, who experienced hair loss 2 weeks after ingestion; and one, a 38-year-old female, who experienced hair loss 12 days after ingestion. Both patients also reported nausea, dizziness, and grey discoloration of the nails [33].

Colchicine

Colchicine is an alkaloid drug used to treat a number of conditions including familial Mediterranean fever, Behçet's disease, amyloidosis, and gout. It has a narrow therapeutic window, with a reported 100% survival after ingestion of <0.5 mg/kg of colchicine and 100% mortality with ≥ 0.8 mg/kg via cardiogenic shock and myelosuppression [34–36]. Colchicine affects cell division by disrupting mitosis and cell transport systems secondary to arrested microtubule polymerization. Thus, the most affected organs are those with a high rate of cell turnover, such as bone marrow, gastrointestinal tract, and hair [37].

There are 3 stages to the clinical presentation of colchicine toxicity. With the first 24 h after ingestion, common symptoms include nausea, vomiting, diarrhea, and leukocytosis. Multiorgan failure, including bone marrow suppression, occurs in the second stage, 1–7 days after ingestion. Individuals who recover experience the third stage, often characterized by transient alopecia between days 7 and 21 [38–40]. However, hair loss may not always be present. In a case series by Alaygut et al. [41], only 1 out of 17 children with colchicine toxicity developed alopecia. The patient was a 16-year-old female who ingested colchicine prescribed for her father's Behçet's disease. Although Bismuth et al. [35, 36] reported 100% mortality at 0.8 mg/kg, this patient ingested 0.88 mg/kg of colchicine in a suicide attempt and miraculously survived [41]. In a separately reported suicide attempt, a 17-year-old female ingested 40 mg of colchicine with sudden anagen effluvium of the scalp on the seventh day after ingestion [42]. Case reports of accidental ingestion of prescribed medication also exist, such as in the case of a 3-year-old female who ingested 20 pills (0.7 mg/kg) of colchicine and developed alopecia within 2 weeks [43].

Ingestion may also occur through consumption of natural sources such as plants in the Colchicaceae family, which contain high levels of colchicine. One species, *Gloriosa superba*, grows in the Sri Lankan wilderness. A retrospective study from western Sri Lanka concluded that *G. superba* was responsible for 44% of plant poisonings, with a 15% case fatality rate [44]. Premaratna et al. [45] described a case of a 26-year-old male who consumed 2 tubers of *G. superba* in an attempt to self-harm. The patient began to lose hair on day 9 and became totally alo-

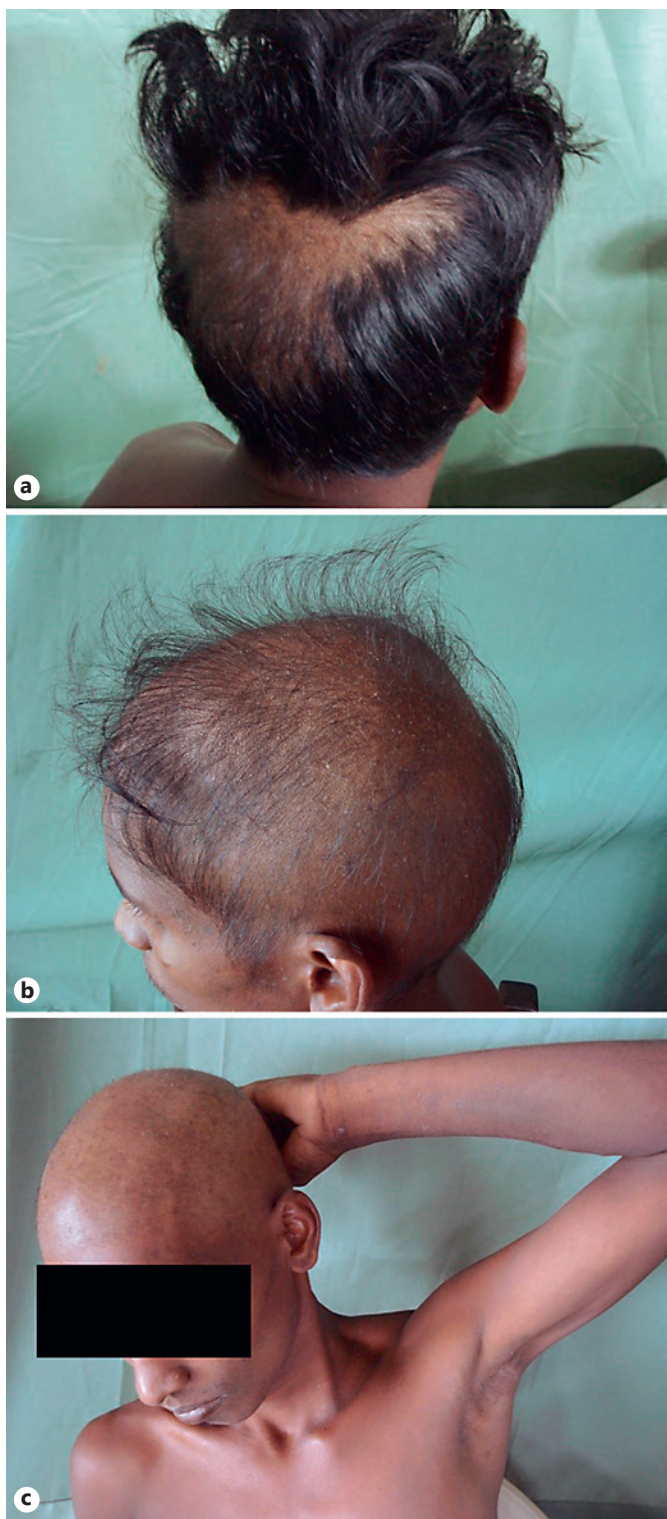

Fig. 4. Alopecia after intentional ingestion of *G. superba* [45]. A 26-year-old male ingested harmful amounts of colchicine from a natural source, *G. superba*. The patient is shown at 9 days after poisoning with onset of hair loss (a), at 11 days (b), and at 14 days (c), demonstrating loss of scalp and axillary hair.

pec by day 14 (Fig. 4) [45]. Senthilkumaran et al. [37] reported a similar case of a 20-year-old male who consumed tubers, instructed by a traditional practitioner, and experienced diffuse loss of scalp hair 6 days later.

Hypervitaminosis A

Vitamin A has multiple functions within the body, including skin health, vision, and maintenance of the immune system [46]. Two forms of this vitamin are obtained in the diet: either as a preformed retinol found in dairy products and liver, or provitamin A carotenoids, such as beta-carotene, found in plants. Vitamin A toxicity occurs when ingesting high quantities of the retinol form; beta-carotene, even at large doses, is not associated with toxicity [47]. The RDA for the retinol form is 4,000 IU for women and 5,000 IU for men [48]. Vitamin A at toxic levels reportedly causes scalp alopecia as well as loss of eyelashes and eyebrows [12, 13, 49]. Other symptoms of toxicity include fatigue, malaise, weight loss, nail dystrophy, and flaky skin [48]. Individuals taking high-dose supplements or systemic retinoids may be at risk.

Botulinum Toxin Type A

Botulinum A injections have been used for years without any known link to alopecia. Recently, however, unilateral madarosis and facial alopecia were reported as a result of long-term use of botulinum A injections for the treatment of orofacial dystonia [50]. In addition, subjective nonscarring frontal alopecia has also been described by Di Pietro and Piraccini [51] in a case series of 5 female patients who had all undergone periodic botulinum A injections for forehead wrinkles. There was no objective measurement of hair loss before the start of injections or after hair loss occurred.

Podostroma cornu-damae

Podostroma cornu-damae is a rare and highly toxic species of fungus in the Hypocreaceae family that grows in Eastern Asia and Java. Although the mechanism by which the toxin acts is unknown, several fatalities associated with this fungus have been reported in Japan. Kim et al. [52] described 2 cases in Korea of accidental *P. cornu-damae* poisoning because the patients mistakenly made tea from the toxic fungus, thinking it was *Ganoderma lucidum*, a popular health food. Only 1 of the patients experienced alopecia 5 days after initial ingestion, as well as fever, weakness, abdominal discomfort, desquamation of hands and feet, and neutropenia [52]. Ahn et al. [53] reported similar cases, also in Korea, of 2 patients poisoned after mistaking *P. cornu-damae* for *G. lucidum*. One pa-

tient developed hair loss, along with accompanying fever, weakness, chills, and desquamation of palms and soles [53].

MT-45

There has been a rise in synthetic opioids and new psychoactive substances (NPS) on the recreational drug market. MT-45, a synthetic opioid invented in the 1970s, was originally developed as an opioid analgesic, with activity comparable to that of morphine [54, 55]. Sold on the internet as “research chemicals,” MT-45 and other synthetic opioids have recently been implicated in multiple fatalities.

MT-45 has also been implicated to cause hair loss. Helander et al. [56] described a case series in Sweden of 3 male patients presenting with alopecia following the use of MT-45. Patients experienced hair depigmentation, folliculitis, dermatitis, dry eyes, and elevated liver enzymes, as well as Mees’ lines. One patient developed a total alopecia, another patient noted cessation of scalp hair, eyebrow, and eyelash growth, and the last patient experienced uncharacterized hair loss beginning approximately 10 days after MT-45 use [56].

Discussion

Alopecia has a wide differential diagnosis and many causes including nutritional deficiencies, autoimmune disorders, pattern baldness, and exposure to toxic agents. Acute onset of alopecia associated with a number of generalized symptoms may lead the clinician to consider toxic exposure as a cause of alopecia. Multiple agents are known to cause alopecia when found at toxic levels in the human body including heavy metals, selenium, boric acid, vitamin A, prescription drugs such as colchicine, botulinum toxin, synthetic opioids, and fungi.

When assessing for heavy metal toxicity, clinicians should ask about possible occupational exposure, dental work, and diet, especially when hair loss is of acute onset and accompanied by general symptoms such as nausea, vomiting, fatigue, depression, insomnia, irritability, recurrent infections, and neurological symptoms, such as memory loss and tremors. Assessment of household toxic exposures is especially important in children. Clinicians should determine which products are present in the household and if they are safely stored. If an adult presents after the ingestion of household items, especially in the instance of boric acid poisoning, it is important to rule out suicidal ideation and/or attempt. In cases of over-the-

counter or prescription drug ingestion, again clinicians should thoroughly assess patients’ psychological state to determine if the ingestion was intentional. If a clinician suspects selenosis as a cause for alopecia, ask about supplements or paradise nut intake, as well as accompanying symptoms such as fatigue, nausea, diarrhea, joint pain, and/or nail changes. Clinicians should elucidate if colchicine is available at home (i.e., family members taking colchicine for a medical indication such as gout or Bechet’s disease) or if the patient ingested a plant from the Colchicaceae family. In all patients presenting with facial and frontal alopecia, without hair loss in other areas, clinicians should elicit a history regarding regular botulinum toxin use.

Thallium toxicity may occur through a variety of methods including ingestion, inhalation, or mucosal absorption and is defined as a urine thallium level >5 $\mu\text{g/L}$ within 24 h [17]. Thallium exposure can occur through occupational exposure, household use of rodent poisons, and intentional poisoning with malicious intent or secondary to attempted suicide. The triad of thallium poisoning is gastroenteritis, polyneuropathy, and a variety of dermatological symptoms including anagen effluvium within 2–3 weeks of exposure [57]. Although mercury toxicity has become less common, historically it was used for syphilis treatment, with vapor exposure still posing a concern for those working in the manufacturing industry as well as for patients with old-style dental amalgam fillings; another route of exposure is ingestion, found in high levels in the tissue of large deep-sea fish [18, 19].

Historically, arsenic was used to treat psoriasis, syphilis, and promyelocytic leukemia; currently, arsenic can be found in high concentration in some seaweed causing toxicity in those individuals who ingest large amounts in their diet [23]. In addition, chronic arsenicosis is a major health concern in areas of the world, such as Bangladesh and neighboring areas, because of ground-water contamination [58]. Affected individuals often present with skin manifestations on their palmar and plantar surfaces; however, a few patients may present with alopecia.

Household items such as insecticides, mouth wash, eye wash, wound irrigation, detergents, and personal care products may contain boric acid [59, 60]. Although not easily toxic to an adult, often accidental ingestion of these products by infants or young children may result in poisoning and possibly even fatality. Currently, the mechanism of boric acid toxicity is not well understood and treatment consists of supportive care.

With an increase in the public’s awareness of healthy dietary additions, selenium-containing supplements

have found a larger market. Given that the RDA of selenium is 55 µg, and the average daily intake in the US is reported at >80 µg (tolerated upper limit approx. 400 µg/day), currently there are no guidelines or recommendations for selenium supplementation in the diet [28, 30]. Although it is an essential element for proper cellular function, in large amounts selenium may become toxic. At physiological levels, selenium acts as an antioxidant; however, it may become a pro-oxidant at higher concentrations causing free-radical damage to cellular structures [61].

Colchicine toxicity is often a result of prescription drug overdose, either by accidental poisoning or suicide attempt. Although the reported half-life of colchicine is 9–16 h, it may be longer at higher doses [38, 62]. Hair loss often begins 7–14 days after colchicine exposure, accompanied by gastrointestinal symptoms and leukocytosis [42].

Botulinum toxin is a neurotoxic protein produced by *Clostridium botulinum*. By preventing the release of the neurotransmitter acetylcholine (ACh) at the neuromuscular junction (NMJ), the toxin produces a flaccid paralysis that has been exploited for medical purposes, such as anti-aging, and treating hyperhidrosis, muscle spasticity, and migraines [50, 63]. Several reports have described frontal alopecia after the use of botulinum toxin; however, the mechanism remains unknown.

As opposed to the loss of telogen hairs as part of the normal hair cycle, toxicity secondary to some of the substances discussed may result in loss of anagen hairs [10]. Microscopic examination of anagen hairs should reveal tapered, pigmented hair bulbs, with attached root sheaths, as compared to telogen hairs which demonstrate a club-shaped bulb with no pigment or root sheath [64]. Multiple cases involving thallium, colchicine, and selenium toxicity report anagen hairs with or without dystrophic follicles on trichoscopy, light microscopy, and

scanning microscopy [5, 6, 31, 37, 42, 64–66]. Unfortunately, many reported cases did not initially present to dermatology and microscopic examination of the hair was not completed. In cases of hair loss where the inciting factor or diagnosis is unclear, a consultation to dermatology must be included in the workup.

Conclusions

Thallium, mercury, selenium, and colchicine have compelling evidence linking toxic levels of these substances to hair loss. Compounds such as boric acid, vitamin A, botulinum toxin, chemicals found in the fungal species *P. cornu-damae*, and synthetic opioids, such as MT-45, have less evidence and their role in toxic hair loss is still emerging. Further research will need to be completed to elucidate a pattern and mechanism of hair loss for the aforementioned agents. A familiarity with the typical presentations of alopecia as well as accompanying symptoms can aid to recognize a possible toxic cause of the patient's alopecia.

Acknowledgements

The authors would like to acknowledge Dr. Khalifa Sharquie, Dr. Puneet Agarwal, and Dr. Ranjan Premaratna as well as their colleagues for generously providing use of patient photographs in Figures 2, 3, and 4, respectively. Use of material from the articles by Dr. Sharquie, Dr. Agarwal, and Dr. Premaratna was permitted by the terms of the Creative Commons Attribution 4.0 International License (<http://creativecommons.org/licenses/by/4.0/>).

Disclosure Statement

The authors have no conflicts of interest to disclose. The authors did not receive outside funding to complete this research.

References

- 1 Oxford Centre for Evidence-Based Medicine – levels of evidence. March 2009. <http://www.cebm.net/blog/2009/06/11/oxford-centre-evidence-based-medicine-levels-evidence-march-2009/> (last update 2017, accessed December 12, 2017).
- 2 Sharquie KE, Ibrahim GA, Noaimi AA, Hamudy HK: Outbreak of thallium poisoning among Iraqi patients. *J Saudi Soc Derm Dermatol Surg* 2011;15:29–32.
- 3 Galván-Arzate S, Santamaría A: Thallium toxicity. *Toxicol Lett* 1998;99:1–13.
- 4 Liu EM, Rajagopal R, Gilbert Grand M: Optic nerve atrophy and hair loss in a young man. *JAMA Ophthalmol* 2015;133:1469–1470.
- 5 Li S, Huang W, Duan Y, Xing J, Zhou Y: Human fatality due to thallium poisoning: autopsy, microscopy, and mass spectrometry assays. *J Forensic Sci* 2015;60:247–251.
- 6 Lu CI, Huang CC, Chang YC, Tsai YT, Kuo HC, Chuang YH, Shih TS: Short-term thallium intoxication: dermatological findings correlated with thallium concentration. *Arch Dermatol* 2007;143:93–98.
- 7 Zhao G, Ding M, Zhang B, Lv W, Yin H, Zhang L, Ying Z, Zhang Q: Clinical manifestations and management of acute thallium poisoning. *Eur Neurol* 2008;60:292–297.
- 8 Kuroda H, Mukai Y, Nishiyama S, Takeshita T, Tateyama M, Takeda A, Aoki M: Tardily accelerated neurologic deterioration in two-step thallium intoxication. *J Clin Neurosci* 2016;34:234–236.
- 9 Baldwin DR, Marshall WJ: Heavy metal poisoning and its laboratory investigation. *Ann Clin Biochem* 1999;36:267–300.

- 10 Kanwar AJ, Narang T: Anagen effluvium. *Indian J Dermatol Venereol Leprol* 2013;79:604–612.
- 11 Namba Y, Suzuki R, Sasaki J, Takayasu M, Watanabe K, Kenji D, Hayashi M, Kitamura Y, Kawamo M, Masaki H, Kyuuno E, Hayashi M, Yamaguchi M, Maeda A: Thallium group poisoning incident in Japan 2011. *Crit Care* 2013;17:S101.
- 12 Sachdeva S, Prasher P: Madarosis: a dermatological marker. *Indian J Dermatol Venereol Leprol* 2008;74:74–76.
- 13 Velez N, Khera P, English IJC: Eyebrow loss: clinical review. *Am J Clin Dermatol* 2007;8:337–346.
- 14 Sun TW, Xu QY, Zhang XJ, Wu Q, Liu ZS, Kan QC, Sun CY, Wang L: Management of thallium poisoning in patients with delayed hospital admission. *Clin Toxicol (Phila)* 2012;50:65–69.
- 15 Pelcova D, Urban P, Ridzon P, Senholdova Z, Lukas E, Diblik P, Lacina L: Two-year follow-up of two patients after severe thallium intoxication. *Hum Exp Toxicol* 2009;28:263–272.
- 16 Afshari R, Emadzadeh A: Short communication: case report on adulterated opium-induced severe lead toxicity. *Drug Chem Toxicol* 2010;33:48–49.
- 17 Ghaderi A, Vahdati-Mashhadian N, Oghabian Z, Moradi V, Afshari R, Mehrpour O: Thallium exists in opioid poisoned patients. *Daru* 2015;23
- 18 Neustadt J, Pieczenik S: Toxic-metal contamination: mercury. *Integr Med* 2007;6:36–37.
- 19 French LK, Burton BT, McKeown NJ: Metal for money: factitious occupational mercury exposure. *Clin Toxicol* 2011;49:587–588.
- 20 Wu ML, Deng JF, Lin KP, Tsai WJ: Lead, mercury, and arsenic poisoning due to topical use of traditional Chinese medicines. *Am J Med* 2013;126:451–454.
- 21 Ghosh A: Evaluation of chronic arsenic poisoning due to consumption of contaminated ground water in West Bengal, India. *Int J Prev Med* 2013;4:976–979.
- 22 Das SK, Nath T, Ghosal A, Jana CK: Papillon-Lefevre syndrome-like presentation in chronic arsenicosis: A rare mimicry. *Indian J Occup Environ Med* 2012;16:145–148.
- 23 Tandon A, Infeld M: Immunocompromise due to seaweed consumption (a form of arsenic poisoning). *Crit Care Med* 2013;41:A353.
- 24 Amster E, Tiwary A, Schenker MB: Case report: potential arsenic toxicosis secondary to herbal kelp supplement. *Environ Health Perspect* 2007;115:606–608.
- 25 Webb DV, Stowman AM, Patterson JW: Boric acid ingestion clinically mimicking toxic epidermal necrolysis. *J Cutan Pathol* 2013;40:962–965.
- 26 Webb A, Kerns IW: What is the origin of these nail changes in an otherwise healthy young patient? *J Med Toxicol* 2009;5:39.
- 27 Lenz M, Lens PNL: The essential toxin: The changing perception of selenium in environmental sciences. *Sci Total Environ* 2009;407:3620–3633.
- 28 MacFarquhar JK, Broussard DL, Melstrom P, Hutchinson R, Wolkin A, Martin C, Burk RF, Dunn JR, Green AL, Hammond R, Schaffner W, Jones TF: Acute selenium toxicity associated with a dietary supplement. *Arch Intern Med* 2010;170:256–261.
- 29 Aldosary BM, Sutter ME, Schwartz M, Morgan BW: Case series of selenium toxicity from a nutritional supplement. *Clin Toxicol (Phila)* 2012;50:57–64.
- 30 Dosary BM, Schwartz MD, Sutter ME, Morgan BW: Subacute selenium toxicity from a nutritional supplement. *Clin Toxicol* 2009;47:745.
- 31 Agarwal P, Sharma S, Agarwal US: Selenium toxicity: a rare diagnosis. *Indian J Dermatol Venereol Leprol* 2016;82:690–693.
- 32 Hammel C, Kyriakopoulos A, Behne D, Gawlik D, Bratter P: Protein-bound selenium in the seeds of coco de mono (*Lecythis ollaria*). *J Trace Elem Med Biol* 1996;10:96–102.
- 33 Müller D, Desel H: Acute selenium poisoning by paradise nuts (*Lecythis ollaria*). *Hum Exp Toxicol* 2010;29:431–434.
- 34 Finkelstein Y, Aks SE, Hutson JR, Juurlink DN, Nguyen P, Dubnov-Raz G, Pollak U, Koren G, Bentur Y: Colchicine poisoning: the dark side of an ancient drug. *Clin Toxicol (Phila)* 2010;48:407–414.
- 35 Bismuth C, Gaultier M, Conso F: Medullary aplasia after acute colchicine poisoning. 20 cases (in French). *Nouv Presse Med* 1977;6:1625–1629.
- 36 Bismuth C, Baud F, Dally S: Standardized prognosis evaluation in acute toxicology its benefit in colchicine, paraquat and digitalis poisonings. *J Toxicol Clin Exp* 1986;6:33–38.
- 37 Senthilkumaran S, Balamurugan N, Rajesh N, Thirumalaikolundusubramanian P: Hard facts about loose stools – massive alopecia in *Gloriosa superba* poisoning. *Int J Trichology* 2011;3:126–127.
- 38 Guven AG, Bahat E, Akman S, Artan R, Erol M: Late diagnosis of severe colchicine intoxication. *Pediatrics* 2002;109:971–973.
- 39 Levsky ME, Miller MA, Masneri DA, Borys D: Colchicine exposures: the Texas experience. *South Med J* 2008;101:480–483.
- 40 Folpini A, Furfuri P: Colchicine toxicity – clinical features and treatment. Massive overdose case report. *J Toxicol Clin Toxicol* 1995;33:71–77.
- 41 Alaygut D, Kilic SC, Kaya A, Oflaz MB, Bolat F, Cevit O, Icgasioglu FD: Assessment of 17 pediatric cases with colchicine poisoning in a 2-year period. *Pediatr Emerg Care* 2016;32:168–172.
- 42 Combalia A, Baliu-Pique C, Fortea A, Ferrando J: Anagen effluvium following acute colchicine poisoning. *Int J Trichology* 2016;8:171–172.
- 43 Biçer S, Soysal DD, Çitak A, Üçsel R, Karaböcüoğlu M, Uzel N: Acute colchicine intoxication in a child: a case report. *Pediatr Emerg Care* 2007;23:314–317.
- 44 Fernando R, Fernando DN: Poisoning with plants and mushrooms in Sri Lanka: a retrospective hospital based study. *Vet Hum Toxicol* 1990;32:579–581.
- 45 Premaratna R, Weerasinghe MS, Premawardana NP, de Silva HJ: *Gloriosa superba* poisoning mimicking an acute infection – a case report. *BMC Pharmacol Toxicol* 2015;16:27.
- 46 Sommer A, Vyas KS: A global clinical view on vitamin A and carotenoids. *Am J Clin Nutr* 2012;96:1204S–1206S.
- 47 Bendich A: The safety of beta-carotene. *Nutr Cancer* 1988;11:207–214.
- 48 Miksad R, de Ledinghen V, McDougall C, Fiel I, Rosenberg H: Hepatic hydrothorax associated with vitamin A toxicity. *J Clin Gastroenterol* 2002;34:275–279.
- 49 O'Donnell J: Polar hysteria: an expression of hypervitaminosis A. *Am J Ther* 2004;11:507–516.
- 50 Kowing D: Madarosis and facial alopecia presumed secondary to botulinum a toxin injections. *Optom Vis Sci* 2005;82:579–582.
- 51 Di Pietro A, Piraccini BM: Frontal alopecia after repeated botulinum toxin type A injections for forehead wrinkles: an underestimated entity? *Skin Appendage Disord* 2016;2:67–69.
- 52 Kim HN, Do HH, Seo JS, Kim HY: Two cases of incidental *Podostroma cornu-damae* poisoning. *Clin Exp Emerg Med* 2016;3:186–189.
- 53 Ahn JY, Seok SJ, Song JE, Choi JH, Han SH, Choi JY, Kim CO, Song YG, Kim JM: Two cases of mushroom poisoning by *Podostroma cornu-damae*. *Yonsei Med J* 2013;54:265–268.
- 54 Natsuka K, Nakamura H, Uno H, Umemoto S: Studies on 1-substituted 4-(1,2-diphenylethyl)piperazine derivatives and their analgesic activities. 1. *J Med Chem* 1975;18:1240–1244.
- 55 Nakamura M, Hachiya N, Murata KY, Nakanishi I, Kondo T, Yasutake A, Miyamoto K, Ser PH, Omi S, Furusawa H, Watanabe C, Usuki F, Sakamoto M: Methylmercury exposure and neurological outcomes in Taiji residents accustomed to consuming whale meat. *Environ Int* 2014;68:25–32.
- 56 Helander A, Bradley M, Hasselblad A, Norlen L, Vassilaki I, Backberg M, Lapins J: Acute skin and hair symptoms followed by severe, delayed eye complications in subjects using the synthetic opioid MT-45. *Br J Dermatol* 2017;176:1021–1027.
- 57 Mulkey JP, Oehme FW: A review of thallium toxicity. *Vet Hum Toxicol* 1993;35:445–453.
- 58 Rahman MM, Chowdhury UK, Mukherjee SC, Mondal BK, Paul K, Lodh D, Biswas BK, Chanda CR, Basu GK, Saha KC, Roy S, Das R, Palit SK, Quamruzzaman Q, Chakraborti D: Chronic arsenic toxicity in Bangladesh and West Bengal, India – a review and commentary. *J Toxicol Clin Toxicol* 2001;39:683–700.
- 59 Moseman RF: Chemical disposition of boron in animals and humans. *Environ Health Perspect* 1994;102(suppl 7):113–117.

- 60 Schillinger BM, Berstein M, Goldberg LA, Shalita AR: Boric acid poisoning. *J Am Acad Dermatol* 1982;7:667–673.
- 61 Forceville X, Laviolle B, Annane D, Vitoux D, Bleichner G, Korach JM, Cantais E, Georges H, Soubirou JL, Combes A, Bellissant E: Effects of high doses of selenium, as sodium selenite, in septic shock: a placebo-controlled, randomized, double-blind, phase II study. *Crit Care* 2007;11:R73.
- 62 Ben-Chetrit E, Levy M: Colchicine: 1998 update. *Semin Arthritis Rheum* 1998;28:48–59.
- 63 Troost BT: Botulinum toxin type A (Botox) in the treatment of migraine and other headaches. *Expert Rev Neurother* 2004;4:27–31.
- 64 Curto-Barredo L, Segura S, Martin-Ezquerria G, Lloveras B, Gallardo F, Pujol RM: Anagen effluvium due to thallium poisoning derived from the intake of Chinese herbal medicine and rodenticide containing thallium salts. *J Dermatol* 2015;42:1027–1029.
- 65 Campbell C, Bahrami S, Owen C: Anagen effluvium caused by thallium poisoning. *JAMA Dermatol* 2016;152:724–726.
- 66 Pelclova D, Farna H, Vlckova S, Caganova B, Plackova S, Zakharov S: International cooperation in treatment of suicidal thallium intoxication. *Clin Toxicol* 2012;50:300.
- 67 Apostolova D, et al: Criminal thallium poisoning: a case series. *Clin Toxicol* 2013;51:358.
- 68 Center for Disease Control and Prevention (CDC): Thallium poisoning from eating contaminated cake – Iraq, 2008. *MMWR Morb Mortal Wkly Rep* 2008;57:1015–1018.
- 69 Ostapenko YN, et al: Case of mass thallium poisoning in a factory. *Clin Toxicol* 2009;47:491.
- 70 Sojakova M, Zigray M, Karaman A, Plackova S, Klepancova P, Hrusovsky S: Thallium intoxication. Case report. *Neuro Endocrinol Lett* 2005;36:311–315.
- 71 Yumoto T, Tsukahara K, Naito H, Iida A, Nakao A: A successfully treated case of criminal thallium poisoning. *J Clin Diagn Res* 2017;11:OD01–OD02.
- 72 Manzanares W, Hardy G: Can dietary selenium intake increase the risk of toxicity in healthy children? *Nutrition* 2016;32:149–150.
- 73 Sutter ME, Thomas JD, Brown J, Morgan B: Selenium toxicity: a case of selenosis caused by a nutritional supplement. *Ann Intern Med* 2008;148:970–971.
- 74 Kande Vidanalage CJ, Ekanayeka R, Wijewardange DK: Case report: a rare case of attempted homicide with *Gloriosa superba* seeds. *BMC Pharmacol Toxicol* 2016;17:26.