

UC San Diego

UC San Diego Previously Published Works

Title

Mature Cystitic Teratoma of the Bladder Masquerading as a Distal Ureteral Stone

Permalink

<https://escholarship.org/uc/item/7p7696q8>

Authors

Omar, Mohamed
El-Gharabawy, Mohamed
Samir, Ahmed
et al.


Publication Date

2017-07-01

DOI

10.1016/j.eucr.2017.01.004

Peer reviewed



Oncology

Mature Cystic Teratoma of the Bladder Masquerading as a Distal Ureteral Stone



Mohamed Omar^{a,*}, Mohamed El-Gharabawy^b, Ahmed Samir^b, Eid El sherif^b,
Manoj Monga^a

^a Glickman Urology & Kidney Institute – Cleveland Clinic Foundation, Cleveland, OH, USA

^b Menofya Urology Department – Menofya University, Menofya, Egypt

ARTICLE INFO

Article history:

Received 12 December 2016

Accepted 10 January 2017

Keywords:

Mature teratoma

Ureteral stone

Bladder

ABSTRACT

A 27-year woman presented with irritative lower urinary tract symptoms and alleged small right distal ureteric stone that had been diagnosed with KUB and non-contrast spiral CT.

Patient was scheduled for ureteroscopic lithotripsy, revealing absence of the presumed stone, while cystoscopy showed unexpected 2 cm pedunculated grayish white lesion, situated on the right lateral wall of the bladder with sparse hairs covering it.

An incomplete TURBT was done; the histological findings correlated with the gross picture seen on cystoscopy.

Following CT urography, the patient went an open partial cystectomy and right oophorectomy; the histopathology was consistent with mature bladder teratoma.

© 2017 Published by Elsevier Inc. This is an open access article under the CC BY-NC-ND license (<http://creativecommons.org/licenses/by-nc-nd/4.0/>).

Introduction

Teratomas are germ cell tumors, derived from all of the three primitive layers of the embryo. Teratomas produce tissues foreign to the site from which they arise; their most frequent location of occurrence is in the ovaries but may also be found at other sites, rarely, they may occur in the urinary bladder.¹

Mature teratoma is a benign tumor that usually occurs between the ages of ten to thirty, and rarely occurs in the postmenopausal age group; they demonstrate well-differentiated tissue such as sebaceous glands, hair and teeth; however immature teratomas are malignant. Their presentation is primarily unilateral and asymptomatic until they grow to a significant size or cause complications.

They are usually found incidentally, during clinical examination, imaging studies, or abdominal operations performed for a non-related indication. When symptoms present, they vary according to the occupying organ, which may include: abdominal pain, swelling, and abnormal organ function. When they arise from the bladder, symptoms range from irritative lower urinary tract symptoms, up to urinary retention.²

Here, we present a case of a mature teratoma of the urinary bladder in a 27-year old woman, which was mimicking a lower ureteric stone.

Case report

A 27-year old woman presented with a 4 month history of dysuria and irritative lower urinary tract symptoms: frequency, nocturia, urgency, and urge incontinence. She denied symptoms of hematuria or loin pain. There was no relevant past medical history of ovulation induction, nor any family history of ovarian or breast malignancies.

No remarkable findings were seen on physical examination, except for a pfannenstiel incision scar, correlating with a surgical history of a lower segment caesarian section 1 year ago. Urinalysis and urine culture were within normal limits, as well as all other routine laboratory work up.

Past medical history revealed a similar attack 4 months ago; the patient sought medical attention at an outside institution. There, a Kidney, Ureters and Bladder X-Ray (KUB) was obtained, which showed a 1 cm radio-opaque shadow just above the anatomical site of the right uretero-vesical junction (Fig. 1). Ultrasonography of the abdomen showed no evidence of hydronephrosis or any other abnormality. Thus, she was diagnosed with a right lower ureteric stone and prescribed medical expulsive therapy (MET) in form of an alpha blocker.

* Corresponding author. Glickman Urology & Kidney Institute, The Cleveland Clinic, 9500 Euclid Avenue, Q10-1, Cleveland, OH 44195, USA.

E-mail address: kimo_81eg@yahoo.com (M. Omar).

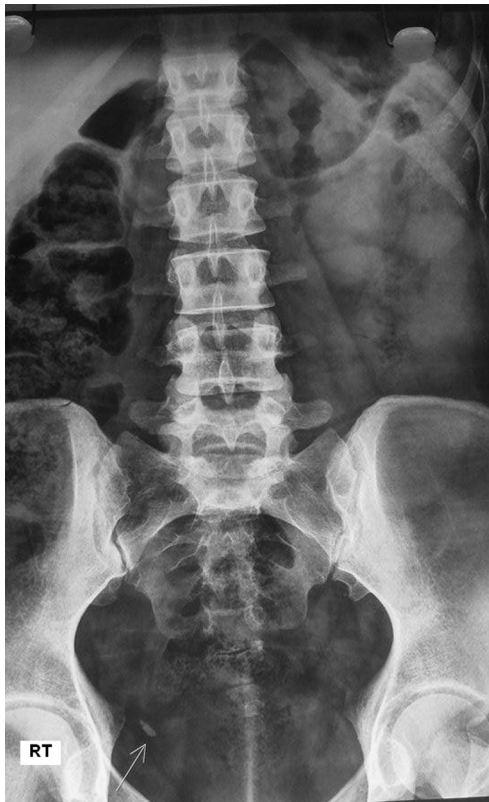

Figure 1. KUB showing a radiopaque 1 cm lesion in right uretero-vesical junction area.

Upon consultation, we ordered a non-contrast helical CT, which confirmed the established diagnosis (Fig. 2). The somewhat antero-lateral location of the calcification raised the suspicion that this may represent a calculus in an ureterocele; suggesting the reason for failed MET. Subsequently we offered the patient ureteroscopic lithotripsy indicated by previously failed medical therapy.

The right ureteric orifice was identified and guide wire introduced, under fluoroscopic guidance followed by ureteroscopy revealing absence of the presumed stone while the radiopaque shadow did not change its place. Surprisingly, a preliminary diagnostic cystoscopy revealed a 2 cm rounded, whitish lesion, arising from the right lateral wall of the bladder with a stalk like base and

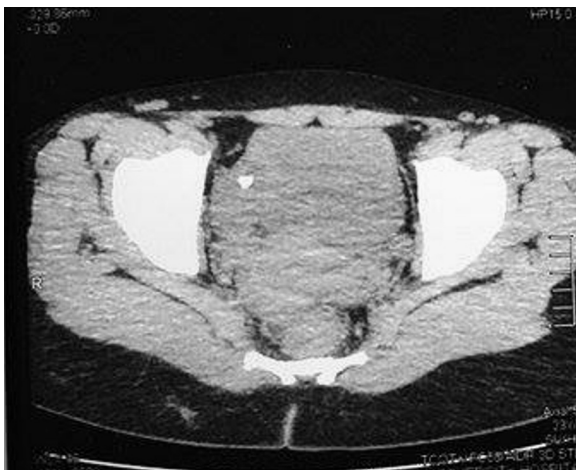

Figure 2. Axial non contrast CT showing the radiopaque content of the teratoma (tooth).

covered by sparse hairs in the same place of the radio-opaque shadow on fluoroscopy. An incomplete transurethral resection of the lesion was performed, and histological examination correlated with the clinical picture of mature teratoma.

Two weeks later, after a CT urogram the patient underwent a partial cystectomy, the mass was excised with a 1 cm safety margin, a right oophorectomy was performed for an indurated cystic ovary connected to the mass by a stalk. No pelvic lymph node enlargement was evident. No other abnormalities were detected on visual examination of all the other intra-abdominal organs. The patient's recovery was uneventful, and she was discharged 3 days later while an indwelling urethral catheter was left to be removed on the 7th POD. A follow up cystoscopy 6 months later was unremarkable and she currently remains symptom free for 14 months.

Gross examination of the resected lesion revealed a single, sessile, pedunculated, whitish-colored mass, measuring about 2 by 2 cm arising from the right lateral wall of the bladder, covered with a tuft of hair. The rest of the bladder specimen was normal. Histological examination revealed a cyst, lined by keratinized stratified squamous epithelium with focal ulceration, overlying a florid granulomatous inflammatory reaction identified as tooth. Hair follicles and scattered sebaceous glands were also observed throughout the lesion (Fig. 3). No gross or histological abnormalities were detected on pathological examination of the resected ovary.

Discussion

Mature cystic ovarian teratoma is the most common germ cell tumor, it is found predominantly in young women, and presents at a median age of 30 years. At a slow growing rate, averaging 1.8 mm each year, it can go unnoticed for a long time. Mature cystic teratomas require removal and can be treated by a simple cystectomy.

Uncomplicated dermoid cysts are often asymptomatic, dependent on their size, as well as the occupied organ. Reported complications include ovarian torsion (16%), rupture (1–4%), malignant transformation (1–2%), infection (1%), invasion into adjacent viscera and autoimmune hemolytic anemia (<1%).³

Most mature cystic teratomas can be diagnosed by Ultrasonography (US). However, numerous pitfalls have been described in this diagnostic modality; this is complicated by the fact that these tumors may have a variety of appearances. In a prospective study, Mais et al reported a sensitivity of 58% and, specificity of 99% in diagnosing a mature cystic teratoma by US.⁴

A review of the literature revealed numerous case reports of urinary bladder teratomas, with diameters ranging between 5 and

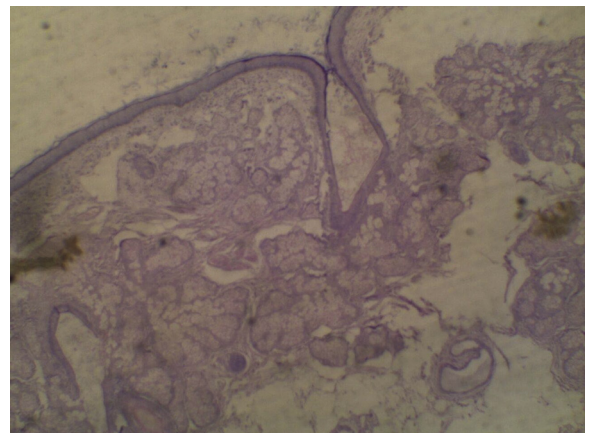


Figure 3. Stratified squamous epithelium, hair follicle, sweat and sebaceous gland.

12 cm.⁵ The teratoma reported here, measured 2 cm, making detection by ultrasound more difficult. To our knowledge, this is the first report of a teratoma masquerading as a ureteral calculus.

The diagnosis of mature cystic teratoma by Computed Tomography (CT) and Magnetic Resonance (MR) imaging is fairly straightforward, because these modalities are more sensitive in the detection of fat. On CT imaging, fat attenuation within a cyst, with or without calcification of the wall, is a diagnostic feature of mature cystic teratoma.

Although Adipose tissue is present in 67–75% of cases of mature teratoma, and teeth are seen in 31%, the classic imaging characteristics of fat attenuation were not appreciated on our non-contrast CT images even when we retrospectively reviewed it.

Conclusion

A small bladder teratoma located in proximity to the ureteric orifice could, clinically and radiologically, mimic the presentation of a lower ureteric stone.

Conflict of interest statement

No competing financial interests exist.

Acknowledgments

None.

References

1. Linus IO, Gabriel O, Blessing R, et al. Dermoid cyst of the urinary bladder as a differential diagnosis of bladder calculus: a case report. *J Med Case Rep.* 2007;1:32.
2. Cislo M, Reszczyński A. Perforation of dermoid cyst of the ovary into the urinary bladder. *Ginekol Pol.* 1962;33:595–600.
3. Park SB, Kim JK, Kim KR, Cho KS. Imaging findings of complications and unusual manifestations of ovarian teratomas. *Radiographics.* 2008;28:969–983.
4. Mais V, Guerriero S, Ajossa S, et al. Transvaginal ultrasonography in the diagnosis of cystic teratoma. *Obstet Gynecol.* 1995;85:48–52.
5. Tandon A, Gulleria K, Gupta S. Mature ovarian dermoid cyst invading the urinary bladder. *Ultrasound Obstet Gynecol.* 2010;35:751–753.