

UC Davis

Dermatology Online Journal

Title

Generalized Bullous Fixed Drug Eruption due to Bromhexine

Permalink

<https://escholarship.org/uc/item/7nt074w4>

Journal

Dermatology Online Journal, 22(7)

Authors

Vide, J
Moreira, C
Cunha, A. P.
[et al.](#)

Publication Date

2016

DOI

10.5070/D3227031650

Copyright Information

Copyright 2016 by the author(s). This work is made available under the terms of a Creative Commons Attribution-NonCommercial-NoDerivatives License, available at <https://creativecommons.org/licenses/by-nc-nd/4.0/>

Peer reviewed

Caset Presentation

Generalized Bullous Fixed Drug Eruption due to Bromhexine

J. Vide¹; C. Moreira¹; A. P. Cunha¹; H. Baldaia²; S. Magina^{1,3}; F. Azevedo¹

Dermatology Online Journal 22 (7): 13

¹Department of Dermatology and Venereology, Centro Hospitalar de São João EPE, Porto, Portugal;

²Department of Pathology, Centro Hospitalar de São João EPE, Porto, Portugal;

³Faculty of Medicine of Porto University, Portugal

Keywords: Drug Eruptions; Adverse Drug Reaction; Bullous Skin Diseases; Bromhexine; Patch Tests

Corresepndence:

Júlia Vide
Rua Camilo Sousa Santos, 124, 3C
00351916306747
Email: juliavide@gmail.com

Abstract

We describe a patient with a generalized bullous form of Fixed Drug Eruption (FDE) induced by bromhexine, a commonly used drug for respiratory symptoms. This is a rare association and generalized bullous FDE is also very rare. We emphasize the importance of patch tests in identifying the culprit drug.

Introduction

Several well known medications are implicated in the majority of fixed drug eruptions. These include antibiotics (especially sulphonamides and tetracyclines) and nonsteroidal anti-inflammatory drugs [1, 2]. Herein we describe a patient with a generalized bullous form of Fixed Drug Eruption (FDE) induced by bromhexine, a commonly used drug for respiratory symptoms. Dermatologic adverse reactions related to bromhexine include urticaria, angioedema, and anaphylaxis [3]. There are no reported cases of FDE triggered by bromhexine.

Case synopsis

A 60-year-old man presented to our department with multiple erythematous and violaceous well-demarcated patches and plaques that had erupted 3 days prior. Most were round in shape and exhibited bullae. They were located on the trunk, lower limbs, and genital skin; he had no other symptoms.

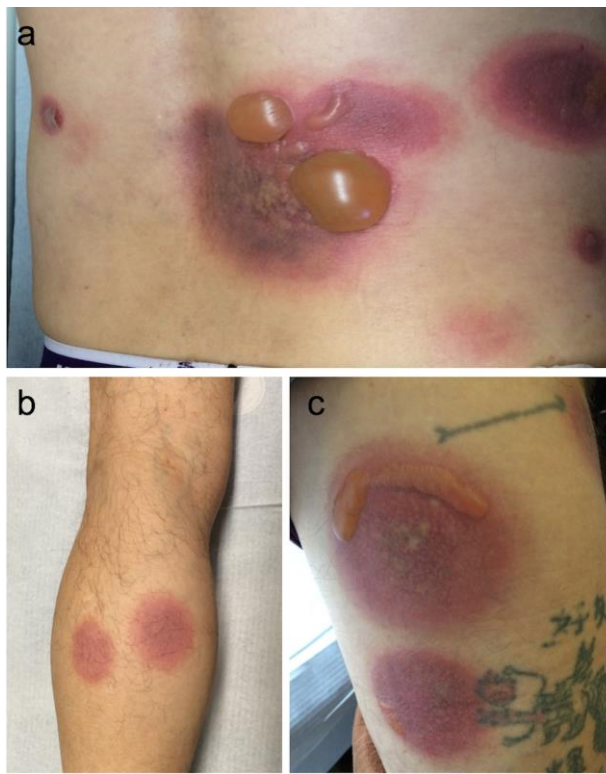

Figure 1. Well-defined erythematous-violaceous patches with bulla over the back (a), legs (b) and thighs (c).

He noted five identical episodes since October 2012, with lesions always appearing in the same spots; three of the episodes occurred after being treated for upper respiratory infections. The eruptions generally resolved spontaneously and turned brownish. The patient's medical history was relevant for asthmatic bronchitis, for which he was treated with daily oral montelukast since 2010. Sporadically, in the past two years, he also took paracetamol, ibuprofen, naproxen, diclofenac, hydroxyzine, ciprofloxacin, levofloxacin, bromhexine, loperamide, and simethicone. After a cutaneous biopsy was performed, he was treated with a short regimen of oral prednisolone (0,5mg/kg/day).

Histopathologic evaluation disclosed an interface dermatitis with eosinophils and a few neutrophils, dermal edema, vacuolar changes, and *Civatte* bodies.

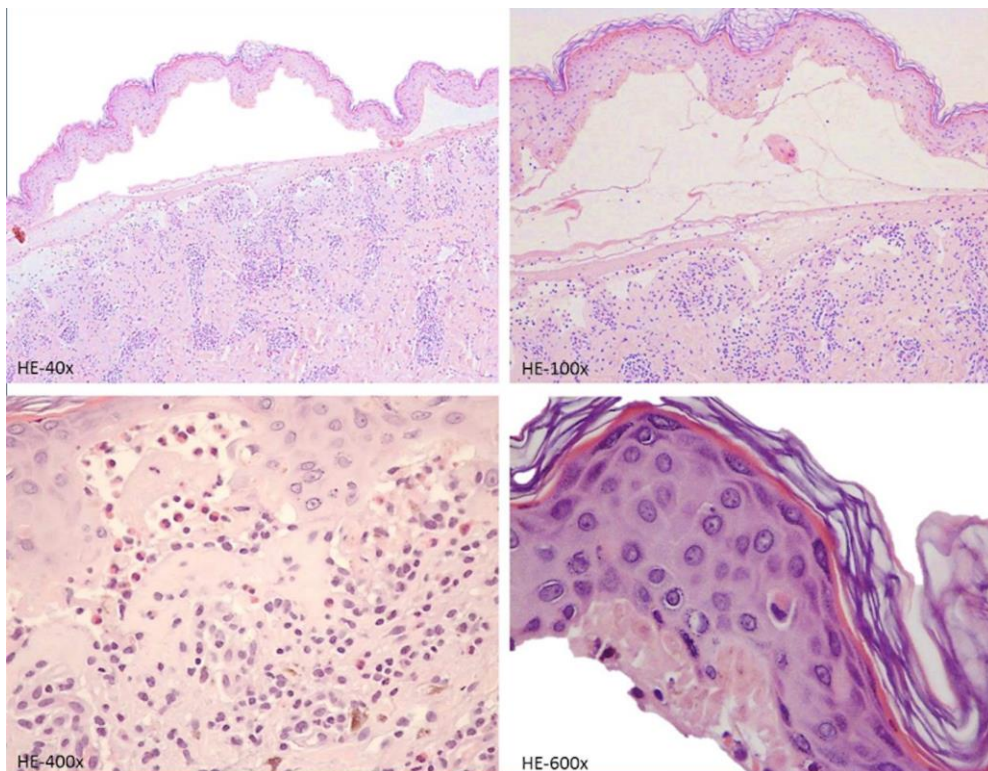


Figure 2. Acute interface dermatitis with prominent vacuolar change and individual necrotic keratinocytes within the epidermis (*Civatte* bodies).

The diagnosis of FDE was confirmed on the basis of clinical and histologic findings. In a quiescent phase, patch tests were performed with all the sporadically taken drugs applied in the residual lesions. Strongly positive results to bromhexine 1% and 5% in petrolatum at 48 hours were documented; they appeared as itchy elevated red papules with vesicles. Standard European series patch tests in nonlesional skin were negative. The patient was advised to avoid bromhexine and, after its suspension, no more episodes have been reported to date. The patient has continued the sporadic use of paracetamol, non-steroidal anti-inflammatory drugs, and antibiotics without eruption.

Discussion

FDE is considered a form of delayed-type hypersensitivity, which may account for as many as 10% of all cutaneous drug eruptions [4].

Making the diagnosis relies upon the history and clinical examination, with special attention to a detailed drug review. The patient should be asked about over the counter medications; these may be common culprits as in this case. Bromhexine is authorized in 29 European countries and it is present, for example, in Bisolvon®, Robitussin®, and Bisolmed®, commonly used as expectorants and for sore throat. As patients are often on multiple drug regimens, it is sometimes difficult to identify the responsible agent solely on chronological criteria and pinpoint the relevant drug from history alone. Unlike oral provocative tests, patch testing *in situ* represents a low-risk diagnostic test. This technique can reproduce delayed hypersensitivity to drugs and presents only a moderate and local re-exposure to the offending agents. Another advantage is the option to study several drugs at the same time. When the drug involved is not clear, patch tests with the suspected drugs on a previously affected site may be helpful, being positive in 40% of the cases [5].

References

1. Mahboob A, Haroon TS. Drugs causing fixed eruptions: a study of 450 cases. *Int J Dermatol*. 1998 Nov;37(11):833-8. [PMID: 9865869]
2. Savin JA. Current causes of fixed drug eruption in the UK. *Br J Dermatol*. 2001 Oct;145(4):667-8. [PMID: 11703300]
3. van Riemsdijk MM, van der Klauw MM, Stricker BH, Herings RM. [Skin reactions attributed to the use of bromhexine]. *Ned Tijdschr Geneeskd*. 1994 Dec 3; 138(49): 2446-8. Dutch. [PMID: 7997301]
4. Mizukawa Y, Yamazaki Y, Shiohara T. In vivo dynamics of intraepidermal CD8+ T cells and CD4+ T cells during the evolution of fixed drug eruption. *Br J Dermatol*. 2008 Jun;158(6):1230-8. [PMID: 18363767]
5. Barbaud A. Skin testing and patch testing in non-IgE-mediated drug allergy. *Curr Allergy Asthma Rep*. 2014 Jun;14(6):442. [PMID: 18363767]