

UCSF

UC San Francisco Previously Published Works

Title

Ischemic Fasciitis Mimicking A Lipoma

Permalink

<https://escholarship.org/uc/item/7nd414gr>

Journal

Dermatologic Surgery, Publish Ahead of Print(&NA;)

ISSN

1076-0512

Authors

Saeed, Lina
Bahrani, Eman
Lauw, Marietya IS
et al.

Publication Date

2020-03-01

DOI

10.1097/dss.0000000000001853

Peer reviewed

advanced and proven technique to maximize and improve age-related volume loss.³

The same principles are true for buccal fat pad repositioning because the aesthetic implications of addressing Bichat's fat pad have been well documented, and the safest approaches to address this fat pad surgically are founded upon techniques aimed at its aesthetic reduction and removal.⁴

This article serves as a great motivator to urge reconstructive surgeons to continue using and making themselves aware of cosmetic principles to expand their reconstructive repertoire. Documenting such applications, as the authors did here, also helps improve the safety of access and surgical approaches for both reconstructive and cosmetic purposes. Specifically, I applaud the authors' use of ultrasound in this study to provide an objective measurement of the durability in using these fat transposition techniques as support to contour overlying soft tissues.¹ As one starts to implement these types of fat transposition techniques, referencing the aesthetic literature is the most fruitful way to optimize invested time and effort to ensure adequate and safe access to these fat pad reservoirs. Finally, I hope this

Ischemic Fasciitis Mimicking A Lipoma

Ischemic fasciitis is a rare benign fibroplasia that occurs in immobile elderly patients because of persistent pressure on bony prominences or in patients with a recent history of trauma. It can clinically resemble malignant entities, including epithelioid sarcomas, the diagnosis of which must be excluded. We present a case of an elderly gentleman who presented to the dermatologic surgery excision clinic for a routine lipoma excision but was ultimately found to have ischemic fasciitis. Dermatologic surgeons should consider ischemic fasciitis in the correct clinical setting for appropriate management.

A 95-year-old gentleman with a history of gout, non-melanoma skin cancer, and psoriasis presented to the emergency department following a fall and was incidentally found to have a subcutaneous mass overlying the right posterior deltoid. The patient was unsure whether

article inspires other reconstructive dermatologic surgeons to explore and publish further connections with aesthetic surgery because there are many more yet unexplored and unapplied concepts that we can use to simply and safely progress the results that our colleagues in all reconstructive specialties are able to achieve.

References

1. Kyung W; Ahn CH, Lew DH; Song SH. Pedicled fat pad used to prevent facial depression following the excision of a soft tissue mass. *Dermatol Surg* 2020;46:424–6.
2. Goldberg RA, Lessner AM, Shorr N, Baylis HI. The transconjunctival approach to the orbital floor and orbital fat: a prospective study. *Ophthalmic Plast Reconstr Surg* 1990;6:241–6.
3. Yoo DB, Peng GL, Massry GG. Effacing the orbitolabellar groove with transposed upper eyelid fat. *Ophthalmic Plast Reconstr Surg* 2013;29:220–4.
4. Kim JT, Sasidaran R. Buccal fat pad: an effective option for facial reconstruction and aesthetic augmentation. *Aesthetic Plast Surg* 2017;41:1362–74.

CAMERON CHESNUT, MD, FAAD, FASDS, FACMS
*University of Washington School of Medicine
Spokane, Washington*

The author has indicated no significant interest with commercial supporters.

the mass was new or had gradually developed; it was nontender and did not appear bruised or inflamed. He was referred to the dermatologic surgery excision clinic for removal of presumed cyst or lipoma. No further imaging studies were performed after head and cervical spine computed tomography scans were negative for acute findings. When he presented to the excision clinic 3 weeks later, physical examination revealed a thin, elderly patient with a round 5 × 3.5-cm soft and rubbery subcutaneous nodule overlying the right deltoid that was mobile and nontender. No erythema, epidermal changes, or lymphadenopathy was appreciated. He felt well and denied new symptoms. Other skin findings included actinic purpura on the bilateral forearms. The mass was presumed to be a lipoma, and the patient elected to have the mass surgically removed. During the procedure, little fat was appreciated subcutaneously. No lipoma or cyst was found in the dermis, but a firm, fibrotic mass was

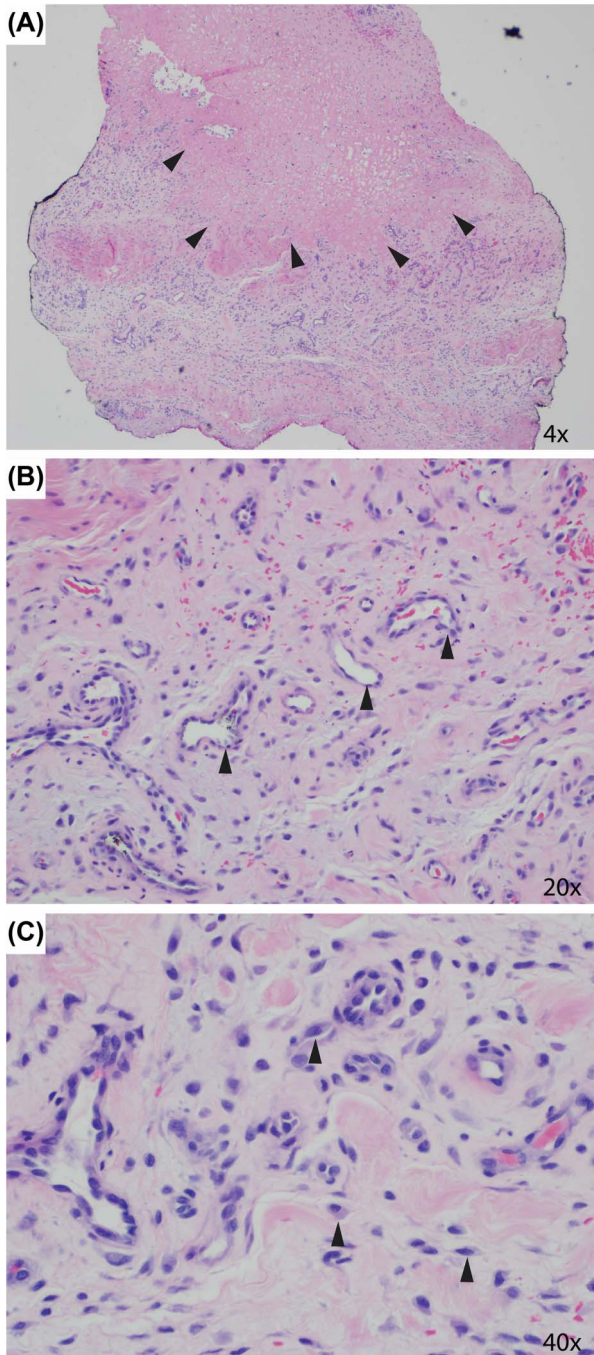


Figure 1. The biopsy showed a central area of fibrinoid degeneration/necrosis outlined by arrowheads (A) surrounded by granulation tissue-like vascular proliferation (B, see arrowheads). Plump, reactive, proliferating fibroblasts (C, see arrowheads) were seen in the stroma along with macrophages and extravasated erythrocytes (B and C).

identified deep to the fascia, clinically concerning for a soft-tissue sarcoma. A 4-mm punch biopsy was made through the fascia into the deeper tissue for diagnosis, and the incision was closed primarily in a layered fashion.

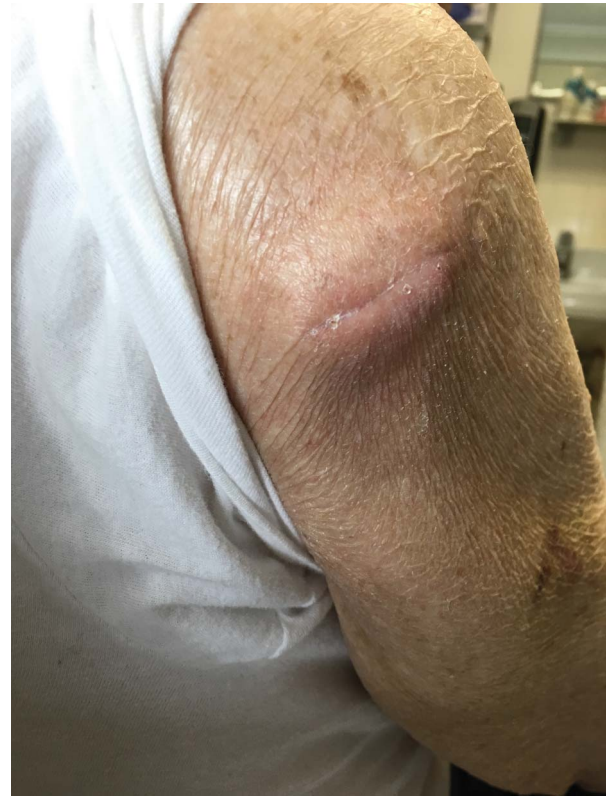

Figure 2. The mass 2 months after initial biopsy. It had regressed from 5 × 3.5 cm to 4 × 3 cm, and the overlying incision was healing well.

The biopsy showed a lesion located in the deep subcutis, composed of a central hypocellular zone of fibrinoid degeneration/necrosis surrounded by granulation tissue-like vascular proliferation (Figure 1A,B). Myxoid change and fat atrophy were seen in the surrounding tissue. Plump, reactive, and proliferating fibroblasts were seen in the stroma along with macrophages and extravasated erythrocytes (Figure 1B,C). Mitotic figures were rare, and atypical mitotic figures were absent. The differential diagnosis based on the clinical history and histopathology included ischemic fasciitis, nodular fasciitis, and epithelioid sarcoma. The latter was excluded by negative pankeratin immunohistochemical stain as well as lack of atypia and tumor cell necrosis and minimal mitotic figures. Ischemic fasciitis was favored over conventional nodular fasciitis because of the presence of central fibrinoid degeneration/necrosis.

When the patient was seen in the clinic 2 months later, he denied pain, growth, or new symptoms at the biopsy

site, and review of systems was negative. The mass had reduced in size to 4 × 3 cm with a well-healed overlying linear scar (Figure 2). The patient and family declined further procedures, imaging, or consultations with other specialists because of his age and comorbidities. The patient will be clinically monitored for new symptoms or recurrence in the dermatology clinic.

Ischemic fasciitis is a rare, benign pseudosarcomatous proliferation of atypical fibroblasts believed to be a result of persistent or recurring pressure leading to ischemia of the soft tissue and subsequent abnormal healing.¹⁻³ It can present clinically as a painless nodule or mass typically overlying bony prominences, most commonly found over the sacrum, limb girdles, hips, and shoulders.² Most cases are present in elderly, immobilized, or debilitated patients, usually in their seventies or eighties, or in patients with a recent history of trauma.² The low recurrence rate after partial or complete excision suggests a reactive rather than a malignant or neoplastic process.³ Although cases in younger individuals have been described, such occurrences are very rare.³

In a study conducted by Liegel and Fletcher,³ 14 lesions were grossly described and found to be white-yellow masses with central necrosis and variable cystic and/or hemorrhagic areas. Masses ranged from 1.3 to 10 cm in size.³ Microscopically, these lesions usually involve the deep subcutis but can infiltrate surrounding structures including the muscle, tendinous tissue, or reticular dermis. Within the mass, ischemic fasciitis is classically characterized by central zone of fibrinoid necrosis, cystic degeneration, and hypocellularity with surrounding granulation tissue.^{2,3} Reactive swollen fibroblasts and myofibroblasts, fat necrosis, macrophages, myxoid changes, and reactive vasculature are often appreciated in the peripheral zones.^{1,3} Presence of fat necrosis and lack of atypical mitotic figures and dense hypercellularity are reassuring and help differentiate ischemic fasciitis from sarcoma. Immunohistochemistry can further confirm the diagnosis. The presence of fibroblasts and fibroblast-like cells will be reactive for smooth muscle actin, CD68, and possibly CD34, indicating enlarged fibroblasts.³ Keratin and S100 stains are negative.³ Differentiating between ischemic fasciitis and subcutaneous granuloma annulare (SGA), a poorly defined subcutaneous mass seen

in young patients on the lower extremities, is performed through histology: SGA demonstrates a basophilic stain due to the presence of mucin and inflammatory cells, as opposed to the eosinophilic staining consistent with ischemic fasciitis.

Clinically, ischemic fasciitis typically presents as a circumscribed, subcutaneous, mobile, and non-tender mass. The overlying epidermis is often elevated without color changes; however, some erythema is not uncommon.¹ Magnetic resonance imaging will reveal the classic zonation of ischemic fasciitis as described above, with a low signal center consistent with the ischemic and devitalized tissue.

The mainstay of treatment for ischemic fasciitis is conservative local excision because these masses can be disfiguring or uncomfortable depending on their location.¹ Recurrence of these lesions is uncommon, and patients are counseled on potentially causal activities or postures.¹ Conservative treatment and educating patients on behavior modification can lead to regression of the mass.¹

This case highlights the broad differential for ischemic fasciitis and distinctive histopathologic characteristics that differentiate it from other clinical mimickers. It is prudent for dermatologic surgeons to consider ischemic fasciitis in elderly patients presenting with a subcutaneous nodule over a bony prominence with a recent history of blunt trauma.

References

1. Lehmer LM, Moore JB, Ragsdale BD. Ischemic fasciitis: enhanced diagnostic resolution through clinical, histopathologic and radiologic correlation in 17 cases. *J Cutan Pathol* 2016;43:740-8.
2. Sayeed SM, Tyrell R, Glickman LT. Management of recurrent ischemic fasciitis, a rare soft tissue pseudosarcoma. *Arch Plast Surg* 2014;41:89-90.
3. Liegel B, Fletcher C. Ischemic fasciitis: analysis of 44 cases indicating an inconsistent association with immobility or debilitation. *Am J Surg Pathol* 2008;32:910:1546-52.

LINA SAEED, BS
Department of Dermatology
School of Medicine
University of California San Francisco
San Francisco, California

EMAN BAHRANI, MD
Department of Dermatology
University of California San Francisco
San Francisco, California

MARIETYA I.S. LAUW, MD
 Z. LAURA TABATABAI, MD
Department of Pathology
University of California San Francisco
San Francisco, California

SARAH T. ARRON, MD, PhD
 THEODORA M. MAURO, MD
Department of Dermatology
University of California San Francisco
San Francisco, California

The authors have indicated no significant interest with commercial supporters.

Treatment of Patchy and Universalis Alopecia Areata With Fractional Laser

Alopecia areata (AA) is a chronic and relapsing autoimmune disorder characterized by patchy nonscarring hair loss. It is the second most common cause of alopecia affecting 1% to 2% of the population. Alopecia areata can cause serious psychosocial distress and impact on quality of life. Localized patchy hair loss may recover spontaneously. However, more severe forms such as alopecia totalis or universalis have poor prognosis; spontaneous remission is unlikely and are usually resistant to therapy.

Conventional medical treatments are usually unsatisfactory for extensive cases and relapse rates are high. Current first-line treatments include the following: intralesional or topical corticosteroids for mild cases and systemic steroids or topical immunotherapy with diphenylcyclopropenone in severe cases. Other therapies are topical calcineurin inhibitors, minoxidil, phototherapy, cyclosporine, and methotrexate among others.¹ Photodynamic therapy seems to be ineffective. These alternative treatments have variable results and can produce adverse events. New directions include laser therapies. We report one case of universalis AA and 6 of resistant patchy AA treated with fractional laser.

We present 19 patches of AA (6 patients) and a patient with diffuse universalis AA. Patients ranged in age from 31 to 63 years (mean 47 years, median 41 years). The median disease duration was 7 months (range 4 months–22 years). Most of the cases reported were long-standing and resistant to systemic or/and topical treatment. Only 2 patients (no. 4 and 6) had not undergone any previous treatment, despite which they preferred laser treatment.

The patients' details are shown in Table 1.

Patients were treated with nonablative 1,550-nm erbium glass fractional laser (Fraxel, Solta Medical, Pleasanton, CA). The parameters applied were as follows: fluences ranging from 30 to 45 mJ, 6 to 10 density, and 8 to 10 passes. Sessions were performed at 2 to 6 weeks intervals for a total of 1 to 9 sessions (median: 3). The treatment was performed with an anesthetic cream or/and an air cooling system. There was no need to shave hair for the treatment. Photographs were taken before and after treatment and were used to evaluate the effects of treatment. The results were evaluated by a dermatologist on a visual global improvement score scale: 0% to 25% improvement, 26% to 50%, 51% to 75%, and greater than 75%.

All patients showed overall remarkable clinical improvement. Hair growth was observed as early as at 2 weeks after 1 to 2 sessions. After 2 to 4 sessions, hair density showed a marked increase, and hair thickness also increased. At the end of the treatment, patches were covered (fully or almost fully) of mostly pigmented terminal hair in its original color (Figures 1 and 2). No recurrence of the same plaques was observed, but new plaques were developed in the patient with AA of 22 years of evolution. One patient relapsed with a new lesion during treatment but exhibited a good response after the treatment.

In the patient with AA universalis, the whole diffuse alopecic area of scalp and eyebrows was treated, but the beard, eyelashes, and areas of the body were not treated serving as control. In this patient, no regrowth