

# UCLA

## UCLA Previously Published Works

### Title

Adolescent athletes can get back in the game after surgery for thoracic outlet syndrome

### Permalink

<https://escholarship.org/uc/item/7mm575nb>

### Journal

Journal of Vascular Surgery, 77(2)

### ISSN

0741-5214

### Authors

Talutis, Stephanie D

Ulloa, Jesus G

Gelabert, Hugh A

### Publication Date

2023-02-01

### DOI

10.1016/j.jvs.2022.10.002

### Copyright Information

This work is made available under the terms of a Creative Commons Attribution License, available at <https://creativecommons.org/licenses/by/4.0/>

Peer reviewed

## Adolescent athletes can get back in the game after surgery for thoracic outlet syndrome

Stephanie D. Talutis, MD, MPH, Jesus G. Ulloa, MD, MBA, and Hugh A. Gelabert, MD, Los Angeles, CA

### ABSTRACT

**Objective:** We compared the functional outcomes among adolescent athletes with venous thoracic outlet syndrome (VTOS) and neurogenic TOS (NTOS) after thoracic outlet decompression.

**Methods:** We performed a single-institution retrospective review of a prospective database of adolescent athletes (aged 13-19 years) from June 1, 1996 to December 31, 2021 who had undergone operative decompression for TOS. The demographic data, preoperative symptoms, operative details, and postoperative outcomes were compared. The primary outcome was the postoperative return to sport. The secondary outcomes included symptom resolution and assessment of the somatic pain scale, QuickDASH, and Derkash scores. The Fisher exact test and *t* test were used to evaluate the categorical and continuous variables, respectively. A logistic regression model was constructed to adjust for the influence of preoperative factors and return to sport.

**Results:** A total of 60 patients (40.0% with VTOS and 60.0% with NTOS) were included. The average age of the VTOS patients was 17.2 years vs 16.6 years for the NTOS patients ( $P = .265$ ). The NTOS patients were more likely to be female (88.9% vs 62.5%;  $P = .024$ ). The NTOS patients had more frequently presented with pain (97.2% vs 70.8%;  $P = .005$ ), paresthesia (94.4% vs 29.1%;  $P = .021$ ), and weakness (67.7% vs 12.5%;  $P = .004$ ) but had less often reported swelling (25.0% vs 95.8%;  $P < .001$ ). At presentation, the NTOS patients had also reported a longer symptom duration (17.7 months vs 3.1 months;  $P < .001$ ). Transaxillary first rib resection with subtotal scalenectomy was performed for 100% of the VTOS patients and 94.4% of the NTOS patients undergoing cervical rib resection (2.8%) or scalenectomy alone (2.8%). Additionally, 11.1% of the NTOS patients had undergone combined first rib resection and cervical rib resection. For the VTOS patients, postoperative venography showed patent subclavian veins in 27.8%. In addition, 44.4% had required venoplasty, 16.8% had required thrombolysis, and 11% were chronically occluded. No significant differences were found in blood loss, operative time, or length of stay between the groups. No surgical complications occurred. The average follow-up was 6.3 months. Significant differences were found between the VTOS and NTOS groups for the pre- and postoperative somatic pain scale, QuickDASH, and Derkash scores. Complete symptom resolution had occurred in 83.3% of the VTOS and 75% of the NTOS patients ( $P = .074$ ). No statistically significant difference in the return to sport was observed between the two groups (VTOS, 94.4%; vs NTOS, 73.9%;  $P = .123$ ). Of the NTOS patients, 10.0% had had other concomitant injuries and 5.0% had had medical conditions that had precluded their return to sport. Logistic regression found no significant relationship between the preoperative somatic pain scale score, QuickDASH score, or duration of symptoms and the return to sport.

**Conclusions:** Adolescent athletes with VTOS and NTOS can have good functional outcomes, and most will be able to return to sport after surgery. Greater initial symptom severity and concomitant injuries were observed in adolescents with NTOS. Of those who had not returned to sport postoperatively, three of seven had had unrelated health issues that had prevented their return to sport. (*J Vasc Surg* 2023;77:599-605.)

**Keywords:** Neurogenic; Outcomes; Paget-Schroetter; Pain; Thoracic outlet

Thoracic outlet syndrome (TOS) results from extrinsic compression of the brachial plexus, subclavian artery, and subclavian vein as they traverse the first rib and enter the arm.<sup>1</sup> The compression of these structures by the anterior scalene muscle, a first rib, or an anomalous fibrous

band will produce neurogenic TOS (NTOS), arterial TOS, or venous TOS (VTOS), respectively.<sup>2-6</sup> TOS results from a combination of congenital anatomic abnormalities and acquired muscle hypertrophy or contracture.<sup>5,7</sup> Patients will present with a constellation of symptoms that will

---

From the Division of Vascular and Endovascular Surgery, David Geffen School of Medicine at UCLA, Ronald Reagan Medical Center, University of California, Los Angeles.

Author conflict of interest: none.

Presented at the VESS Paper Session at the 2022 Vascular Annual Meeting of the Society for Vascular Surgery, Boston, MA, June 14-17, 2022.

Correspondence: Stephanie D. Talutis, MD, MPH, Division of Vascular and Endovascular Surgery, David Geffen School of Medicine at UCLA, Ronald Reagan Medical Center, University of California, Los Angeles, 200 Medical Plaza Driveway, Ste 526, Los Angeles, CA 90024 (e-mail: [stalutis@mednet.ucla.edu](mailto:stalutis@mednet.ucla.edu)).

---

The editors and reviewers of this article have no relevant financial relationships to disclose per the JVS policy that requires reviewers to decline review of any manuscript for which they may have a conflict of interest.

0741-5214

Copyright © 2022 The Authors. Published by Elsevier Inc. on behalf of the Society for Vascular Surgery. This is an open access article under the CC BY license (<http://creativecommons.org/licenses/by/4.0/>).

<https://doi.org/10.1016/j.jvs.2022.10.002>

vary by the severity of the compression and symptom duration. The symptoms will often include pain, paresthesia, fatigue, color change, weakness, heaviness, and motor deficits in the neck, arm, and/or hand.<sup>3,4,8,9</sup>

TOS is infrequent, with a prevalence of 1% to 2% in the general population.<sup>9,10</sup> TOS has also been more frequently diagnosed in women at a ratio of 3:1,<sup>4,7,10,11</sup> with a typical age of diagnosis of 21 to 50 years.<sup>5,8,9</sup> Many patients have reported vigorous and repetitive physical activity; thus, the condition has been well recognized among athletes and industrial workers.<sup>6</sup>

Because of the variety in the clinical presentation and symptom severity, TOS will often be underdiagnosed in children and adolescents and, subsequently, undertreated.<sup>12</sup> Such delays in diagnosis and management can result in prolonged disability and reduced quality of life for patients. Several studies have included adolescents in their study population<sup>2,4,5,7,8,10-12</sup>; however, few studies have compared the NTOS and VTOS patient outcomes with long-term follow-up data. In the present study, we evaluated the clinical presentation and postoperative outcomes of adolescent athletes (aged 13-19 years) with NTOS and VTOS.

## METHODS

A prospective surgical database was reviewed for adolescent athletes who had required surgical care for disabling TOS between 1997 and 2022. Adolescents were defined as those aged 13 to 19 years. Athlete status was determined by patient report of competitive athletic pursuits. The demographic, clinical, and pathologic data were reviewed.

**Diagnosis of TOS.** The Society for Vascular Surgery reporting standards were used for the diagnosis of TOS.<sup>13</sup> A diagnosis of NTOS was determined by the presence of symptoms of radicular pain, paresthesia, and weakness, in addition to physical examination findings consistent with the diagnosis of TOS. Diagnostic testing included a combination of cervical spine radiography, cervical magnetic resonance imaging (MRI), nerve conduction testing, and anterior scalene muscle blocks (ASMBs). The initial treatment of NTOS included TOS-specific physical therapy. After a trial of targeted physical therapy, all the patients with persistent and severe symptoms were offered treatment with Botox (Allergan, Dublin, Ireland) for chemical denervation or surgical decompression. Surgery was reserved for patients with severe, intractable, and disabling symptoms. The patients whose condition had responded to targeted physical therapy were not offered surgery. These nonoperative patients were followed up until their symptoms had resolved or were well controlled. Patients with negative imaging findings and negative results from ASMBs were informed that they did not have TOS.

A diagnosis of VTOS was diagnosed by the presence of symptoms, including limb swelling, pain, and discoloration, in addition to the ultrasound and venography

## ARTICLE HIGHLIGHTS

- **Type of Research:** A single-institution, retrospective analysis of a prospectively collected thoracic outlet syndrome (TOS) registry
- **Key Findings:** Adolescent athletes with venous and neurogenic TOS had had good functional outcomes and a return to sports after surgery. A greater initial symptom severity and concomitant injuries were observed in adolescents with neurogenic TOS.
- **Take Home Message:** Adolescent athletes with both neurogenic and venous TOS had good functional outcomes, with most patients experiencing complete symptom resolution and a return to sports after surgery.

findings. Thrombolysis was routinely used for patients with an acute presentation (within 2 weeks of symptom onset), followed by anticoagulation therapy. Surgery was considered for patients with evidence of extrinsic venous compression and persistent congestive symptoms. Venography was routinely performed for patients with VTOS at the first rib resection (FRR). Venoplasty was not performed concurrent with FRR because of prior experience with intraoperative venoplasty resulting in hemorrhage. Patients with VTOS began anticoagulation therapy again on postoperative day 5. Routine venography after rib resection was performed 2 to 3 weeks after surgery to assess the surgical results and provide angioplasty, as needed. If venoplasty had been performed, anticoagulation therapy was continued for an additional 4 weeks.

TOS decompression was achieved in most patients by transaxillary resection of first and/or cervical rib with sub-total scalenectomy.<sup>14-16</sup> One patient had required scalenectomy for TOS decompression. Primary scalenectomy alone had been performed because of the predominance of upper brachial plexus symptoms and patient preference.

Postdecompression venography and ultrasound were used to follow-up patients with VTOS. The postoperative visits were conducted at 2 and 6 weeks and then every 3 months until the symptoms had resolved. The patients received postoperative physical therapy beginning 2 weeks after surgery. They were given instructions on performing range of motion exercises at discharge and a prescription for physical therapy after their first postoperative appointment. Postoperative physical therapy included massage, stretching, and strengthening. The duration of physical therapy was determined by the individual patient's recovery and was an average of 4 to 6 weeks.

**Analysis of outcomes.** In alignment with the Society for Vascular Surgery reporting standards, the outcomes were assessed using the somatic pain scale (SPS) scores, QuickDASH scores,<sup>17</sup> and Derkash scores<sup>18</sup> and

**Table.** Demographic and clinical presentation data

Variable	Overall (n = 60)	NTOS (n = 36)	VTOS (n = 24)	P value
Age, years	16.9 (13-19)	16.6 (13-19)	17.2 (14-19)	.27
Female sex	47 (78.3)	32 (88.9)	15 (62.5)	<b>.024</b>
Symptom laterality				<b>.038</b>
Right	38 (63.3)	19 (52.8)	19 (79.2)	
Left	15 (25.0)	10 (27.8)	5 (20.8)	
Bilateral	7 (11.7)	7 (19.4)	0 (0.0)	
Symptoms in dominant hand	44 (73.3)	25 (69.4)	19 (79.1)	.54
Symptom duration, months	11.6 (0-72)	17.7 (1-72)	3.1 (0-24)	<b>&lt;.001</b>
Presenting symptoms				
Pain	52 (86.7)	35 (97.2)	17 (70.8)	<b>.005</b>
Paresthesia	41 (68.3)	34 (94.4)	7 (29.1)	<b>.021</b>
Color change	24 (40)	11 (30.6)	13 (54.2)	<b>.038</b>
Coldness	19 (31.7)	15 (41.7)	4 (16.7)	.48
Weakness	27 (45)	24 (66.7)	3 (12.5)	<b>.004</b>
Swelling	32 (53.3)	9 (25.0)	24 (95.8)	<b>&lt;.001</b>
Headache	16 (26.7)	13 (36.1)	3 (12.5)	.29

NTOS, Neurogenic thoracic outlet syndrome; VTOS, venous thoracic outlet syndrome.  
Data presented as average (range) or number (%).  
Boldface P values represent statistical significance.

compared between the NTOS and VTOS patients. The Derkash scores indicate the effect of TOS symptoms on professional and daily activities using a scale from 1 (poor) to 4 (excellent).<sup>18</sup> Each of these scores was compared preoperatively, at consultation, and postoperatively within the NTOS and VTOS groups at the last postoperative appointment. The return to sport was recorded for all patients at all clinic visits. The University of California, Los Angeles, institutional review board approved the present study.

**Statistical analysis.** The Fisher exact test and *t* test were used to evaluate the categorical and continuous variables, respectively. A logistic regression model was constructed to adjust for the influence of preoperative factors and the return to sport. Significance was defined at  $P < .05$ .

## RESULTS

During the study period, 1700 operations for TOS had been performed. Of these, 60 adolescent athletes had undergone surgery to treat TOS during the study period. The demographic and clinical presentation data are presented in the [Table](#). The cohort was predominantly female ( $n = 47$ ; 78.3%). The average age of the athletes was 16.9 years. Of the 60 patients, 36 (60%) had had NTOS and 24 (40%) had had VTOS.

No differences were found in the average age (NTOS, 16.6 years; vs VTOS, 17.2 years;  $P = 0.265$ ). A slightly higher percentage of girls was found in the NTOS group (88.9% vs 62.5%;  $P = .024$ ). The NTOS patients were also more likely to have bilateral symptoms (19.4% vs 0.0%;

$P = .038$ ; [Table](#)). Symptoms had occurred in the dominant hand in 79.1% of the VTOS patients and 69.4% of the NTOS patients ( $P = 0.54$ ). The interval from symptom onset to diagnosis was longer for the NTOS patients than for the VTOS patients (17.7 months vs 3.1 months;  $P < .001$ ). The symptoms reported at consultation also differed between the two groups ([Table](#)).

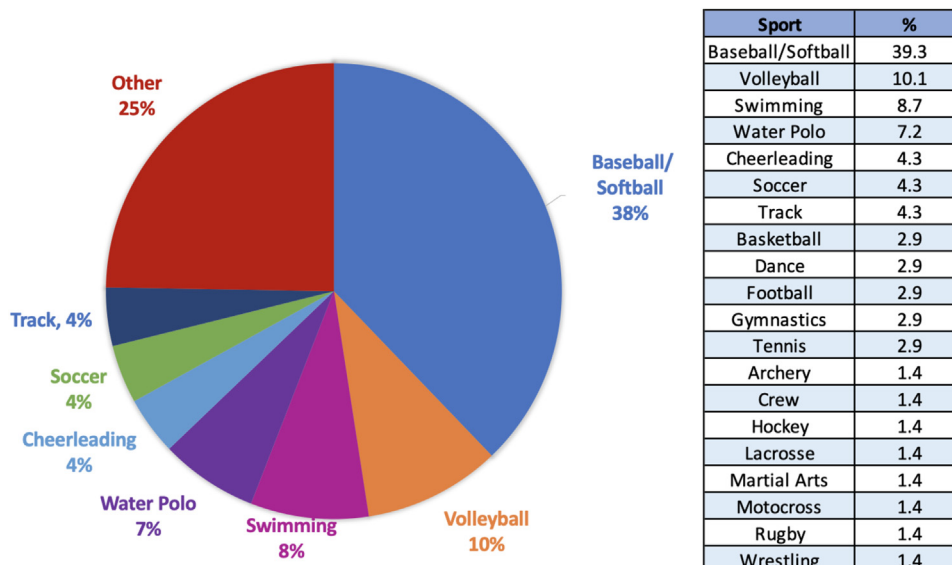
The sports played by the athletes are presented in [Fig 1](#). Most patients played only one sport competitively (85%). Eight patients (13.3%) played two sports, and one (1.7%) played three sports. The most common sports reported were baseball or softball (39.3%), volleyball (10.1%), swimming (8.7%), and water polo (7.2%).

### NTOS group

In addition to the standard NTOS workup, including cervical spine radiography, cervical MRI, and nerve conduction testing, 27 patients (75.0%) had undergone an ASMB. Of those who had undergone ASMB testing, 22 (81.5%) had experienced a positive result (temporary relief of symptoms). ASMB testing was occasionally omitted for the patients for whom the electrophysiology, ultrasound, or MRI findings were diagnostic, in addition to history and physical examination findings strongly supporting the diagnosis of NTOS without confounders. Two patients with NTOS had also had concurrent pectoralis minor syndrome, which was diagnosed by physical examination and confirmed by the results from a pectoralis minor block.

### VTOS group

Among the patients with VTOS, 19 (79.2%) had presented with acute deep vein thrombosis. Five patients



**Fig 1.** Sports reported among adolescent athletes.

had presented to our institution with acute subclavian vein thrombus and had undergone thrombolysis. These patients had undergone thrombolysis, followed by FRR, during the index hospitalization. The other 14 patients had presented acutely to an outside institution, where 10 had undergone thrombolysis and 4 had received anticoagulation therapy alone. Of the patients with VTOS, five (20.8%) had had pathologic subclavian vein compression without thrombosis (McCleery syndrome), as evidenced by severe limb swelling, pain, and discoloration. These patients did not receive anticoagulation therapy before surgery.

#### Operative details

All 60 patients (100%) had undergone thoracic outlet decompression. Of the 60 patients, 59 (98.3%) had undergone transaxillary FRR, and 5 (8.5%) had undergone cervical rib resection concurrent with FRR. Additionally, one patient (1.7%) had undergone concurrent pectoralis minor tenotomy concurrent with FRR. One patient with NTOS had undergone scalenectomy instead of FRR at the index operation because of predominant upper brachial plexus symptoms.

The mean operative time was 107.8 minutes (range, 65–247 minutes). The mean estimated blood loss was 25 mL. The mean length of stay was 2.1 days. No significant differences were found in the operative time, estimated blood loss, or length of stay between the two groups. No brachial plexus or arterial or venous injuries were found among the study population.

#### Outcomes

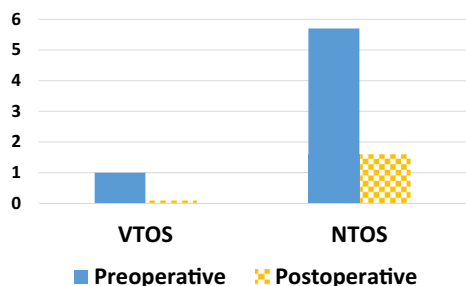
The mean postoperative follow-up duration was 4.1 months for the VTOS group and 7.3 months for the NTOS group ( $P = .231$ ).

**SPS score.** The pre- and postoperative SPS scores are presented in Fig 2. The average preoperative SPS score was 4.6 for all the patients. The average postoperative SPS score was 1.0. The NTOS patients reported significantly higher preoperative (5.7 vs 1.0;  $P < .001$ ) and postoperative (1.6 vs 0.1;  $P = .014$ ) SPS scores compared with those of the VTOS patients. The average improvement in the SPS score was 1.1 points for the NTOS patients and 0.1 point for the VTOS patients ( $P = .019$ ). A paired  $t$  test analysis revealed that the NTOS and VTOS patients had both experienced significant improvements in the SPS score ( $P < .001$  for both).

**QuickDASH scores.** The pre- and postoperative QuickDASH scores are presented in Fig 3. The average preoperative QuickDASH score for all patients was 53.1. The average postoperative QuickDASH score was 17.7. The NTOS patients had reported significantly higher preoperative (59.3 vs 22.8;  $P < .001$ ) and postoperative (23.0 vs 3.84;  $P = .001$ ) QuickDASH scores compared with those of the VTOS patients. The average improvement in the QuickDASH score was 40.5 points for the NTOS patients and 21.5 for the VTOS patients; however, this difference was not statistically significant ( $P = .055$ ). The paired  $t$  test analysis revealed that the NTOS and VTOS patients had experienced significant improvements in the QuickDASH scores ( $P < .001$  for both).

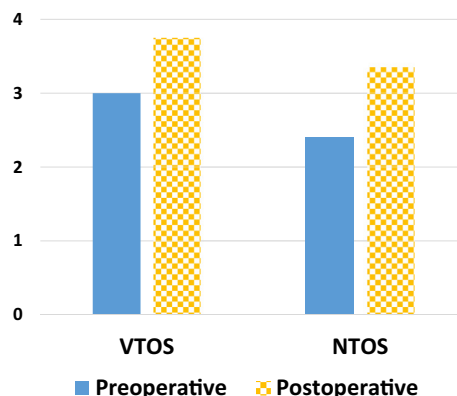
**Derkash scores.** The pre- and postoperative Derkash scores are presented in Fig 4. The average preoperative Derkash score for all patients was 2.7. The average postoperative Derkash score was 3.5. The NTOS patients had reported significantly lower preoperative (2.4 vs 3.0;  $P < .001$ ) and postoperative (3.4 vs 3.7;  $P = .013$ ) Derkash scores compared with those for the VTOS patients. The average improvement in the Derkash score was 0.9 point for each group, which was not a statistically significant





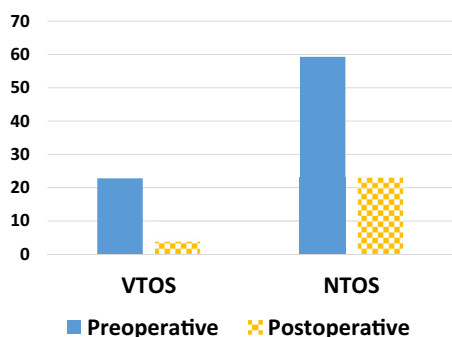
	Preoperative	Postoperative	Delta Pain	P-value
VTOS	1.0	0.1	0.1	<0.001*
NTOS	5.7	1.6	1.1	<0.001*

**Fig 2.** Somatic pain scores. *NTOS*, Neurogenic thoracic outlet syndrome; *VTOS*, venous thoracic outlet syndrome. \*Significance defined as  $P < .001$  (difference between pre- and postoperative somatic pain scale [SPS] scores using paired  $t$  test).



	Preoperative	Postoperative	Delta Derkash	P-value
VTOS	3.0	3.8	0.9	<0.001*
NTOS	2.4	3.4	0.9	<0.001*

**Fig 4.** Derkash scores. *NTOS*, Neurogenic thoracic outlet syndrome; *VTOS*, venous thoracic outlet syndrome. \*Significance defined as  $P < .001$  (difference between pre- and postoperative Derkash scores using paired  $t$  test).



	Preoperative	Postoperative	Delta DASH	P-value
VTOS	22.8	3.8	21.5	<0.001*
NTOS	59.3	23.0	40.5	<0.001*

**Fig 3.** QuickDASH scores. *NTOS*, Neurogenic thoracic outlet syndrome; *VTOS*, venous thoracic outlet syndrome. \*Significance defined as  $P < .001$  (difference between pre- and postoperative QuickDASH scores using paired  $t$  test).

difference ( $P = .747$ ). The paired  $t$  test analysis revealed that the *NTOS* and *VTOS* patients had experienced significant improvements in the Derkash score ( $P < .001$  for both).

**Postoperative venography.** Postoperative venography was performed in 75% of the patients with *VTOS* 2 weeks after *FRR*. The subclavian vein was patent in 20.8%, stenotic in 33.3%, and thrombosed in 12.6%. Subclavian vein stenosis was treated with venoplasty. Subclavian vein thrombosis was managed with thrombolysis and continued anticoagulation therapy. Of the *VTOS* patients, 25% had not undergone venography postoperatively at

our institution because they lived far from our institution. Therefore, they had undergone venography in their local community.

**Additional surgery.** Seven patients (39%) with *NTOS* had undergone contralateral *FRR* after recovery from their initial surgery. The average time to contralateral *FRR* was 9 months. Of the seven patients who had required contralateral *FRR*, four had also required scalenectomy (two bilateral and two unilateral) to treat recurrent symptoms. An additional eight patients with *NTOS* had also required scalenectomy because of robust scar tissue formation after unilateral *FRR*. The average time to scalenectomy after *FRR* was 10 months. None of the patients with *VTOS* had required scalenectomy or contralateral *FRR*.

**Symptom resolution and return to sport.** The mean postoperative follow-up was 6.2 months and was not significantly different between the two groups (*NTOS*, 7.3 months; vs *VTOS*, 4.1 months;  $P = .231$ ). Complete symptom resolution was reported for 78.3% of all athletes, including 83.3% with *VTOS* and 75.0% with *NTOS*. No statistically significant difference in the return to sport was observed between the two groups. Of the 25 *VTOS* patients, 24 had returned to their sport. The one athlete who had not returned to sport had not done so because of an unrelated injury. Of the 36 *NTOS* patients, 30 had returned to sport. Of the six who had not returned to sport, one had had an unrelated injury, one had had a medical condition, and four had been lost to follow-up before their possible return to sport. For both groups, binary logistic regression found no significant relationship between age ( $P = .344$ ), sex ( $P = .999$ ), preoperative

pain score ( $P = .316$ ), preoperative QuickDASH score ( $P = .291$ ), or symptom duration ( $P = .451$ ) and a return to sport.

## DISCUSSION

TOS is a clinical disorder that often presents with upper extremity symptoms due to compression of the brachial plexus by the anterior scalene muscle, the first rib, or an anomalous fibrous band.<sup>2,3</sup> The anatomic compression results from repetitive activity or trauma and has been well described among athletes and industrial workers.<sup>2,6</sup> NTOS, in particular, has been more frequent among physically active individuals. It is believed that repetitive, rigorous upper extremity exercises can accelerate disease progression in patients with an anatomic predisposition, such as those with a cervical rib, fascial band, or scalenus minimus muscle.<sup>6</sup> Repeated trauma can also irritate the brachial plexus, resulting in inflammation and compression in the absence of structural abnormalities.<sup>6</sup>

To the best of our knowledge, the present study is the largest study with follow-up of adolescents and the only study to report on adolescent athletes with TOS after surgical decompression. We found that adolescent athletes with NTOS and VTOS experienced significant improvement in postoperative pain, QuickDASH, and Derkash scores. The improvement in the QuickDASH score did not reach statistical significance, which was likely limited by the sample size and statistical power. Nearly 80% of the patients had reported complete symptom resolution after thoracic outlet decompression. Furthermore, 90% of the adolescent athletes had returned to their sport by the end of their follow-up period.

**Athletes and TOS.** Several studies have described the association of NTOS and VTOS with competitive athletes.<sup>3,19-22</sup> Many of the athletes in these series had participated in sports involving vigorous or repetitive upper extremity motion. Baseball and softball, swimming, volleyball, and water polo were represented highly among these cohorts,<sup>3,21,22</sup> a finding also consistent with our patient population. Chandra et al<sup>3</sup> noted that the high physical performance demands and the short span of time in which they can compete could both benefit and hinder athletes. Furthermore, athletes likely have better coping skills and strategies for managing stress, pain, and disability, resulting in highly motivated patients.<sup>19</sup> To increase the likelihood of a successful and injury-free return to sport, athletes with TOS should be cared for by a team composed of surgeons, physical therapists, athletic trainers, and team physicians.<sup>3</sup>

Our cohort included only surgical patients. We found that the NTOS patients often had a longer time from symptom onset to consultation. The NTOS patients had, on average, also had higher SPS scores, QuickDASH

scores, and disability, as rated using the Derkash score. Chandra et al<sup>3</sup> describe a subset of NTOS patients with a short symptom duration and lower QuickDASH score who had received physical therapy alone. This is an important point, because early diagnosis and treatment could prevent the ongoing brachial plexopathy resulting from repetitive motion and vigorous activity.<sup>3,21</sup>

**Adolescents and TOS.** For adolescents with TOS, the relationship with repetitive motion activities and athletics has persisted.<sup>2,4,5,7,8,10-12</sup> However, the diagnosis and surgical referral will often be delayed by a lack of understanding of TOS among pediatricians.<sup>9</sup> A delay in the diagnosis will result in missed school and extracurricular activities.<sup>2</sup> A delay in operative management for patients with debilitating symptoms could result in additional disability and a decreased likelihood that operative repair will be successful owing to prolonged nerve compression.

The diagnosis should be undertaken for adolescents similar to that used for adults, including cervical spine imaging, electromyography, nerve conduction studies, and neuromuscular blockade. However, Al Shakarchi et al<sup>9</sup> found that the adolescents had frequently not undergone electromyography or nerve conduction studies to evaluate their symptoms. This discrepancy in the use of diagnostic modalities is thought to be related to the low familiarity of the referring pediatric physicians. Once diagnosed, however, the surgical approach and management should be similar to that for adults, including FRR and postoperative physical therapy.<sup>2,9,11,12</sup> Similar to our study, many of the children and adolescents in these pediatric TOS studies had returned to school and extracurricular activities, indicating that thoracic outlet decompression will be beneficial through a spectrum of ages.<sup>7,9,11,12</sup>

VTOS has been reported at a greater frequency than NTOS among children and adolescents.<sup>5,8</sup> We did not observe this in our cohort, however, which might have been because we had targeted our analysis to adolescent athletes, leading to a slight NTOS predominance. Regardless of the diagnosis of NTOS or VTOS, many of the studies of adolescents and children had noted a high prevalence of anatomic abnormalities, including cervical ribs or an abnormal tendon insertion.<sup>2,7,12</sup> In a study by Rehemutula et al,<sup>4</sup> many of the children who had undergone thoracic outlet decompression had also been found to have enlarged lymph nodes within the surgical field, with pathologic evidence of chronic inflammation. This finding supports the idea of repeated insults to the structures of the thoracic outlet over time.

**Study limitations.** Our report was limited by its retrospective nature. Although the present study included, to the best of our knowledge, the largest cohort of adolescents and the only cohort of solely adolescent

athletes, our cohort size was smaller than those of adults with TOS. The present study included only adolescent athletes who had undergone TOS decompression and did not include patients who had received conservative treatment. Although these data have suggested that most patients can be managed conservatively, we had only evaluated patients whose symptoms were severe and debilitating enough to necessitate surgery.

Because of the small sample size, a type II error could have been present and might account for the lack of statistically significant differences in some analyses. We were also limited by the short-term follow-up for patients who had been referred from remote areas, because these patients completed their long-term follow-up with their local vascular surgeons.

## CONCLUSIONS

Adolescent athletes are at risk of TOS because of the repetitive motion activities associated with their sport. Adolescent athletes with both VTOS and NTOS can have good functional outcomes, with most patients experiencing complete symptom resolution and a return to sport after surgery.

## AUTHOR CONTRIBUTIONS

Conception and design: ST, HG

Analysis and interpretation: ST, JU, HG

Data collection: ST, HG

Writing the article: ST

Critical revision of the article: ST, JU, HG

Final approval of the article: ST, JU, HG

Statistical analysis: ST, HG

Obtained funding: Not applicable

Overall responsibility: ST

## REFERENCES

1. Peet RM, Henriksen JD, Anderson TP, Martin GM. Thoracic-outlet syndrome: evaluation of a therapeutic exercise program. *Proc Staff Meet Mayo Clin* 1956;31:281-7.
2. Chang K, Graf E, Davis K, Demos J, Roethle T, Freischlag JA. Spectrum of thoracic outlet syndrome presentation in adolescents. *Arch Surg* 2011;146:1383-7.
3. Chandra V, Little C, Lee JT. Thoracic outlet syndrome in high-performance athletes. *J Vasc Surg* 2014;60:1012-7; discussion: 1017-8.
4. Rehemutula A, Zhang L, Chen L, Chen D, Gu Y. Managing pediatric thoracic outlet syndrome. *Ital J Pediatr* 2015;41:22.
5. Vercellio G, Baraldini V, Gatti C, Coletti M, Cipolat L. Thoracic outlet syndrome in paediatrics: clinical presentation, surgical treatment, and outcome in a series of eight children. *J Pediatr Surg* 2003;38:58-61.
6. White JM, Soo Hoo AJ, Golarz SR. Supraclavicular thoracic outlet decompression in the high-performance military population. *Mil Med* 2018;183:e90-4.
7. Hong J, Pisapia JM, Ali ZS, Heuer AJ, Alexander E, Heuer GG, et al. Long-term outcomes after surgical treatment of pediatric neurogenic thoracic outlet syndrome. *J Neurosurg Pediatr* 2018;21:54-64.
8. Vu AT, Patel PA, Elhadi H, Schwentker AR, Yakuboff KP. Thoracic outlet syndrome in the pediatric population: case series. *J Hand Surg Am* 2014;39:484-7.e2.
9. Al Shakarchi J, Jaipersad A, Morgan R, Pherwani A. Early and late outcomes of surgery for neurogenic thoracic outlet syndrome in adolescents. *Ann Vasc Surg* 2020;63:332-5.
10. Maru S, Dosluoglu H, Dryjski M, Cherr C, Curl GR, Harris LM. Thoracic outlet syndrome in children and young adults. *Eur J Vasc Endovasc Surg* 2009;38:560-4.
11. Ransom EF, Minton HL, Young BL, He JK, Ponce BA, McGwin C, et al. Intermediate and long-term outcomes following surgical decompression of neurogenic thoracic outlet syndrome in an adolescent patient population. *Hand (N Y)* 2022;17:43-9.
12. Rigberg DA, Gelabert H. The management of thoracic outlet syndrome in teenaged patients. *Ann Vasc Surg* 2009;23:335-40.
13. Illig KA, Donahue D, Duncan A, Freischlag J, Gelabert H, Johansen K, et al. Reporting standards of the Society for Vascular Surgery for thoracic outlet syndrome. *J Vasc Surg* 2016;64:e23-35.
14. Chan YC, Gelabert HA. High-definition video-assisted transaxillary first rib resection for thoracic outlet syndrome. *J Vasc Surg* 2013;57:1155-8.
15. Moridzadeh RS, Gelabert MC, Rigberg DA, Gelabert HA. A novel technique for transaxillary resection of fully formed cervical ribs with long-term clinical outcomes. *J Vasc Surg* 2021;73:572-80.
16. Roos DB. Transaxillary approach for first rib resection to relieve thoracic outlet syndrome. *Ann Surg* 1966;163:354-8.
17. Wong JY, Fung BK, Chu MM, Chan RK. The use of disabilities of the arm, shoulder, and hand questionnaire in rehabilitation after acute traumatic hand injuries. *J Hand Ther* 2007;20:49-55. quiz: 56.
18. Derkash RS, Goldberg VM, Mendelson H, Mevicker R. The results of first rib resection in thoracic outlet syndrome. *Orthopedics* 1981;4:1025-9.
19. Beteck B, Shutze W, Richardson B, Shutze R, Tran K, Dao A, et al. Comparison of athletes and nonathletes undergoing thoracic outlet decompression for neurogenic thoracic outlet syndrome. *Ann Vasc Surg* 2019;54:269-75.
20. Melby SJ, Vedantham S, Narra VR, Paletta GA, Khoo-Summers L, Driskill M, et al. Comprehensive surgical management of the competitive athlete with effort thrombosis of the subclavian vein (Paget-Schroetter syndrome). *J Vasc Surg* 2008;47:809-20; discussion: 821.
21. Shutze W, Richardson B, Shutze R, Tran K, Dao A, Ogola GO, et al. Midterm and long-term follow-up in competitive athletes undergoing thoracic outlet decompression for neurogenic thoracic outlet syndrome. *J Vasc Surg* 2017;66:1798-805.
22. Thompson RW, Dawkins C, Vemuri C, Mulholland MW, Hadzinsky TD, Pearl GJ. Performance metrics in professional baseball pitchers before and after surgical treatment for neurogenic thoracic outlet syndrome. *Ann Vasc Surg* 2017;39:216-27.

Submitted Jun 28, 2022; accepted Oct 3, 2022.