

# UC San Diego

## UC San Diego Previously Published Works

### Title

[IC-P-146]: TASK-FREE MAGNETIC RESONANCE BRAIN IMAGING DISTINGUISHES ALZHEIMER'S DISEASE FROM HIV-DISEASE VIA SUPPORT VECTOR MACHINE CLASSIFICATION

### Permalink

<https://escholarship.org/uc/item/7j33k8c0>

### Journal

Alzheimer's & Dementia, 13(7S\_Part\_2)

### ISSN

1552-5260

### Authors

Shattuck, Kyle  
Magnus, Manya  
Hassanzadeh, Shiva  
et al.

### Publication Date

2017-07-01

### DOI

10.1016/j.jalz.2017.06.2420

Peer reviewed

# UC San Diego

## UC San Diego Previously Published Works

### Title

[P1-373]: TASK-FREE MAGNETIC RESONANCE BRAIN IMAGING DISTINGUISHES ALZHEIMER'S DISEASE FROM HIV-DISEASE VIA SUPPORT VECTOR MACHINE CLASSIFICATION

### Permalink

<https://escholarship.org/uc/item/8wv490bw>

### Journal

Alzheimer's & Dementia, 13(7S\_Part\_8)

### ISSN

1552-5260

### Authors

Shattuck, Kyle  
Magnus, Manya  
Hassanzadeh, Shiva  
et al.

### Publication Date

2017-07-01

### DOI

10.1016/j.jalz.2017.06.389

Peer reviewed

neuropathologies, by combining ex-vivo brain MRI and neuropathology in a large community cohort of older adults. **Methods:** Cerebral hemispheres were obtained from 275 participants of the Rush Memory and Aging Project and Religious Orders Study, two longitudinal cohort studies of aging (Fig.1). All hemispheres were imaged ex vivo on a 3T MRI scanner. An experienced observer manually outlined WMH on ex-vivo MRI. The white matter of each hemisphere was segmented into periventricular and deep white matter, and each segment was further divided into frontal, temporal, and parieto-occipital regions, using an automated approach. The total volume of WMH in each of the six white matter segments was measured for each hemisphere. Regional WMH burden was then defined as the square root of the regional WMH volume normalized by the height of the participant. Neuropathologic assessment was performed by a board-certified neuropathologist (Fig.2). Multiple linear regression was used to investigate the link between regional WMH burden and age-related neuropathologies: amyloid plaques, PHF-tau tangles, Lewy bodies, TDP43, hippocampal sclerosis, gross and microscopic infarcts, atherosclerosis, arteriolosclerosis, and cerebral amyloid angiopathy (CAA), controlling for age at death, sex, education, and postmortem interval to fixation. **Results:** Arteriolosclerosis was associated with WMH burden in most white matter segments: in parieto-occipital periventricular and in all deep white matter segments ( $p < 0.05$ ). Gross infarcts and atherosclerosis were associated with WMH burden in frontal periventricular and deep white matter ( $p < 0.05$ ). CAA was associated with WMH burden in parieto-occipital deep white matter ( $p < 0.05$ ). Tangles were associated with WMH burden in frontal periventricular and temporal deep white matter ( $p < 0.05$ ). **Conclusions:** The present study in a large community cohort provides robust evidence on regional variations in the relationship between WMH burden and age-related neuropathologies.

Characteristics	
Participants, N	275
Age at death, y (SD)	89.6 (6.4)
Male, n (%)	85 (31)
Education, y (SD)	15.9 (3.6)
Median time between last clinical evaluation and death, y	0.81
Antemortem clinical diagnosis, n (%)	
No clinical impairment	85 (31)
Mild cognitive impairment	62 (23)
Alzheimer's disease	122 (44)
Other primary causes of dementia	6(2)
Global cognition score, mean (SD)	-1.0 (1.3)
Episodic memory score, mean (SD)	-1.0 (1.5)
Semantic memory score, mean (SD)	-1.3 (1.7)
Working memory score, mean (SD)	-0.8 (1.2)
Perceptual speed score, mean (SD)	-1.2 (1.2)
Visuospatial ability score, mean (SD)	-0.5 (1.2)
Mini-Mental State Examination (MMSE), mean (SD)	20.0 (9.7)
Mini-Mental State Examination (MMSE), median	24
Right hemisphere, n (%)	123 (45)
Postmortem interval to fixation, h (SD)	8 (5)
Postmortem interval to imaging, d (SD)	43.6 (18.0)

Key: SD, standard deviation.

Neuropathology	
N	275
NIA Reagan (likelihood of AD), n (%)	
High	64 (23)
Intermediate	132 (48)
Non or low	79 (29)
Lewy bodies, n (%)	65 (24)
Hippocampal sclerosis, n (%)	37 (13)
Gross infarcts, n (%)	119 (43)
Microscopic infarcts, n (%)	99 (36)
Atherosclerosis, n (%)	
Severe	20 (7)
Moderate	71 (26)
Mild	133 (48)
None	51 (19)
Arteriolosclerosis, n (%)	
Severe	23 (8)
Moderate	48 (18)
Mild	136 (49)
None	68 (25)
Cerebral amyloid angiopathy, n (%)	
Severe	27 (10)
Moderate	60 (22)
Mild	136 (49)
None	52 (19)
TDP-43, n (%)	
Inclusions in amygdala, entorhinal cortex or hippocampus CA1, and neocortex	42 (15)
Inclusions in amygdala and entorhinal cortex or hippocampus CA1	55 (20)
Inclusions in amygdala	51 (19)
No inclusions	127 (46)

Key: NIA, National Institute on Aging; AD, Alzheimer's disease; TDP-43, TAR DNA-binding protein 43.

**PI-373**

**TASK-FREE MAGNETIC RESONANCE BRAIN IMAGING DISTINGUISHES ALZHEIMER'S DISEASE FROM HIV-DISEASE VIA SUPPORT VECTOR MACHINE CLASSIFICATION**



**Kyle Shattuck**<sup>1</sup>, Manyia Magnus<sup>2</sup>, Shiva Hassanzadeh<sup>1</sup>, Princy Kumar<sup>1</sup>, Mary Young<sup>1</sup>, G. William Rebeck<sup>1</sup>, John W. VanMeter<sup>1</sup>, David J. Moore<sup>3</sup>, Ronald J. Ellis<sup>3</sup>, Raymond Scott Turner<sup>1</sup>, Xiong Jiang<sup>1</sup>, <sup>1</sup>Georgetown University Medical Center, Washington, DC, USA; <sup>2</sup>George Washington University, Washington, DC, USA; <sup>3</sup>University of California San Diego, La Jolla, CA, USA. Contact e-mail: [ks355@georgetown.edu](mailto:ks355@georgetown.edu)

**Background:** With a rapidly aging HIV+ population, clinicians are increasingly facing the challenge of differentiating HIV-associated neurocognitive disorder (HAND) from other dementias of aging, especially Alzheimer's disease (AD). Current biomarkers of AD and its precursor mild cognitive impairment (MCI) are invasive and/or expensive, limiting their applicability in HIV clinical practice. This study provides evidence that observations from less than ten minutes of task-free structural and functional brain magnetic resonance imaging (MRI) may aid differentiation between AD/MCI and HIV-brain disease. **Methods:** One functional MRI

scan and one structural MRI scan were collected from cohorts of HIV patients ( $n = 23$ ) and AD/MCI patients ( $n = 24$ ), each with demographically matched control subjects ( $n = 14$  and  $48$ , respectively). Functional features ( $n = 1614$ ) were derived from intra- and inter-regional correlations, and structural features ( $n = 418$ ) were derived from volume and concentration measurements for grey and white matter. All features were based on regions-of-interest provided by two publicly available brain atlases defining canonical anatomical space (120 regions) or functional networks (28 regions). A total of 2914 nonlinear support vector machine classification models were created — each withholding one possible combination of patient and control subject used for accuracy testing. For each model, linear effects of age, gender, race, education and acquisition parameters were estimated for non-testing control subjects and removed from training and testing data. Further, all features that subsequently distinguished between the non-testing control subject groups were removed from the analysis (identified by 2-way t-tests thresholded at 0.5 SD); final models contained an average of 232 features. Classification of each subject was based on majority voting of all models from which the subject was withheld. **Results:** Classification was accurate for patients (88%,  $p = 2.8 \times 10^{-9}$ ) but not control subjects (53%,  $p = .70$ ). Specificity was 93% for HIV patients and 82% for AD/MCI patients. **Conclusions:** These results show that machine learning classification based upon short periods of task-free brain MRI acquisition is robustly sensitive to differences in disease-related information, even upon removal of the majority of available feature space. Future studies with demographically matched cohorts are warranted.

P1-374

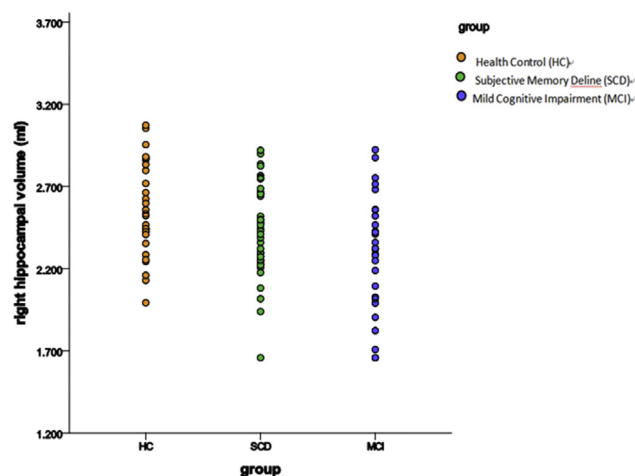
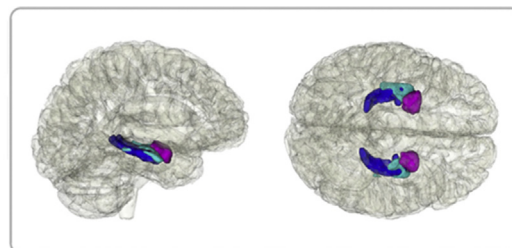
#### ALTERATION OF HIPPOCAMPUS AND AMYGDALA IN SUBJECTIVE COGNITIVE DECLINE AND MILD COGNITIVE IMPAIRMENT IN COMMUNITY-DWELLING CHINESE



Ling Yue<sup>1,2</sup>, Tao Wang<sup>1,2</sup>, Guanjun Li<sup>1,2</sup>, Xia Li<sup>1,2</sup>, Jinghua Wang<sup>1,2</sup>, Minjie Zhu<sup>1,2</sup>, Wei Li<sup>1,2</sup>, Shifu Xiao<sup>1,2</sup>, <sup>1</sup>Department of Geriatric Psychiatry, Shanghai Mental Health Center, Shanghai Jiao Tong University School of Medicine, Shanghai, China; <sup>2</sup>Alzheimer's Disease and Related Disorders Center, Shanghai Jiao Tong University, Shanghai, China. Contact e-mail: [bellinthemoon@hotmail.com](mailto:bellinthemoon@hotmail.com)

**Background:** Subjective cognitive decline (SCD) may be the first clinical sign of Alzheimer's disease (AD). SCD individuals with normal cognition may already have significant hippocampal atrophy. However, few studies have been devoted to exploring the alteration of left-right asymmetry with hippocampus and amygdala. The aim of this study was to compare SCD individuals with mild cognitive impairment (MCI) patients and the normal population for volume and asymmetry of hippocampus and amygdala, and to assess their relationship with cognitive function in elderly population living in the community of China. **Methods:** 40 SCD, 30 MCI, and 30 matched controls underwent a standard T1-weighted MRI and were compared with volume of hippocampus and amygdala. Moreover, we also evaluated the pattern and extent of asymmetry in hippocampus and amygdala of these samples. Cognitive function was assessed with Mini-Mental State Examination (MMSE) and the Montreal Cognitive Assessment (MoCA). Then we investigated the relationship between the altered brain region and cognitive function. **Results:** By using a combination of clinical investigations and laboratory testing, we found there were 30 people with normal cognition without SCD, 40 people with SCD and 30 people with

MCI. There were no significant differences in sex and age between the three groups. By using ANOVA tests, we found statistically significant differences in right hippocampal volumes, mean hippocampal volumes, asymmetry of hippocampus, mean amygdala volumes and asymmetry of amygdala among three groups ( $P < 0.05$ ). SCD individuals showed significant decreased related volumes than controls, but increased than MCI group. For asymmetry pattern, a consistent left-less-than-right asymmetry pattern was found both in hippocampus and amygdala, but with different extents ( $HC > SCD > MCI$ ,  $P < 0.01$ ). Furthermore, neuropsychological test results (MMSE and MoCA) were significant difference between the three groups ( $HC > SCD > MCI$ ,  $P = 0.000$ ). Correlation analysis showed a positive correlation between right hippocampal volume and Moca score in SCD group. **Conclusions:** Right hippocampus were different between MCI patients, SCD individuals and normal controls. SCD individuals with reduced right hippocampus may related to cognitive impairment and increase the likelihood of dementia. Moreover, different extents of asymmetry in hippocampus and amygdala may be a potential dividing factor to differentiate clinical diagnosis.



P1-375

#### DATA-DRIVEN DIAGNOSIS OF DEMENTIA DISORDERS: THE PREDICTND VALIDATION STUDY



Marie Bruun<sup>1</sup>, Le Gjerum<sup>2</sup>, Kristian Steen Frederiksen<sup>2,3</sup>, Hanneke FM. Rhodius-Meester<sup>4</sup>, Marta Baroni<sup>5</sup>, Evelien Lemstra<sup>6</sup>, Jonne A. E. Bremer<sup>6</sup>, Anne Remes<sup>7</sup>, Timo Urhema<sup>8</sup>, Antti Tolonen<sup>9</sup>, Tong Tong<sup>10</sup>, Ricardo Guerrero<sup>10</sup>, Daniel Rueckert<sup>10</sup>, Gunhild Waldemar<sup>3</sup>, Hilikka Soininen<sup>7</sup>, Wiesje M. van der Flier<sup>6</sup>, Patrizia Mecocci<sup>11</sup>, Jyrki Lotjonen<sup>9,12</sup>, Steen Gregers Hasselbalch<sup>1</sup>, <sup>1</sup>Danish Dementia