

UC Davis

Dermatology Online Journal

Title

Opioid associated intravenous and cutaneous microvascular drug abuse (skin-popping) masquerading as Degos disease (malignant atrophic papulosis) with multiorgan involvement

Permalink

<https://escholarship.org/uc/item/7dk8q7n1>

Journal

Dermatology Online Journal, 21(9)

Authors

Magro, Cynthia M
Toledo-Garcia, Aixa
Pala, Ozlem
[et al.](#)

Publication Date

2015

DOI

10.5070/D3219028675

Copyright Information

Copyright 2015 by the author(s). This work is made available under the terms of a Creative Commons Attribution-NonCommercial-NoDerivatives License, available at <https://creativecommons.org/licenses/by-nc-nd/4.0/>

Peer reviewed

Case report

Opioid associated intravenous and cutaneous microvascular drug abuse (skin-popping) masquerading as Degos disease (malignant atrophic papulosis) with multiorgan involvement

Cynthia M Magro¹, Aixa Toledo-Garcia^{2,3}, Ozlem Pala⁴, Shabnam Momtahan¹, Lee Shapiro^{2,3}

Dermatology Online Journal 21 (9): 2

¹Weill Cornell College of Cornell University, New York, NY

²Steffens Scleroderma Center, Saratoga Springs, NY

³The Center for Rheumatology, Albany Medical College

⁴Department of Medicine, Division of Rheumatology, University of Miami Miller School of Medicine, Miami, FL

Correspondence:

Cynthia Magro, M.D.
Professor of Pathology & Laboratory Medicine
Division of Dermatopathology
Director of Dermatopathology
Weill Cornell Medical College of Cornell University
1300 York Ave, Room F309
New York, NY 10065
Tel: 212-746-6434
Fax: 212-746-8570
Email: cym2003@med.cornell.edu

Abstract

Background: In 2012, a nephrologist reported the development of a multiorgan thrombotic syndromic complex resembling thrombotic thrombocytopenic purpura (TTP) in patients who were abusing long acting oxymorphone hydrochloride; all patients had hemolytic anemia and thrombocytopenia.

Objective: Herein, we report another case involving a 31-year-old woman who self intravenously administered dissolved oral oxymorphone resulting in thrombotic sequelae resembling Degos disease.

Methods: Formalin-fixed and paraffin embedded skin biopsies were prepared according to standard protocols for H&E and immunohistochemistry.

Results: The clinical presentation and biopsy findings were held to be indicative of Degos disease/malignant atrophic papulosis (MAP) but with unusual clinical features including renal failure and severe respiratory insufficiency. Given the efficacy of eculizumab in the treatment of the acute thrombotic phase of Degos disease/MAP, the patient received this drug, resulting in rapid resolution of signs and symptoms associated with her multiorgan failure. Although she developed recurrent cutaneous ulcers despite complete complement inhibition with eculizumab., her other extracutaneous manifestations did not recur. The patient's pre and post eculizuamb skin biopsies showed a striking pauci-inflammatory thrombogenic vasculopathy associated with marked

endothelial cell injury along with deposits of C3d and C4d within the cutaneous vasculature; the C5b-9 deposits were limited to the pre-eculizumab biopsy. We discovered that her syndromic complex was a self-inflicted one related to the localized administration of dissolved oxymorphone.

Conclusion: Our patient's biopsy along with the rapid response to eculizumab indicates that this distinct thrombotic microangiopathy is another complement mediated thrombotic microangiopathy syndrome. Opioid thrombotic microangiopathy has a varied clinical presentation and can mimic other catastrophic microangiopathy syndromes, all of which have in common a responsiveness to complement inhibition.

Keywords: Opioid drug abuse, Degos Disease, Malignant atrophic papulosis

Introduction

Acute microvascular thrombosis has a variety of etiologies and, when involving multiple organs is associated with significant morbidity and high mortality. The more common medical conditions associated with catastrophic microvascular thrombosis comprise those related to infection, specifically disseminated intravascular coagulation and purpura fulminans, autoimmune based thrombosis best typified by catastrophic antiphospholipid antibody syndrome, and thrombotic conditions induced by certain genetic abnormalities in hemostasis-most notably atypical hemolytic uremic syndrome (atypical HUS) and thrombotic thrombocytopenic purpura (TTP) [1-6].

On August 13th 2012, a nephrologist reported to the Tennessee State Department of Health the development of a multiorgan thrombotic syndromic complex resembling TTP in 3 patients who were abusing long acting oxymorphone hydrochloride. This particular report led to a statewide investigation in Tennessee uncovering fifteen other cases. More cases have since been described. The cases to date have not been fatal despite significant hemolytic anemia and thrombocytopenia. All of these patients with this unusual TTP-like complex had injected dissolved tablets of Opana ER (Endo Pharmaceuticals), an extended-release form of oral oxymorphone. The mechanism of vascular thrombosis related to the utilization of long acting opioids is unclear [7-10].

Herein, we report a very unusual case in which the overall clinical presentation resembled another catastrophic microangiopathy syndrome, specifically Degos disease/malignant atrophic papulosis (MAP). The patient initially withheld information concerning intravenous drug abuse. Given the efficacy of eculizumab in the treatment of Degos disease/MAP, the patient received this drug, resulting in rapid resolution of signs and symptoms associated with her multiorgan failure. We describe in detail the distinctive clinical features and address the pathogenic basis of opioid associated thrombotic microangiopathy. We review the literature addressing other cases of opioid associated thrombotic vasculopathy and present an espousal regarding its pathogenetic basis.

Case synopsis

In December of 2013, a 31-year-old woman presented for a second opinion regarding a recent diagnosis of Degos Disease/MAP. Prior to this consult, she had been seen at other tertiary care academic medical centers. Her immunological work up was negative. She had been treated with hydroxychloroquine and steroids for 6 months with no substantial benefit. Her illness first became apparent in 2010 when she was noticed to develop crops of skin lesions along with severe myalgias and arthralgias. There was a short lived but predictable positive response to corticosteroids. Following the development of abdominal pain, a diagnosis of Degos disease/malignant atrophic papulosis was made in the setting of probable lupus erythematosus. Treatment in October of

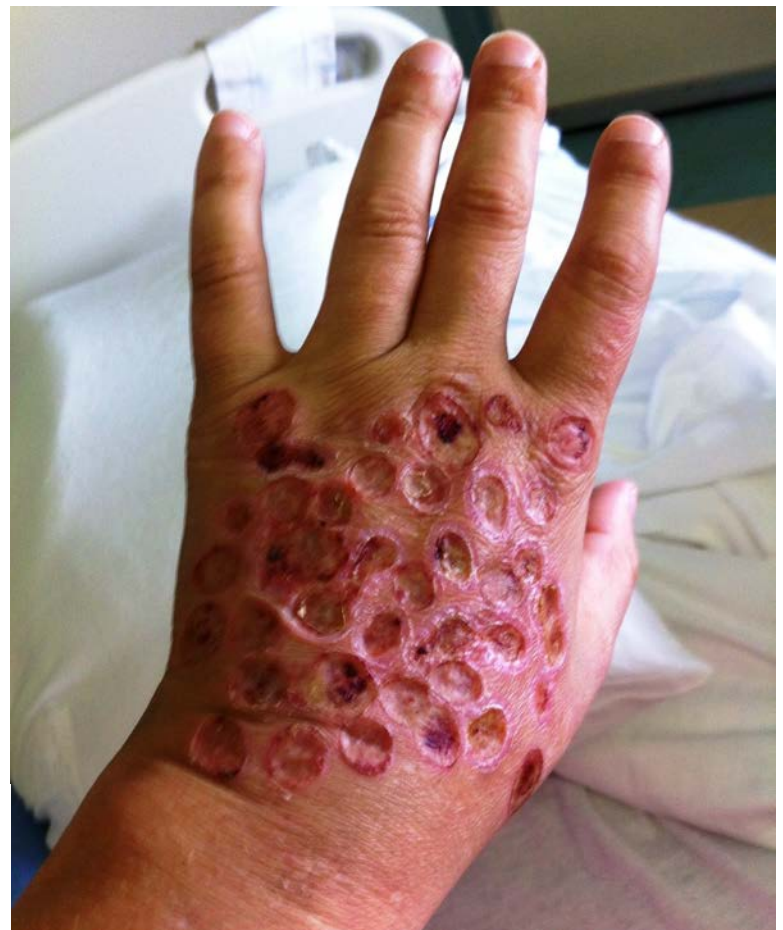

Figure 1. The patient developed striking overlapping concentric rings of cutaneous necrosis exhibiting a sharp pattern of localization to the dorsum of the hand. The lesions proved to be refractory to eculizumab therapy.

2013 ensued with rituximab. The patient was referred for treatment of Degos disease. At that time she was on paroxetine, intramuscular methylprednisolone, transdermal lidocaine, morphine sulfate, pantoprazole, hydroxychloroquine, and dapsone.

We suggested admission to the hospital for expedited ecuzumab (monoclonal C5 inhibitor) treatment on a compassionate basis. Ecuzumab was started in the hospital with rapid improvement in her skin lesions. She also reported that her abdominal pain subsided enabling us to rapidly taper the steroids. As the steroid dose was tapered the patient reported severe myalgias and requested more narcotics for pain.

Eventually she was discharged on sevelamer, hydrocortisone, lidocaine patch, Vitamin D, short acting morphine sulfate, and pantoprazole for GI prophylaxis. Within 12 hours of discharge, the patient was readmitted in shock; she had acute renal failure, oxygen desaturation, and obtundation. Temporary hemodialysis was required. She improved while in the hospital setting initially on stress dose corticosteroids and ecuzumab was continued.

She was once again discharged and was rapidly readmitted with the same complications. Despite continued ecuzumab, she had multiple episodes of respiratory distress and hypotension. High-resolution computerized tomography of the chest revealed a predominantly centrilobular reticular nodular pattern. A lung biopsy was performed and revealed intra-arterial occlusion by talc with an attendant foreign body reaction. She subsequently admitted to utilizing her peripherally inserted central catheter line (PICC) line to inject crushed opioid preparations, which commenced prior to her initial arrival. The PICC line was subsequently removed. Her oral pain medications were tapered. She then started to have worsening of her skin lesions on the dorsum of the hands despite continued ecuzumab therapy.

Physical examination demonstrated a concentric geometric pattern of cutaneous necrosis. The biopsy of skin lesions was performed again. A dermatopathologist reviewed all her data including skin photos and histopathology samples and was provided with a full account of the patient's medical history.

Material and Methods

Formalin-fixed and paraffin embedded skin biopsies were prepared according to standard protocols for H&E and immunohistochemistry. The immunohistochemical stain protocols are described in table 1 (Table 1).

Table 1. Description of various immunohistochemical stains

IHC Stain	Company	Concentration	Clone	Host	Reactivity	Control	Protocol	Retrieval	Dilution	Storage
C3d	Cell Marque	2.96 ug/ml	Polyclonal	Rabbit	Human	Skin	15 8 8 RM	H220	1:100	4°C
C4d	Quidel	1.2 mg/mL	N/A	Murine	Human	Placenta, Tonsil	15 8 8 RM	H220	1:50	4°C
MxA	Santa Cruz	200 ug/ml	C-1	Mouse	Human, Mouse	Skin	15 8 8 RM	H130	1:2000	N/A
C5b-9	Dako	95 mg/L	a#11	Mouse	Human	Placenta	15 8 8 RM	E110	1:250	4°C
Caspase-3	Cell Signaling	N/A	Polyclonal	Rabbit	Human, Mouse, Rat, Monkey, Bovine, Dog, Pig	Tonsil	25 15 25 RM	H130	1:50	-20°C

N/A, not available

Pathology Reports

The patient had two sets of skin biopsies owing to progressive, albeit localized, disease involving the dorsum of the hands. In addition, she had endoscopic biopsies prompted by significant abdominal pain. The earlier skin biopsy that presaged the administration of ecuzumab showed a superficial ulcer with superficial pauci-inflammatory thrombosis.

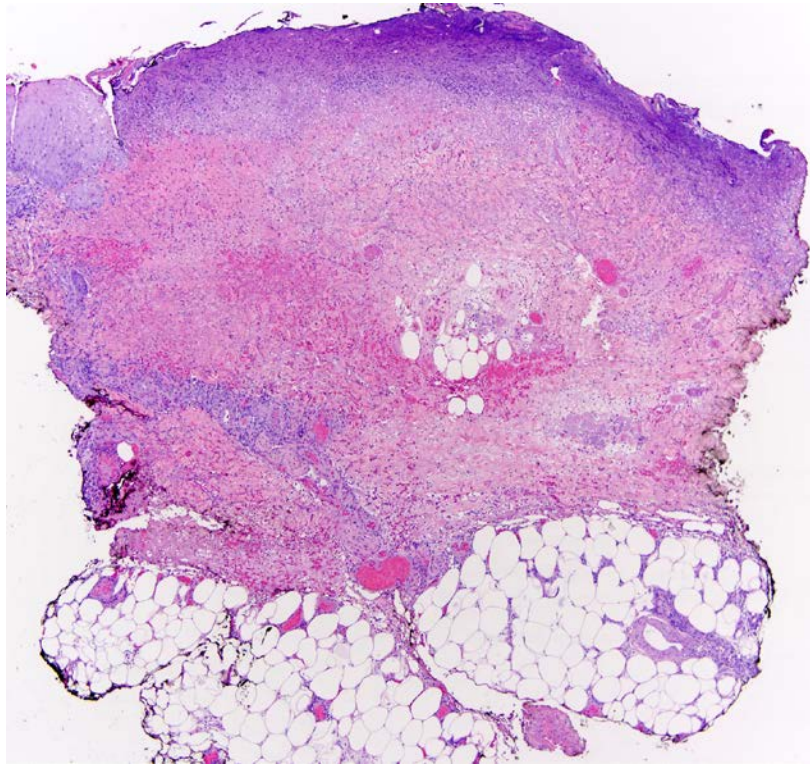


Figure 2. This low power view of the skin biopsy shows striking cutaneous necrosis. There is ulceration with marked degenerative alterations of the subjacent dermis. Extensive hemorrhage due to vascular compromise is identified (Hematoxylin and Eosin, 100x).

The post-eculizumab biopsy of the recurrent ulcerated skin showed striking cutaneous necrosis. The necrosis was most dramatic superficially where there was also an admixture of polarizable exogenous material. The necrotic zone was flanked by viable epithelium. The vessels in the immediate vicinity of the ulcer demonstrated severe endothelial cell injury and occlusive thrombi.

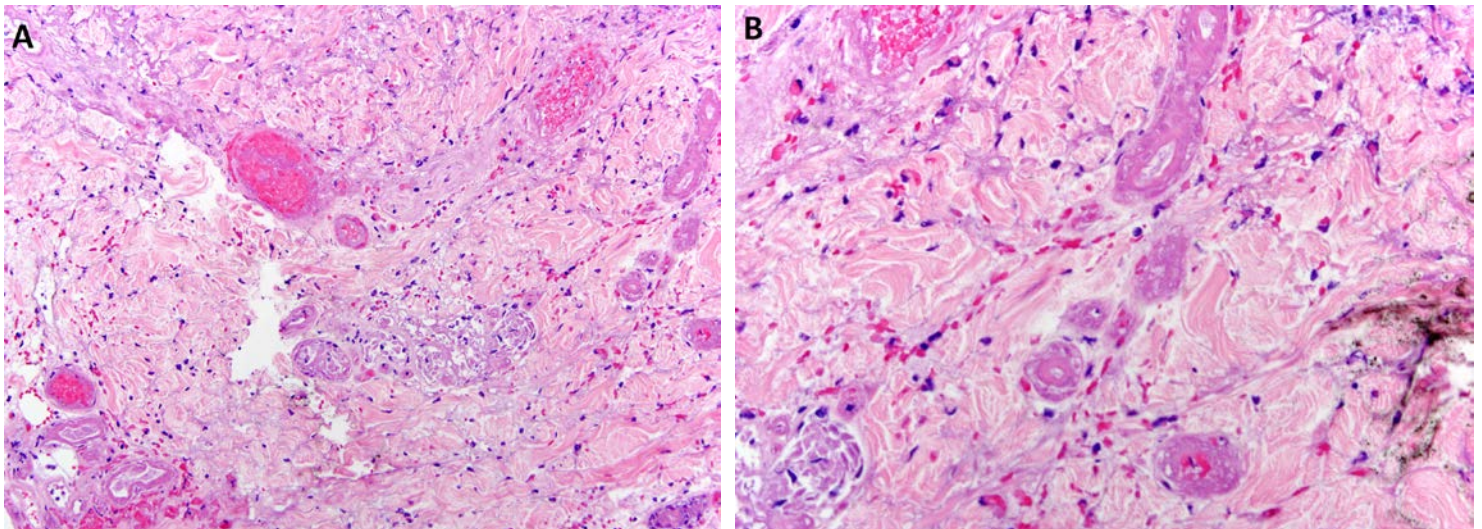


Figure 3A, 3B. Peripheral to the area of epidermal and dermal necrosis there is abrupt necrolytic alteration of the eccrine coil in a fashion almost reminiscent of barbiturate induced eccrine coil necrosis (3A). The vessels in the immediate vicinity of the ulcer demonstrated severe endothelial cell injury with frank endothelial cell detachment and intraluminal thrombus formation (3B). (Hematoxylin and Eosin, 400x)

There was eccrine coil necrosis in a fashion almost reminiscent of barbiturate induced eccrine coil necrosis. The small bowel biopsy showed a pauci-inflammatory thrombotic vasculopathy involving vessels of the lamina propria.

Immunohistochemical and direct immunofluorescent assessment

The paraffin embedded formalin fixed tissue of her skin was assessed immunohistochemically. Unlike classic Degos disease, there was no evidence of an upregulated type I interferon microenvironment as revealed by the lack of staining for MXA in any of the biopsies either pre- or post-eculizumab. In the post-eculizumab biopsy, the caspase 3, an apoptotic marker [11-13], was

surprisingly negative despite the extensive degenerative changes of the endothelial cells, suggesting abrupt necrosis rather than controlled apoptosis.

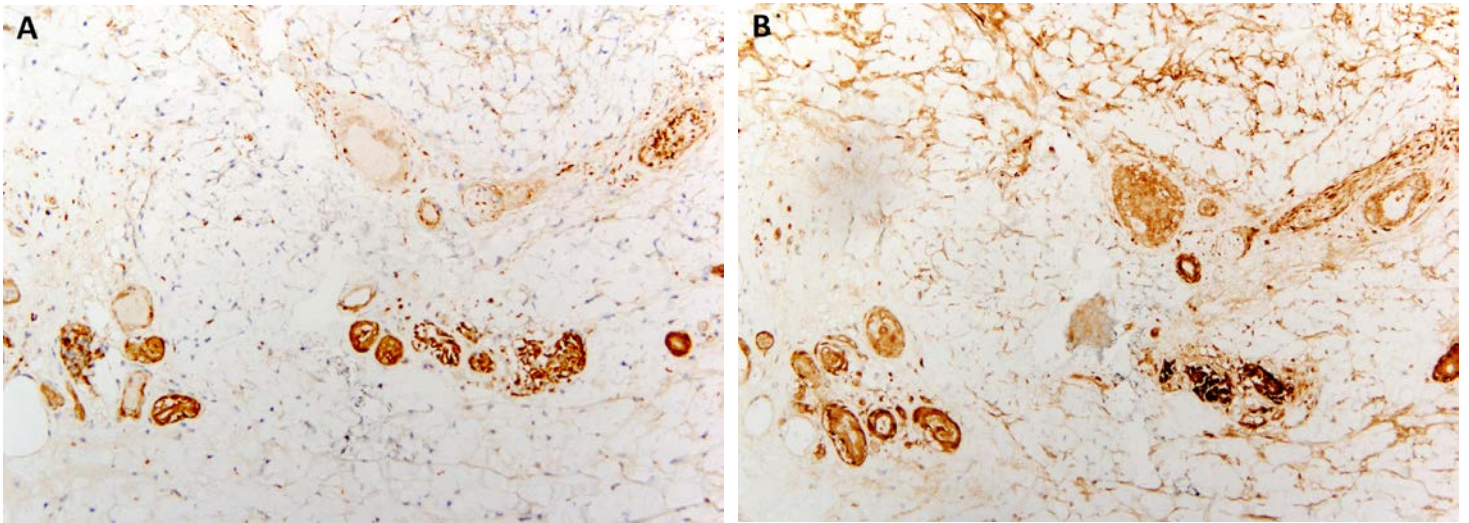


Figure 4A, 4B. The C3d and C4d stains show extensive staining within vessels throughout the cutaneous vasculature (A. C3d, B. C4d, 400x).

In the pre-eculizumab skin and gastrointestinal biopsies there was striking deposition of C3d, C4d and C5b-9 within the microvasculature. In the post-eculizumab biopsies there was marked deposition of C5b-9 within the thrombosed vessels primarily comprising capillaries and venules and the necrotic straight eccrine duct and eccrine coil.

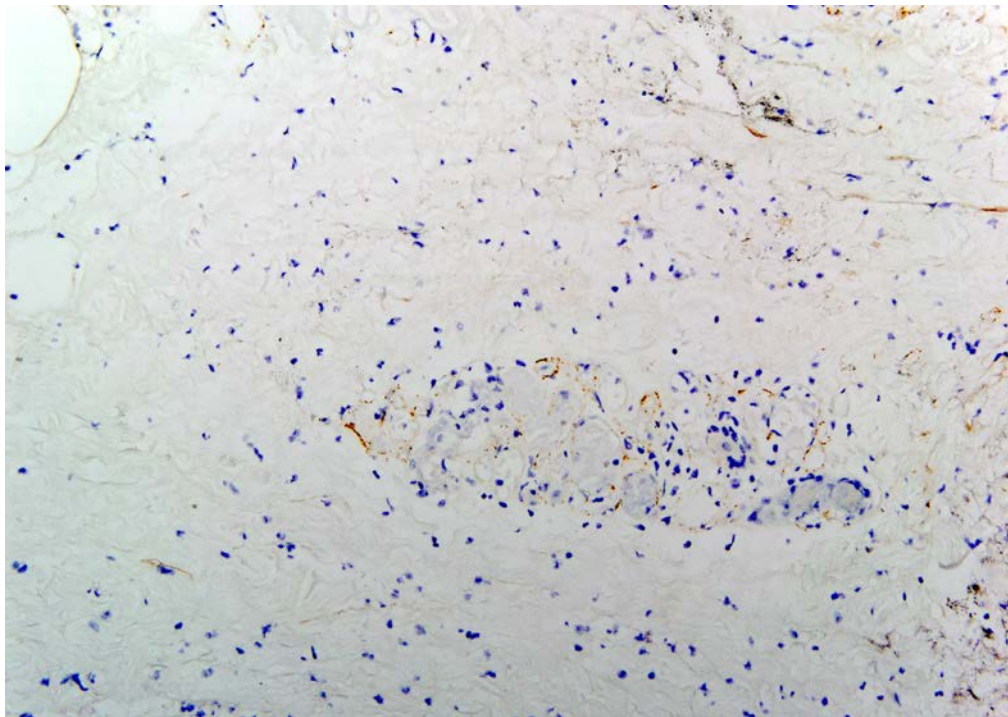


Figure 5. In the post-eculizumab biopsies, vessels without vascular thrombosis were relatively devoid of C5b-9 deposition (400x).

However, vessels without vascular thrombosis were relatively devoid of C5b-9 deposition.

In the post-eculizumab biopsy, the direct immunofluorescent studies on her skin biopsy were notable for a relative lack of immunoreactant deposition for all classes of immunoglobulin. Although there was focal intense staining for C3d and C4d, the C5b-9 preparation was essentially negative. Pre-eculizumab biopsy material was not available for direct immunofluorescent studies.

Discussion

There is now an emerging body of literature describing a severe thrombotic microangiopathy syndrome associated with acute renal failure and exhibiting in some cases atypical TTP- like features attributable to the intravenous administration of an oral formulation of the opioid oxycodone hydrochloride [14-17]. All of the reported patients were in their twenties and presented with severe kidney injury and peripheral blood hemolysis; thrombocytopenia was a frequent feature in the cases reported. In one previously reported patient there was a concomitant positive antinuclear anti-neutrophilic cytoplasmic antibody even though she did not have other features of Wegener's granulomatosis [18].

We have presented a patient who injected intravenously opioid oxycodone in whom thrombotic microangiopathic complications ensued but the clinical presentation lead physicians initially to conclude she had Degos disease.

Skin manifestations resulting from prolonged and habitual subcutaneous self-injection (skin-popping) of opioids and other related narcotics are distinctive although the pathogenetic mechanisms underlying the striking clinical picture have not been elucidated until now. Although the overall clinical presentation in this patient suggested a true idiopathic microvascular injury syndrome, namely Degos disease, this case serves to emphasize the potential for diverse clinical features associated with skin-popping reflective of the effects of the cutaneous injected narcotics at other distant critical organ sites. The putative agent gains extracutaneous systemic access through its passive absorption into the arborizing cutaneous microvasculature. The skin lesions of skin-popping are typically multiple and range in size from 0.5 to 3 cm, exhibiting a sharply demarcated oval to rounded depressed punch-out appearance. Areas on the body that provide easy access including the extensor surface of arms and dorsal surface of the hands, as well as abdomen and thighs, are preferentially involved. The clinical lesions in Degos disease/MAP also have a very circumscribed rounded depressed appearance reflecting the sequelae of microvascular compromise similar to the complement mediated thrombotic vasculopathy that appears to underly skin popping at least according to our studies. Unlike skin-popping, the lesions are not aggregated clustered ones involving a particular region of the body but rather exhibit a widely spread distribution most commonly on the extremities. In our patient the clinical diagnosis of Degos disease was based on the unusual combined cutaneous and gastrointestinal manifestations of pauci-inflammatory thrombotic small vessel compromise accompanied by prominent vascular deposits of C5b-9. When her hemodynamic compromise responded dramatically to eculizumab similar to that seen in other gravely ill patients with classic Degos disease, the discrete and unusual skin ulcers were simply held to represent a divergent clinical presentation from conventional Degos disease.

We have encountered very similar and striking changes of ischemic cutaneous disease in the context of the iatrogenic counterpart of skin-popping, namely Nicolau's syndrome. Varieties of drugs are implicated and include non-steroidal anti-inflammatory agents, analgesics and barbiturates. As with this case, the morphology is a pauci-inflammatory thrombotic vasculopathy with eccrine coil necrosis and prominent complement deposition within the microvasculature. In Nicolau's syndrome the area of iatrogenic cutaneous necrosis resembles purpura fulminans, warranting the designation of Nicolau's livedoid dermatitis. Many drugs are implicated including non-steroidal anti-inflammatory agents, penicillin, diclofenac, and gentamycin. At least one hypothesis relates to the administration of the drug within an artery. However, an intra-arterial localization of the drug is not always implicated. Other postulates include paraneural and periarterial extravasation with resultant reflux arterial vasospasm and direct compression of the injected area. In cases where the drug is injected more superficially the pathogenetic events are likely similar to the infarctive sequelae observed in the setting of skin popping. Regardless of whether a self-induced or iatrogenic scenario of perivascular superficial drug administration is implicated a localized cutaneous morphology simulating a catastrophic thrombotic microvascular injury syndrome is seen [19].

Even though she did not admit to directly injecting her skin with opioids, there are certain exogenous agents when injected locally evoke a very dramatic acute thrombotic event such as heparin, morphine, interferon alpha, and/or interferon beta resulting in severe vascular thrombosis and necrosis [14, 20-22]. The striking necrosis of the eccrine coil could be ischemic but it is also highly reminiscent of the changes noted in drug induced coma, barbiturate toxicity, and fatal theophylline intoxication [23-26].

From a histomorphologic perspective, the incipient lesion of classic Degos disease/MAP is characterized by florid mucin with angiocentric lymphocytic infiltrates in a fashion reminiscent of tumid lupus erythematosus. There is gradual vascular thrombosis eventuating into ischemic dermopathy changes [27] the latter is characterized by vascular dropout, fibrosis, and epidermal thinning resulting in the characteristic porcelain plaque. In contrast, the findings on the biopsy of our patient were all extremely acute whereby the insult was of such a magnitude that it resulted in abrupt necrosis of the eccrine coil and microvasculature. Her gastrointestinal biopsies were also unusual for Degos disease given the presence of vascular thrombi in the lamina propria. In classic Degos disease/MAP, the brunt of vascular changes affects small and medium sized arteries of the subserosa with endoscopic biopsies being characteristically normal [28-30].

Immunohistochemically, the skin and gastrointestinal biopsies in our patient did not demonstrate any staining for MXA, a type I interferon marker; the caspase 3 stain was negative as well, indicating that the endothelial cell injury was truly an acute event that had caused necrosis as opposed to a more controlled apoptotic pattern of endothelial cell degeneration. In virtually all patients with Degos disease, there is striking upregulation of MXA reflective of a type I interferon rich microenvironment. In addition,

caspase 3 endothelial cell staining is reflective of apoptosis as opposed to abrupt necrosis and is typical of Degos disease or other immunologically mediated forms of endothelial cell injury as noted in the setting of dermatomyositis and systemic lupus erythematosus. Over and above the lack of staining for MXA and caspase 3, immunofluorescent findings in our patient also did not support an immunologically mediated phenomenon.

The role for complement in the pathogenesis of opioid associated endotheliopathy has been further corroborated by the activation of the complement cascade by repeated injection of morphine with the generation of the highly potent C5a [31]. It has been shown that there is upregulation of C5a and C5a receptor (C5aR) in morphine tolerance and withdrawal-induced hyperalgesia. The authors demonstrated that the C5aR antagonist PMX53 blocked the development of these phenomena, a finding supportive of the effects of morphine exposure on the generation of C5a. A direct effect of C5a generation is one of intracellular activation of NF- κ B, which in turn enhances apoptosis [31].

One might suggest that an adulterant could be implicated. However, in the majority of cases the opioid is obtained from a drug clinic where adulterants would not be used. The polyethylene oxide could be causative. However, in other drugs using this agent a similar thrombotic diathesis has not been identified. Although microcrystalline particles were not detected in previously reported cases, we were able to find a talc-like substance in both her skin and lung biopsies.

Conclusion

We have presented a very dramatic example of the microvascular complications attributable to illicit intravenous opioid use. The mechanism of tissue injury is one induced by microvascular complement activation leading to endothelial cell injury and vascular thrombosis. It would appear that injected opioids are capable of creating disease states that closely recapitulate catastrophic multiorgan thrombotic syndromes. This unusual case emphasizes the grave microvascular complications of intravenous oral opioid injections. In this regard intravenous oral opioids must be considered in the differential diagnosis of catastrophic microvascular injury syndromes including thrombotic thrombocytopenic purpura, catastrophic antiphospholipid antibody syndrome, atypical hemolytic uremic syndrome, and Degos disease. The microscopic findings reflect the permissive effects of opioids on microvascular complement activation with resultant endothelial cell injury. Although the mechanism of microvascular complement deposition is different in idiopathic Degos disease, the end result in either scenario i.e. intravenous oral opioid injection versus Degos disease is identical. In our patient the administration of eculizumab likely saved her life. We feel that this case emphasizes the critical role of complement activation in the thrombotic complications of intravenous and local cutaneous opioid injection and serves to emphasize the efficacy of short-term eculizumab as an effective treatment option in patients with significant vascular compromise associated with intravascular oral opioid injection.

References

1. Nayer A, Asif A. Atypical Hemolytic-Uremic Syndrome: A Clinical Review. *Am J Ther.* 2014 Mar 27. [Epub ahead of print] [PMID: 24681522]
2. Nayer A, Ortega LM. Catastrophic antiphospholipid syndrome: a clinical review. *J Nephropathol.* 2014 Jan; 3(1): 9-17. [PMID: 24644537]
3. Shenkman B, Einav Y. Thrombotic thrombocytopenic purpura and other thrombotic microangiopathic hemolytic anemias: diagnosis and classification. *Autoimmun Rev* 2014 Apr-May; 13(4-5): 584-6. [PMID: 24418304]
4. Kappler S, Ronan-Bentle S, Graham A. Thrombotic microangiopathies (TTP, HUS, HELLP). *Emerg Med Clin North Am.* 2014 Aug; 32(3): 649-71. [PMID: 25060255]
5. Chalmers E, Cooper P, Forman K, Grimley C, Khair K, Minford A, Morgan M. Purpura fulminans: recognition, diagnosis and management. *Arch Dis Child* 2011 Nov; 96(11): 1066-71. [PMID: 21233082]
6. Lim W. Antiphospholipid syndrome. *Hematology Am Soc Hematol Educ Program.* 2013; 2013:675-80. [PMID: 24319251]
7. Kapila A, Chhabra L, Chaubey VK, Summers J. Opana ER abuse and thrombotic thrombocytopenic purpura (TTP)-like illness: a rising risk factor in illicit drug users. *BMJ Case Rep.* 2014 Mar 3; 2014. [PMID: 24591390]
8. Ambruzs JM, Serrell PB, Rahim N, Larsen CP. Thrombotic microangiopathy and acute kidney injury associated with intravenous abuse of an oral extended-release formulation of oxycodone hydrochloride: kidney biopsy findings and report of 3 cases. *Am J Kidney Dis.* 2014 Jun; 63(6): 1022-6. [PMID: 24529995]
9. Amjad AI, Parikh RA. Opana-ER used the wrong way: intravenous abuse leading to microangiopathic hemolysis and a TTP-like syndrome. *Blood.* 2013 Nov 14; 122(20): 3403. [PMID: 24369032]
10. Centers for Disease Control and Prevention (CDC). Thrombotic thrombocytopenic purpura (TTP)-like illness associated with intravenous Opana ER abuse--Tennessee, 2012. *MMWR Morb Mortal Wkly Rep.* 2013 Jan 11; 62(1):1-4. [PMID: 23302815]
11. Gu C, Casaccia-Bonnel P, Srinivasan A, Chao MV. Oligodendrocyte apoptosis mediated by caspase activation. *J Neurosci.* 1999 Apr 15; 19(8):3043-9.[PMID: 10191321]

12. Lin HI, Lee YJ, Chen BF, Tsai MC, Lu JL, Chou CJ, Jow GM. Involvement of Bcl-2 family, cytochrome c and caspase 3 in induction of apoptosis by beauvericin in human non-small cell lung cancer cells. *Cancer Lett.* 2005 Dec 18; 230(2): 248-59. [PMID: 16297711]
13. Ou JM, Yu ZY, Qiu MK, Dai YX, Dong Q, Shen J, Wang XF, Liu YB, Quan ZW, Fei ZW. Knockdown of VEGFR2 inhibits proliferation and induces apoptosis in hemangioma-derived endothelial cells. *Eur J Histochem.* 2014 Mar 17; 58(1): 2263. [PMID: 24704994]
14. Barańska-Rybak W, Błażewicz I, Kąkol M, Roter M, Nowicki R. Cutaneous manifestations of injectable drug use: hidden secrets. *Cutis.* 2014 Apr; 93(4): 185-7. [PMID: 24818177]
15. Crum ED, Bailey KM, Richards-Waugh LL, Clay DJ, Gebhardt MA, Kraner JC. Validation of blood and liver oxymorphone analysis using LC-MS-MS: concentrations in 30 fatal overdoses. *J Anal Toxicol* 2013 Oct; 37 (8): 512-6. [PMID: 23980120]
16. Prommer E. Oxymorphone: a review. *Supportive Care in Cancer* 2006 Feb; 14: 109-115. [PMID: 16317569]
17. Smith H.S. Clinical pharmacology of oxymorphone. *Pain Medicine* 2009; 10: S3-S10.
18. Ocaña Pérez E, Peña Casas AM, del Campo Muñoz T, Avila Casas A, Luque Barona R. [Wegener's granulomatosis with anti-neutrophil cytoplasmic antibodies against anti-cathepsin G antigen]. *An Pediatr (Barc).* 2013 Dec; 79(6):381-4. [PMID: 23602835]
19. Luton K, Garcia C, Poletti E, Koester G. Nicolau Syndrome: three cases and review. *Int J Dermatol* 2006 Nov; 45(11):1326-8. [PMID:17076716]
20. Choudhry S, Fishman PM, Hernandez C. Heparin-induced bullous hemorrhagic dermatosis. *Cutis* 2013 Feb; 91(2): 93-8. [PMID: 23513558]
21. Wells J, Kossard S, McGrath M. Abdominal wall ulceration and mucinosis secondary to recombinant human interferon-beta-1b. *Australas J Dermatol* 2005 Aug; 46(3): 202-4. [PMID: 16008658]
22. Ohata U, Hara H, Yoshitake M, et al. Cutaneous reactions following subcutaneous beta-interferon-1b injection. *J Dermatol* 2010 Feb; 37(2):179-81. [PMID: 20175855]
23. Sanchez Yus E, Requena L, Simon P. Histopathology of cutaneous changes in drug-induced coma. *Am J Dermatopathol.* 1993 Jun; 15(3): 208-16. [PMID: 8100121]
24. Chacon AH, Farooq U, Choudhary S, Yin N, Nolan B, Shiman M, Milikowski C, Izakovic J, Elgart GW. Coma blisters in two postoperative patients. *Am J Dermatopathol.* 2013 May; 35(3): 381-4. [PMID: 23334516].
25. Rocha J, Pereira T, Ventura F, Pardal F, Brito C. Coma Blisters. *Case Rep Dermatol.* 2009 Oct; 1(1): 66-70. [PMID: 20652118]
26. Tsokos M, Sperhake JP. Coma blisters in a case of fatal theophylline intoxication. *Am J Forensic Med Pathol.* 2002 Sep; 23(3): 292-4. [PMID: 12198361]
27. Anker JP, Kaminska-Winciorek G, Lallas A, Nicoletti S, Januszewski K, Mazzei ME, Wydmanski J, Borges AL, Zalaudek I. The dermoscopic variability of Degos disease at different stages of progression. *Dermatol Pract Concept* 2014; 4(3): 59-61. [PMID: 25126461]
28. Magro CM, Poe JC, Kim C, Shapiro L, Nuovo G, Crow MK, Crow YJ. Degos disease: a C5b-9/interferon- α -mediated endotheliopathy syndrome. *Am J Clin Pathol.* 2011Apr; 135(4):599-610.[PMID: 21411783]
29. Dyrksen ME, Iwenofu OH, Nuovo G, Magro CM. Parvovirus B19-associated catastrophic endothelialitis with a Degos-like presentation. *J Cutan Pathol* 2008; 35 Suppl 1: 20-5. [PMID: 18537856]
30. Magro CM, Wang X, Garrett-Bakelman F, Laurence J, Shapiro LS, DeSancho MT. The effects of Eculizumab on the pathology of malignant atrophic papulosis. *Orphanet J Rare Dis.* 2013 Nov 26; 8:185. [PMID: 24279613]
31. Li YH, Jin H, Xu JS, Guo GQ, Chen DL, Bo Y. Complement factor C5a and C5a receptor contribute to morphine tolerance and withdrawal-induced hyperalgesia in rats. *Exp Ther Med.* 2012 Oct; 4(4): 723-727. [PMID: 23170133]