

UCSF

UC San Francisco Previously Published Works

Title

A case of Bilateral Perisylvian Syndrome with reading disability

Permalink

<https://escholarship.org/uc/item/7dc7z32v>

Authors

Eckert, Mark A
Berninger, Virginia W
Hoeft, Fumiko
[et al.](#)

Publication Date

2016-03-01

DOI

10.1016/j.cortex.2016.01.004

Peer reviewed



Published in final edited form as:

Cortex. 2016 March ; 76: 121–124. doi:10.1016/j.cortex.2016.01.004.

A Case of Bilateral Perisylvian Syndrome with Reading Disability

Mark A. Eckert^a, Virginia W. Berninger^b, Fumiko Hoeft^c, Kenneth I. Vaden Jr.^a, and Dyslexia Data Consortium

^aDepartment of Otolaryngology – Head and Neck Surgery, Medical University of South Carolina, Charleston, S.C., 29425-5500

^bDepartment of Educational Psychology, University of Washington, Seattle, W.A., 98195-3600

^cDepartment of Psychiatry, University of California San Francisco, San Francisco, C.A., 94143-2211

Keywords

Bilateral Perisylvian Syndrome; Dyslexia; Reading Disability; Sylvian Fissure

Bilateral Perisylvian Syndrome (BPS) often presents with epilepsy and significant behavioral impairments that can include mental retardation, dysarthria, delayed speech development, and delayed fine motor development (Graff-Radford et al., 1986; Kuzniecky et al., 1993). While a small subset of BPS cases have been described as having relatively isolated language delays (Leventer et al., 2010), BPS is not expected in children with dyslexia. As part of a Medical University of South Carolina IRB approved multi-site study involving retrospective and de-identified dyslexia data, we unexpectedly identified a 14.05 year old male with evidence of BPS whose father had been diagnosed with dyslexia and dysgraphia. This child had been recruited for a neuroimaging study on dyslexia from a school specializing in educating children with dyslexia. The T1-weighted MRI scan from this child demonstrated a highly unusual perisylvian sulcal/gyral patterning that is a defining feature of BPS (Figure 1). BPS cases exhibit bilateral dysgenesis of the Sylvian fissure and surrounding gyri, which appears to occur because of a limited or absent arcuate fasciculus (Kilinc et al., 2015). This BPS case also had a relatively enlarged atrium of the lateral ventricle that is consistent with the BPS anatomical presentation and reduction of parietal white matter (Graff-Radford et al., 1986; Kilinc et al., 2015; Toldo et al, 2011).

An automated analysis of SPM8 segmented T1-weighted MRI scans was used to determine the degree to which the BPS native space white matter image (rigidly aligned and non-normalized) exhibited gross morphological dis-similarity to white matter images from age and gender matched cases. This image covariance approach provided an average similarity measure for the BPS case and images from 10 control and 19 reading disabled cases across 7 research sites who were selected from 172 males enrolled in reading disability studies, had

Address Correspondence To: Mark A. Eckert, Ph.D., 135 Rutledge Ave, MSC550, Department of Otolaryngology – Head and Neck Surgery, Medical University of South Carolina, Charleston, S.C., 29425-5500, eckert@musc.edu.

The authors have no conflicts of interest.

T1-weighted images, and were within a 2 year age range of the BPS case (13.27–15.05 years). Image similarity was calculated using the VBM8 Toolbox homogeneity of image variance function that provides covariance estimates across spatially corresponding voxels for each pair of images. An average estimate was calculated for each case to obtain a single similarity estimate for each image relative to the rest of the sample. The BPS case had a white matter similarity estimate that was more than 2 standard deviations below the mean of the control and reading disability groups, but exhibited a total white matter volume estimate that was within the normal range of control and reading disability cases (Figure 2).

The BPS case did not exhibit evidence of general cognitive problems, but instead exhibited a behavioral profile that is consistent with a dyslexia diagnosis. He demonstrated relatively average general cognitive function compared to below average phonological processing skills (Figure 1). His Matrix Reasoning, Peabody Picture Vocabulary Test Receptive Vocabulary knowledge, and Rapid Automatic Naming for letters, numbers, and colors were in the normal range. However, he demonstrated below average Woodcock-Johnson measures of pseudo-word and real word decoding, reading comprehension, spelling, writing fluency, and Comprehensive Test of Phonological Processing memory for digits. Particularly low fluency summary scores from the Gray Oral Reading Tests and Test of Word Reading Efficiency indicated a significant deficit in rapid access to lexical information compared to sub-lexical information given his relatively normal Rapid Automatic Naming of Letter scores. In summary, an incidental BPS finding with characteristic Sylvian fissure dysgenesis had a behavioral profile that was consistent with dyslexia.

Variable expression of gene(s) in Xq27.3, where an X-linked pattern of BPS inheritance has been identified (Santos et al., 2008) and where a marker for dyslexia has also been identified (de Kovel et al., 2004; Huc-Chabrolle et al., 2013), appear to contribute to the expression of a dyslexia behavioral profile. Like other genetic markers for dyslexia, however (Raskind et al., 2012), DYX9 linkage to dyslexia has been inconsistent (Fisher et al., 2013). Inadvertant inclusion of neurogenetic disorders with mild symptoms may contribute to inconsistent dyslexia findings. The use of an image similarity metric, which effectively identified the BPS case from control and reading disability cases compared to a total white matter volume measure, could identify cases with highly unusual brain morphology in large imaging-genetics consortium studies where investigator inspection of images may miss unusual cases. Such an approach might uncover additional cases with BPS who have a dyslexia diagnosis, but have not been identified because of their relatively mild symptoms.

Relatively mild BPS symptoms are consistent with the absence of epilepsy (Yasuda et al., 2014) and perhaps relatively normal total white matter volume (Figure 2) despite likely dysgenesis of the arcuate fasciculus (Kilinc et al., 2015). Variable expressivity of characteristic BPS phenotypes is consistent with recent evidence that mosaic mutations of the PIK3R2 gene can occur in patients with bilateral polymicrogia and normal head size (Mirzaa et al., 2015). Whether due to PIK3R2 mosaicism or other genetic and perinatal events (Stutterd & Leventer, 2014), variable expression of the BPS clinical profile appears to include mild impairments that can present as a reading disability.

Acknowledgments

Members of the Dyslexia Data Consortium during preparation of this manuscript include C. Beaulieu, V. Berninger, X. Castellanos, C. Chiarello, T. Conway, L. Cutting, G. Dehaene-Lambertz, G. Eden, R. Frye, D. Giaschi, J. Gilger, F. Hoeft, M. Kibby, K. van Krigstein, M. Kronbichler, C. Leonard, M. Milham, T. Odegard, R. Poldrack, K. Pugh, T. Richards, N. Rollins, K. Schneider, J. Talcott, and B. Wandell. This work was supported by 5R01HD069374. This investigation was conducted in a facility constructed with support from Research Facilities Improvement Program (C06 RR14516) from the National Center for Research Resources, National Institutes of Health.

References

- De Kovel CGF, Hol FA, Heister JGAM, Willems JJHT, Sandkuijl LA, Franke B, Padberg GW. Genomewide scan identifies susceptibility locus for dyslexia on Xq27 in an extended Dutch family. *Journal of Medical Genetics*. 2004; 41(9):652–657. [PubMed: 15342694]
- Fisher SE, Francks C, Marlow AJ, MacPhie IL, Newbury DF, Cardon LR, Ishikawa-Brush Y, Richardson AJ, Talcott JB, Gayan J, Olson RK, Pennington BF, Smith SD, DeFries JC, Stein JF, Monaco AP. Independent genome-wide scans identify a chromosome 18 quantitative-trait locus influencing dyslexia. *Nature Genetics*. 2002; 30(1):86–91. [PubMed: 11743577]
- Fletcher JM. Dyslexia: The evolution of a scientific concept. *Journal of the International Neuropsychological Society*. 2009; 15(4):501. [PubMed: 19573267]
- Graff-Radford NR, Bosch EP, Stears JC, Tranel D. Developmental Foix-Chavany-Marie syndrome in identical twins. *Annals of Neurology*. 1986; 20(5):632–635. [PubMed: 3789677]
- Huc-Chabrolle M, Charon C, Guilmatre A, Vourc'h P, Tripi G, Barthez MA, Sizaret E, Thepault RA, Le Gallic S, Hager J, Toutain A, Raynaud M, Andres C, Campion D, Laumonnier F, Bonnet-Brilhault F. Xq27 FRAXA locus is a strong candidate for dyslexia: evidence from a genome-wide scan in French families. *Behavior Genetics*. 2013; 43(2):132–140. [PubMed: 23307483]
- Kilinc O, Ekinci G, Demirkol E, Agan K. Bilateral agenesis of arcuate fasciculus demonstrated by fiber tractography in congenital bilateral perisylvian syndrome. *Brain and Development*. 2015; 37(3):352–355. [PubMed: 24852949]
- Kuzniecky R, Andermann F, Guerrini R, Study TCMC. Congenital bilateral perisylvian syndrome: study of 31 patients. *The Lancet*. 1993; 341(8845):608–612.
- Leventer RJ, Jansen A, Pilz DT, Stoodley N, Marini C, Dubeau F, Malone J, Mitchell LA, Mandelstam S, Scheffer IE, Berkovic SF. Clinical and imaging heterogeneity of polymicrogyria: a study of 328 patients. *Brain*. 2010:awq078.
- Mirzaa GM, Conti V, Timms AE, Smyser CD, Ahmed S, Carter M, Barnett S, Hufnagel RB, Goldstein A, Narumi-Kishimoto Y, Olds C. Characterisation of mutations of the phosphoinositide-3-kinase regulatory subunit, PIK3R2, in perisylvian polymicrogyria: a next-generation sequencing study. *The Lancet Neurology*. 2015; 14(12):1182–1195. [PubMed: 26520804]
- Raskind WH, Peter B, Richards T, Eckert MA, Berninger VW. The genetics of reading disabilities: from phenotypes to candidate genes. *Frontiers of Psychology*. 2012; 3:601.
- Santos NF, Secolin R, Brandao-Almeida IL, Silva MS, Torres FR, Tsuneda SS, Guimaraes CA, Hage SR, Cendes F, Guerreiro MM, Lopes-Cendes I. A new candidate locus for bilateral perisylvian polymicrogyria mapped on chromosome Xq27. *American Journal of Medical Genetics Part A*. 2008; 146A:1151–1157. [PubMed: 18384144]
- Silliman ER, Berninger VW. Cross-disciplinary dialogue about the nature of oral and written language problems in the context of developmental, academic, and phenotypic profiles. *Topics in Language Disorders*. 2011; 31(1):6–23.
- Stutterd CA, Leventer RJ. Polymicrogyria: A common and heterogeneous malformation of cortical development. *American Journal of Medical Genetics Part C: Seminars in Medical Genetics*. 2014; 166(2):227–239.
- Toldo I, Calderone M, Sartori S, Mardari R, Gatta M, Boniver C, Guerrini R, Battistella PA. Bilateral perisylvian polymicrogyria with cerebellar dysplasia and ectopic neurohypophysis. *Journal of Child Neurology*. 2011; 26(3):361–365. [PubMed: 21273507]

Yasuda CL, Guimarães CA, Guerreiro MM, Boscariol M, Oliveira EP, Teixeira KC, Costa L, Beltramini GC, Cendes F. Voxel-based morphometry and intellectual assessment in patients with congenital bilateral perisylvian syndrome. *Journal of Neurology*. 2014; 261(7):1374–1380. [PubMed: 24781839]

Author Manuscript

Author Manuscript

Author Manuscript

Author Manuscript

Highlights

An unexpected case of Bilateral Perisylvian Syndrome (BPS) with dyslexia was identified.

The BPS case had Sylvian fissure dysgenesis, but not typical BPS cognitive and gross motor deficits.

An automated white matter image similarity metric distinguished the BPS case from controls.

Mild BPS can be expressed as dyslexia or reading disability.

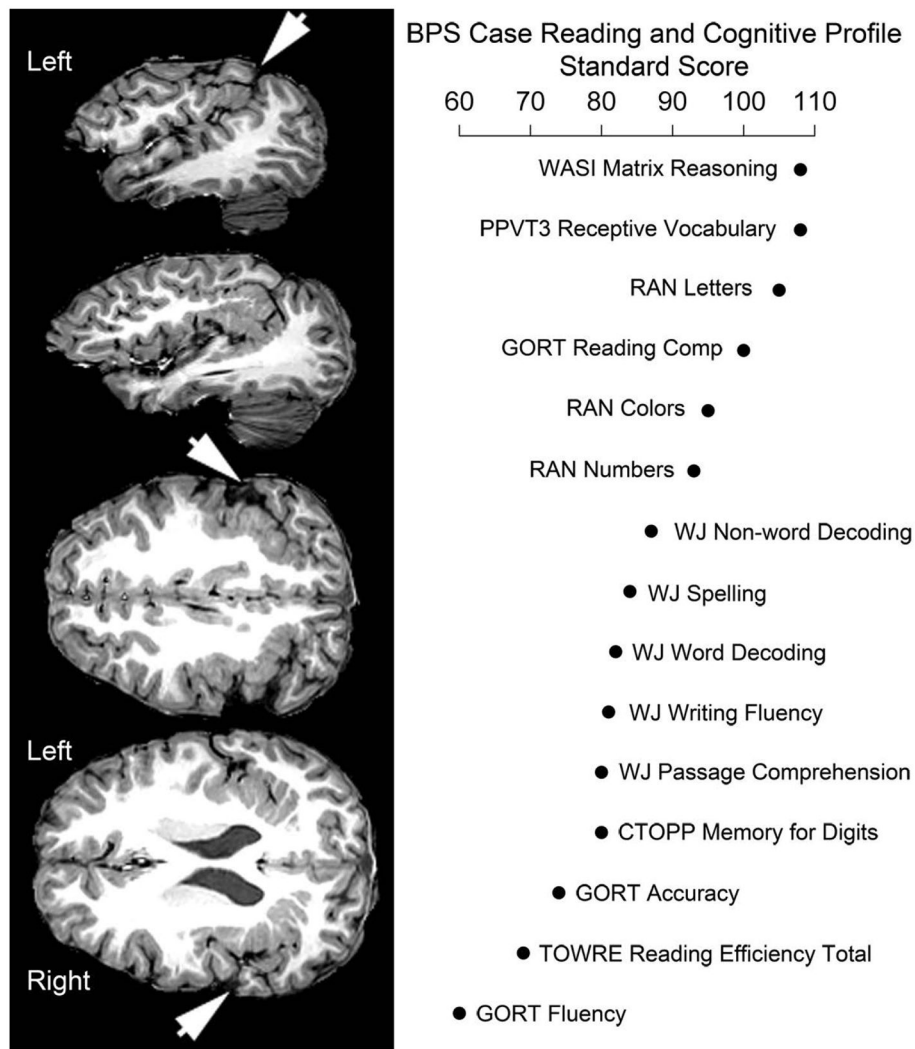


Figure 1.

T1-weighted image sections from a 14.05 year old male with evidence of BPS. Left: Note the atypical formation of the Sylvian fissure (arrows) that merges with the intraparietal sulcus and surrounding polymicrogyria. Right: Standardized scores for cognitive assessments that were available for the BPS case. Performance in the normal range was observed for Wechsler Matrix Reasoning, Peabody Picture Vocabulary Test Receptive Vocabulary knowledge, and Rapid Automatic Naming for letters, numbers, and colors. Below average performance was observed for Woodcock-Johnson measures of pseudo-word and real word decoding, reading comprehension, spelling, writing fluency, and Comprehensive Test of Phonological Processing memory for digits. Particularly low Gray Oral Reading Tests and Test of Word Reading Efficiency fluency summary scores indicated a significant deficit in rapid access to lexical information compared to sub-lexical information given his relatively normal RAN Letter scores. Comprehensive Test of Phonological Processing (CTOPP); Gray Oral Reading Tests (GORT); Peabody Picture Vocabulary Test (PPVT3); Rapid Automatized Naming (RAN); Test of Word Reading Efficiency (TOWRE); Woodcock-Johnson (WJ)

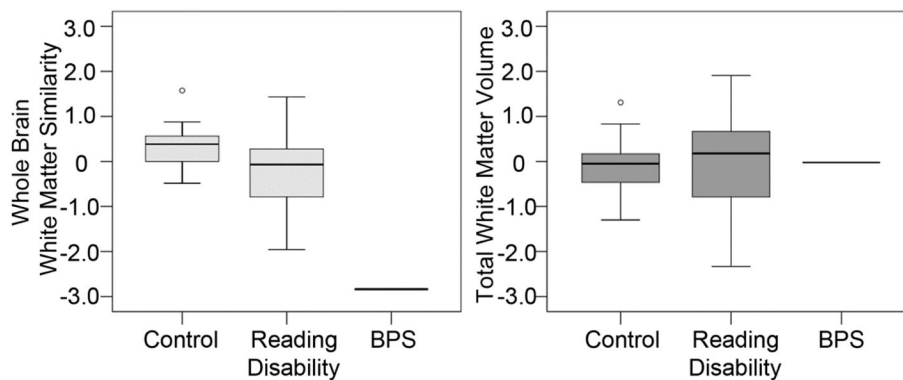


Figure 2.

Left: The BPS case had a white matter image similarity estimate (scaled score that was adjusted for potential effects of scanner differences across the 7 sites) that was more than 2 standard deviations below the mean of 10 male control cases and 19 male reading disability cases who were selected to be aged matched to the BPS case. Gray matter image similarity did not characterize the BPS case as an outlier despite the atypical Sylvian fissure patterning and cortical dysplasia that is consistent with polymicrogyria. Right: The BPS case was not an outlier when examining total white matter volume that was estimated from the summed voxel probabilities from native space white matter images that were segmented with default segmentation parameters using SPM8.