

# **UCLA**

## **Proceedings of UCLA Health**

### **Title**

Rapid-Onset Drug Induced Liver Injury in a Patient Receiving Intravenous Acetaminophen

### **Permalink**

<https://escholarship.org/uc/item/7d2213gg>

### **Journal**

Proceedings of UCLA Health, 27(1)

### **Authors**

Zhang, Derek

Saab, Faysal

### **Publication Date**

2024-02-13

## CLINICAL VIGNETTE

# Rapid-Onset Drug Induced Liver Injury in a Patient Receiving Intravenous Acetaminophen

Derek Zhang and Faysal Saab, MD

### Case Description

A female in her late 50s was admitted for chronic abdominal pain. She has prothrombin/MTHFR with prior superior mesenteric artery thrombosis status-post bowel resection and right hemicolectomy with resulting short bowel syndrome, (TPN) dependence. The pain was around her ostomy site and increased with TPN infusion. She did not receive TPN for the three days prior to her admission, and reported some oral intake. After admission she was given intravenous (IV) hydromorphone 0.5mg every 4 hours as needed for severe pain in addition to scheduled IV acetaminophen (APAP) 1000mg every 8 hours.

On admission, the patient's labs included: AST 48 units/L; ALT 43 units/L; alkaline phosphatase (AP) 152 IU/L. The first evening, she received her first 1g dose of IV APAP. The following morning labs showed: AST 455; ALT 278; AP 315. The

remainder of the patient's chemistries, lactate, and gamma-glutamyl transferase were within normal limits. She received a second dose in the morning, before discontinuing APAP. Right upper quadrant ultrasound was negative for acute pathology. The only other medications that the patient received were hydromorphone, ondansetron and continued chronic warfarin. Over the next four days, the patient's AST, ALT, and AP gradually returned to baseline. With the absence of other etiologies, as well as normalization of transaminases after stopping APAP, her laboratory abnormalities were thought to be IV APAP drug induced liver injury. The patient was rechallenged with IV APAP later in the hospitalization without recurrence in liver injury. The trend of liver enzymes is presented in Figure 1.

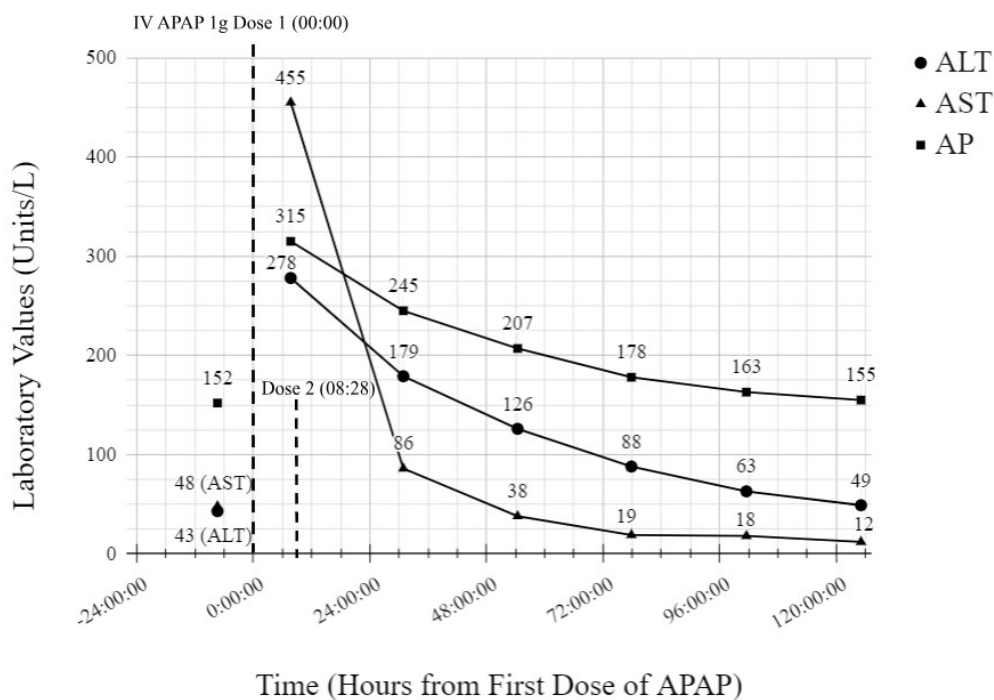


Figure 1. ALT, AST, and AP plotted across time (in hours from initial dose).

## Discussion

Drug-induced liver injury (DILI) remains difficult to diagnose as it does not have characteristic laboratory, imaging, or histologic findings. Diagnosis is made after excluding other etiologies of hepatotoxicity, considering the timing of liver injury with the administration of the drug, as well as improvement in laboratory parameters after drug cessation.<sup>1</sup> Clinicians can use the official National Institutes of Health (NIH) database LiverTox to determine if a specific medication has been linked to DILI.

There are two types of DILI: direct and idiosyncratic. Direct hepatotoxicity arises when agents cause hepatotoxicity in a well-established, dose-dependent, reproducible manner. Direct DILI occurs rapidly, with onset one to five days from exposure. Idiosyncratic hepatotoxicity are rare cases of liver injury that cannot be reliably reproduced for a given substance and are not dose-dependent. The onset of idiosyncratic DILI is typically slower, ranging from five days to several months after starting a medication. The pathophysiology of idiosyncratic DILI is not well understood.<sup>1</sup>

Management of DILI primarily involves discontinuing the culprit medication and treating sequelae of liver injury. Most patients are asymptomatic with elevated transaminases DILI.<sup>1</sup> However, severe DILI can lead to acute liver failure. In Western countries, more than half the cases of acute liver failure are due to DILI. Over 50% of these result from oral APAP ingestion.<sup>1,2</sup>

Acetaminophen (N-acetyl-P-aminophenol or APAP) is a centrally-acting analgesic and antipyretic that has been FDA-approved for over the counter use since 1951.<sup>3</sup> Although oral formulations have long been in use, the IV formulation of APAP was approved in 2010.<sup>3</sup> Intravenous APAP is theorized to have improved drug penetration into the CSF, faster time to peak plasma concentration, and reduced risk of hepatotoxicity.<sup>4</sup> This, in combination with its ease of administration, makes it an attractive option inpatient analgesia; especially for patients unable to tolerate oral medication.

APAP causes a dose-dependent, intrinsic form of liver injury, a form of direct DILI. The primary mechanism of its toxicity comes from the conversion of a minority (roughly 10%) of ingested APAP into the toxic metabolite NAPQI (N-acetyl-p-benzo-quinone imine) during hepatic, first-pass metabolism. At subtoxic doses, the antioxidant hepatic glutathione (GSH) is able to conjugate the small amount of NAPQI before substantial liver injury occurs. However, at higher doses, the amount of NAPQI generated depletes the body's stores of GSH, leading to rapid accumulation of the toxic metabolite.<sup>2</sup> Since the conversion of NAPQI is mediated by the enzyme CYP2E1, situations leading to the upregulation of this, including chronic alcohol use, certain drugs increase the generation of NAPQI and subsequent risk of liver injury. Conversely, fasting states, chronic liver disease, and advanced age, can lead to reduced GSH stores in the liver, also increasing risk of DILI.<sup>1,2</sup> Intravenous APAP, which bypasses hepatic first-pass

metabolism, is thought to generate less NAPQI when compared to oral APAP, thereby reducing risk of DILI.<sup>4,5</sup>

Although APAP toxicity can precipitate acute liver failure, the majority of APAP-associated DILI results in asymptomatic aminotransferase elevations that resolve with cessation of the drug.<sup>6</sup> This effect may be common, especially if APAP is taken at high doses over several days. A 2006 randomized controlled trial monitored subjects receiving APAP therapy, 76% of the examined patients (n=106) developed ALT above the upper limit of normal when receiving 4gm of oral APAP daily over the two-week trial period, with the elevation typically occurring after three days of use.<sup>7</sup>

There are few published cases of IV APAP-associated DILI. All patients had risk factors predisposing them to DILI. One case report involved a 36-year-old who presented with several days of nausea and vomiting, likely resulting in decreased nutrition and therefore stores of GSH.<sup>8</sup> Another, was a 92-year-old post-surgery, whose advanced age, post-operative status, and catabolic state likely contributed to increased risk of DILI.<sup>9</sup> Another patient with orthotopic liver transplant developed DILI two days after receiving therapeutic doses of IV and PO APAP after prostatectomy. The authors speculated that the transplanted liver did not carry as much GSH stores either due to post-transplant reperfusion or cold storage preservation.<sup>10</sup> The latency of onset ranged from two to six days. In two of the three cases, DILI occurred only after several days of maximally dosed IV APAP, 4gm/day, a pattern similar to that observed with oral APAP ingestion.<sup>8-10</sup>

Our patient is similar to those previously reported. Our patient had chronic malnutrition, given short bowel syndrome and several days without TPN, likely predisposing her to DILI from APAP. This may explain why she did not develop DILI upon rechallenge with IV APAP several days later, after receiving multiple days of TPN. Our case differs from previously reported as her DILI occurred less than 8 hours after drug exposure with a single administration of 1g of APAP. It is unlikely that our patient developed liver injury from any other etiology, as imaging and additional labs were unremarkable. The only other medications that the patient received prior to her DILI were ondansetron, hydromorphone, and warfarin. Serotonin type 3 (5-HT<sub>3</sub>) receptor antagonists like ondansetron have rarely been associated with DILI, but typically between 1 to 2 weeks of use, with mild enzyme elevations.<sup>6</sup> Hydromorphone is not associated with DILI.<sup>6</sup> Our patient had taken warfarin chronically without issue, making it unlikely for her DILI. Our case illustrates rapid occurring DILI from a single 1g dose of IV APAP, which has not been previously described.

## Conclusion

DILI may occur after administration of APAP, though is more typically associated with oral APAP. IV APAP is a recently approved form of APAP that is theorized to have lower risk of

DILI. Although few cases have been reported, IV APAP has also been shown to induce DILI, particularly in patients with comorbid malnutrition, chronic illness, advanced age, or other risk factors which reduce the liver's ability to clear toxic metabolites generated from APAP. The latency of DILI for IV APAP ranges from 1-6 days, with multiple cases showing injury only after several consecutive days of around-the-clock dosing. It is important for clinicians to recognize IV APAP-induced DILI as a possible etiology of liver injury in the inpatient setting, even after low, infrequent doses, as IV APAP is increasingly utilized for pain control.

Transplant Patient. *The American Journal of Gastroenterology* 114():p S1368-S1369, October 2019. | DOI: 10.14309/01.ajg.0000599468.03430.0f

## REFERENCES

1. **Hoofnagle JH, Björnsson ES.** Drug-Induced Liver Injury - Types and Phenotypes. *N Engl J Med.* 2019 Jul 18;381(3):264-273. doi: 10.1056/NEJMra1816149. PMID: 31314970.
2. **Bunchorntavakul C, Reddy KR.** Acetaminophen (APAP or N-Acetyl-p-Aminophenol) and Acute Liver Failure. *Clin Liver Dis.* 2018 May;22(2):325-346. doi: 10.1016/j.cld.2018.01.007. Epub 2018 Feb 9. PMID: 29605069.
3. **OFIRMEV (Acetaminophen).** Published online March 2018. [www.fda.gov/medwatch](http://www.fda.gov/medwatch). Available at: [https://www.accessdata.fda.gov/drugsatfda\\_docs/label/2018/022450s011lbl.pdf](https://www.accessdata.fda.gov/drugsatfda_docs/label/2018/022450s011lbl.pdf).
4. **Tompkins DM, DiPasquale A, Segovia M, Cohn SM.** Review of Intravenous Acetaminophen for Analgesia in the Postoperative Setting. *Am Surg.* 2021 Nov;87(11):1809-1822. doi: 10.1177/0003134821989056. Epub 2021 Jan 30. PMID: 33522265.
5. **Dart RC, Rumack BH.** Intravenous acetaminophen in the United States: iatrogenic dosing errors. *Pediatrics.* 2012 Feb;129(2):349-53. doi: 10.1542/peds.2011-2345. Epub 2012 Jan 23. PMID: 22271694.
6. **LiverTox: Clinical and Research Information on Drug-Induced Liver Injury [Internet].** Bethesda (MD): National Institute of Diabetes and Digestive and Kidney Diseases; 2012-. PMID: 31643176.
7. **Watkins PB, Kaplowitz N, Slattery JT, Colonese CR, Colucci SV, Stewart PW, Harris SC.** Aminotransferase elevations in healthy adults receiving 4 grams of acetaminophen daily: a randomized controlled trial. *JAMA.* 2006 Jul 5;296(1):87-93. doi: 10.1001/jama.296.1.87. PMID: 16820551.
8. **Lee PJ, Shen M, Wang S, Spiegler P, Caraccio T, DeMuro JP, Malone B.** Possible hepatotoxicity associated with intravenous acetaminophen in a 36-year-old female patient. *P T.* 2015 Feb;40(2):123-32. PMID: 25673962; PMCID: PMC4315114.
9. **Seifert SA, Kovnat D, Anderson VE, Green JL, Dart RC, Heard KJ.** Acute hepatotoxicity associated with therapeutic doses of intravenous acetaminophen. *Clin Toxicol (Phila).* 2016 Mar;54(3):282-5. doi: 10.3109/15563650.2015.1134798. Epub 2016 Jan 14. PMID: 26763284.
10. **Khuc T, Selim K.** 2484 Intravenous Acetaminophen Associated With Hepatotoxicity in an Orthotopic Liver