

# UC Davis

## Dermatology Online Journal

### Title

Pseudoepitheliomatous, keratotic, and micaceous balanitis mimicking lichen sclerosus et atrophicus

### Permalink

<https://escholarship.org/uc/item/7c33g14w>

### Journal

Dermatology Online Journal, 26(9)

### Authors

Tonin, Beatrice  
Catenaro, Roberta  
Girolomoni, Giampiero  
et al.

### Publication Date

2020

### DOI

10.5070/D3269050171

### Copyright Information

Copyright 2020 by the author(s). This work is made available under the terms of a Creative Commons Attribution-NonCommercial-NoDerivatives License, available at <https://creativecommons.org/licenses/by-nc-nd/4.0/>

Peer reviewed

# Pseudoepitheliomatous, keratotic, and micaceous balanitis mimicking lichen sclerosus et atrophicus

Beatrice Tonin<sup>1</sup> MD, Roberta Catenaro<sup>1</sup> MD, Giampiero Girolomoni<sup>1</sup> MD, Claudio Ghimenton<sup>2</sup> MD, Paolo Gisondi<sup>1</sup> MD

Affiliations: <sup>1</sup>Section of Dermatology, Department of Medicine, University of Verona, Verona, Italy, <sup>2</sup>Section of Pathology, Department of Pathology and Diagnostics, University of Verona, Verona, Italy

Corresponding Author: Beatrice Tonin MD, Section of Dermatology, Department of Medicine, University of Verona, Piazzale A. Stefani n. 1, 37126 Verona, Italy, Tel: 39-0458122547, Email: [beatrice.tonin18@gmail.com](mailto:beatrice.tonin18@gmail.com)

## Abstract

We present a man in his 70s with a hyperkeratotic whitish plaque over the internal prepuce and glans. The lesion was slowly growing for four years prior to presentation and was resistant to several topical treatments. The histological examination of the lesion revealed marked hyperkeratosis and pseudoepitheliomatous hyperplasia, supporting the diagnosis of pseudoepitheliomatous, keratotic, and micaceous balanitis. It is important to be aware of this uncommon but potentially malignant condition affecting elderly men.

*Keywords: balanitis, glans, keratotic, pseudoepitheliomatous*

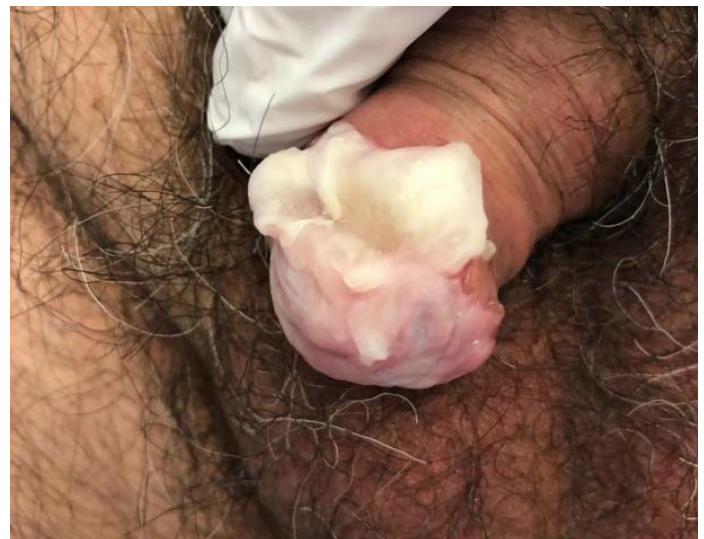## Introduction

Several premalignant and malignant conditions can affect the genitalia of elderly men, including erythroplasia of Queyrat, giant condyloma of Buschke and Löwenstein, verrucous carcinoma, and invasive squamous cell carcinoma. Pseudoepitheliomatous keratotic, and micaceous balanitis is a rare premalignant condition, with only a few cases reported in the world literature.

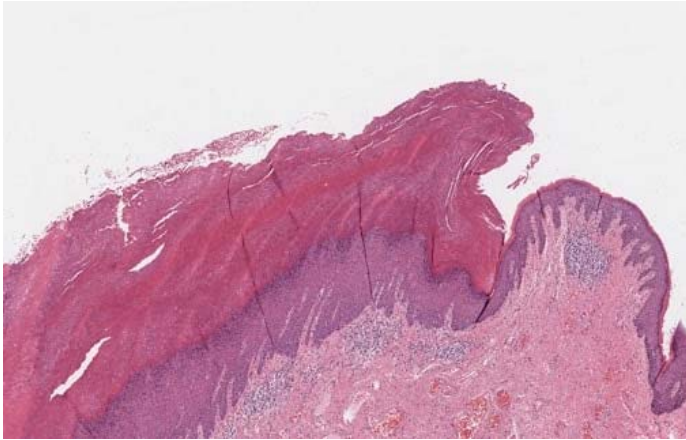
## Case Synopsis

A 77-year-old otherwise healthy man presented to our clinic complaining of a genital lesion that was slightly growing for about four years. Physical

examination revealed a hyperkeratotic, thick, whitish plaque over the glans (**Figure 1**), which was completely asymptomatic. The patient was uncircumcised. There was neither regional lymphadenopathy nor dysuria. Routine laboratory tests, including blood count, liver and renal function tests, erythrocyte sedimentation rate, and C-reactive protein levels were within normal limits. The patient's serologies were negative for HIV and hepatitis B and C viruses. Two penile biopsies had already been taken from the lesion some years earlier, with histological diagnosis of lichen sclerosus et atrophicus. The patient had previously been treated with topical corticosteroids, emollients, and calcineurin inhibitors without any improvements.

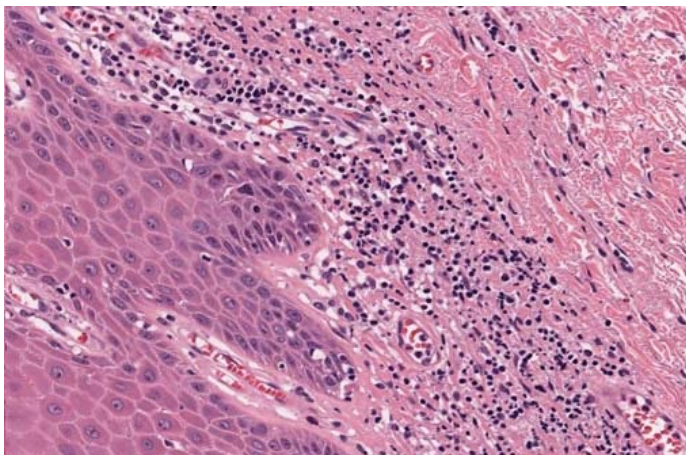


**Figure 1.** Clinical image of a whitish, thick, and hyperkeratotic plaque over the glans.



**Figure 2.** Histopathological image demonstrating hyperkeratosis and pseudoepitheliomatous hyperplasia of the epithelium of mucosa. H&E, 2x.

The persistence and growth of the plaque made us suspect malignancy. Therefore we decided to perform a complete surgical removal of the plaque. Histopathological examination showed erosions and atrophy of the epithelium of mucosa, alternating with areas of marked hyperkeratosis and pseudoepitheliomatous hyperplasia (**Figure 2**). Chronic inflammatory changes were noted on the subepithelial connective tissue (**Figure 3**). There was no cytological atypia and no mitotic figures or architectural disarray of keratinocytes. Based on the clinical and histopathological findings, the diagnosis of pseudoepitheliomatous, keratotic, and micaceous balanitis (PKMB) was made. The penile lesion healed completely after surgery and there was no recurrence after one year of follow up.



**Figure 3.** Histopathological image demonstrating chronic inflammation in the subepithelial connective tissue. H&E, 40x.

## Case Discussion

Pseudoepitheliomatous, keratotic, and micaceous balanitis is a rare, acquired penile disorder described by Lortat-Jacob and Civatte in 1961. It is characterized by a thick hyperkeratotic plaque, usually affecting the glans, covered by adherent, whitish, "micaceous" keratotic material (resembling mica, the white, scaly and crumbling silicate of aluminum). It is generally asymptomatic, but some patients report symptoms like irritation, itching, burning sensation, fissuring, or maceration. There is no inguinal lymphadenopathy. It can present with phimosis; rarely the plaque can involve the urethral meatus leading to urinary obstruction. In some cases, the hyperkeratosis is so thick that the plaque resembles a horn.

The etiology of PKMB is still unknown. Considered benign in the past, it is now regarded as a premalignant condition or a locally invasive low-grade malignancy, associated with the development of a verrucous carcinoma [1-3]. More rarely, invasive squamous cell carcinoma develops [4]. It has been suggested that PMKB is a pseudoepitheliomatous response to chronic inflammation [5]. Some authors think that PMKB is a complication of chronic, untreated or burnt-out lichen sclerosus et atrophicus [6]. Pseudoepitheliomatous, keratotic, and micaceous balanitis in fact can resemble both clinically and histologically genital hypertrophic lichen sclerosus et atrophicus [7]; both have a risk of malignant transformation. Our patient previously received a diagnosis of lichen sclerosus et atrophicus, suggesting a link between the two conditions.

There are four clinical stages of the disease: the initial plaque stage is followed by a tumor stage characterized by verrucous growth of the plaque. The third and fourth stages are characterized by malignant transformation into verrucous carcinoma and SCC with invasion, respectively.

The differential diagnosis includes lichen sclerosus et atrophicus, penile horns, verrucous or squamous cell carcinoma, keratoacanthoma, penile psoriasis, giant condyloma, squamous carcinoma arising from erythroplasia of Queyrat, and Bowen disease. The definitive diagnosis is essentially histopathological.

Treatment should be conservative when there is no histological evidence of malignancy [8]. Topical 5-fluorouracil is the most highly rated option for the initial plaque stage [9]. Surgical excision seems to be the best therapeutic option for the second stage, as in our case. Third and fourth stages may require more radical surgery, because the disease can recur locally. Other therapeutic options include cryotherapy, localized photodynamic therapy, subcutaneous interferon-alfa, shave biopsy plus electrocoagulation, and CO<sub>2</sub> laser therapy.

## References

1. Read SI, Abell E. Pseudoepitheliomatous, keratotic and micaceous balanitis. *Arch Dermatol*. 1981;117:435–7. [PMID: 7259225].
2. Jenkins D, Jr, Jakubovic HR. Pseudoepitheliomatous, keratotic, micaceous balanitis. A clinical lesion with two histologic subsets: Hyperplastic dystrophy and verrucous carcinoma. *J Am Acad Dermatol*. 1988;18:419–22. [PMID: 3343410].
3. Beljaards RC, van Dijk E, Hausman R. Is pseudoepitheliomatous, micaceous and keratotic balanitis synonymous with verrucous carcinoma? *Br J Dermatol*. 1987;117:641–6. [PMID: 3689682].
4. Subhadarshani S, Gupta V, Sarangi J, Agarwal S, Verma KK. Pseudoepitheliomatous, Keratotic, and Micaceous Balanitis. *Dermatol Pract Concept*. 2019;10:e2020012. [PMID: 31921499].
5. Murthy PS, Kanak K, Raveendra L, Reddy P. Pseudoepitheliomatous, keratotic, and micaceous balanitis. *Indian J Dermatol*. 2010;55:190–91. [PMID: 20606894].
6. Bunker CB, Francis N. Pseudoepitheliomatous keratotic and micaceous balanitis: comment. *Clin Exp Dermatol*. 2012;37:434–435. [PMID: 22092361].
7. Choo KJL, Ng SK, Sim CS, Cheng SWN. Pseudoepitheliomatous keratotic and micaceous balanitis treated with topical 5-fluorouracil and liquid nitrogen. *Clin Exp Dermatol*. 2017;42:424–426. [PMID: 28406530].
8. Kronic AL, Djerdj K, Starcevic-Bozovic A, et al. Pseudoepitheliomatous, keratotic, and micaceous balanitis. Case report and review of the literature. *Urol Int*. 1996;56:125–8. [PMID: 8659009].
9. Hanumaiah B, Mohan, Lingaiah NB, Kumaraswamy SK, Vijaya B. Pseudoepitheliomatous Keratotic and Micaceous Balanitis: A Rare Condition Successfully Treated with Topical 5-Fluorouracil. *Indian J Dermatol*. 2013;58:492. [PMID: 24249909].

## Conclusion

Pseudoepitheliomatous, keratotic, and micaceous balanitis is an unusual but potentially severe disease as it can sometimes progress to verrucous carcinoma and squamous cell carcinoma. We emphasize the importance of close follow-up of these patients.

## Potential conflicts of interest

The authors declare no conflicts of interest.