

UCSF

UC San Francisco Electronic Theses and Dissertations

Title

Evaluating Condylar Head Morphology as it relates to the Skeletal Vertical Facial Dimension:
A Three-Dimensional Semi-Automated Landmark Study

Permalink

<https://escholarship.org/uc/item/7bf5z4nk>

Author

Contro, Curtis Michael

Publication Date

2015

Peer reviewed|Thesis/dissertation

Evaluating Condylar Head Morphology as it relates to the Skeletal
Vertical Facial Dimension: A Three-Dimensional Semi-Automated
Landmark Study

by

Curtis Contro, DDS

THESIS

Submitted in partial satisfaction of the requirements for the degree of

MASTER OF SCIENCE

in

Oral and Craniofacial Sciences

in the

GRADUATE DIVISION

of the

UNIVERSITY OF CALIFORNIA, SAN FRANCISCO

DEDICATION

I would like to dedicate this master's thesis to my beautiful, caring wife Stephanie Contro. Were it not for your never-ending support and love, the last 7 years of education would have been far more arduous. I am so grateful to have you in my life now and forever.

ACKNOWLEDGEMENTS

I would like to thank Dr. Lissa Tallman and Dr. David Hatcher for their guidance and expertise through this project. I would also like to thank Yu-Yao Xu for her help with completing this project.

ABSTRACT

Introduction: Condylar growth direction and rotation affect the type of occlusion that forms, especially in the vertical dimension. It stands to reason that condylar morphology would be positively correlated with vertical facial dimension. The first objective of this study was to evaluate the reliability of novel three-dimensional semi-automated landmark computer software on mapping the head of the mandibular condyle. The second objective was to evaluate qualitatively how condylar morphology differs three-dimensionally according to skeletal vertical pattern and mandibular morphology in healthy adults who had had cone beam computed tomography scans (CBCT).

Methods: A convenience sample of 606 (423 females and 183 males) patient CBCT DICOM scans without identifiers was obtained from DDI Imaging Center in Sacramento. Due to inclusion and exclusion criteria, a total of 242 (169 females and 73 males) scans were eligible for the study. DICOM scans were loaded into the Anatomage InVivo software (Anatomage, San Jose, CA) to create lateral cephalograms. The lateral cephalograms were then loaded into Dolphin Imaging (Dolphin, Chatsworth, CA) and traced to determine MP-SN^o and chin angle (Id-Pg-MP^o). Subjects were selected at random from the 242 to create three groups of 10 subjects based on their MP-SN^o. Subjects who were more than one standard deviation below the norm were assigned to the brachyfacial group, while subjects who were more than one standard deviation above the norm were assigned to the

dolichofacial group. Those in between were assigned to the mesofacial group. Those 30 subjects were also divided by mandibular symphyseal morphology according to the chin angle (Id-Pg-MP°). Each subject's condyles were landmarked using Stratovan's Checkpoint software (Davis, CA). A Procrustes analysis was then used to generate an average condylar shape for each of the six groups from which to evaluate shape differences.

Results: Checkpoint proved to be a reliable method of placing landmarks on the condyle with a low coefficient of variation of 1.81% (SD/mean). The Bland-Altman indicated a mean difference of 0.344mm on average measurements of 55.232. Qualitative analysis of the Procrustes averages revealed morphological differences between the three skeletal vertical pattern groups. The brachyfacial average showed a moderate anterior lean from the sagittal, anterior convexity from the axial, and medial lean from the coronal views. The dolichofacial average showed a mild anterior lean from the sagittal, anterior concavity from the axial, and a symmetrical half-dome shape from the coronal. Counter to expectations, the obtuse chin angle group average displayed morphology similar to the brachyfacial average while the acute chin angle group average displayed morphology similar to the dolichofacial average.

Conclusions: Checkpoint is reliable software to landmark the TMJ. There are differences in average morphologies between all groups. Larger sample sizes and objective quantitative methods are needed for future research.

TABLE OF CONTENTS	PAGE
DEDICATION.....	iii
ACKNOWLEDGEMENTS.....	iv
ABSTRACT.....	v
INTRODUCTION.....	1
Background.....	1
Specific Aims.....	7
Hypothesis.....	7
METHODS.....	8
RESULTS.....	16
DISCUSSION.....	34
CONCLUSIONS.....	38
REFERENCES.....	39

INTRODUCTION

Orthodontics has traditionally borrowed much of its analysis of the human craniofacial complex from anthropometry. Much of the anatomical landmarks we use to describe a patient's lateral cephalogram were borrowed from anthropology (Graber *et al.*, 2011). Biological anthropologists strive to determine how humans differ in shape and morphology, while orthodontists work towards understanding how these craniofacial differences affect the treatment they prescribe to their patients. For example, orthodontists know to avoid extrusive treatments on long-faced individuals and conversely employ those very same extrusive mechanics on short-faced individuals. Since morphology plays an integral role in diagnosis and treatment, it is important to understand what makes the craniofacial complex of some individuals different from others.

With the advent and popularization of cone beam computed tomography (CBCT), orthodontists today are seeing clearer and more detailed images of the craniofacial complex in three dimensions than ever before (Dalili *et al.*, 2012). Prior to this technology, CT scans and two-dimensional radiography were used to image a mandibular condyle. Two-dimensional radiography is limited in its diagnostic value due to the inability to use it to make measurements in all three dimensions of space (Proffit, 2012). CT scans are costly and expose the patient to a higher than desired levels of radiation (Barghan *et al.*, 2012). Magnetic resonance imaging (MRI)

has also been used, and while there is no radiation exposure, the scan is time consuming and costly (Tsiklakis *et al.*, 2004). Cone beam computed tomography overcomes many of the shortcomings of these other imaging modalities. The information gained from a cone beam computed tomography is far more accurate and reliable when evaluating the TMJ and mandible (Hilgers *et al.*, 2005). Kau *et al.*, emphasized the important role that cone beam computed tomography is playing in orthodontics when he said, "CBCT has become a vital tool in evaluating multidisciplinary orthodontic cases that require surgical planning. It has shown major advancements over the two-dimensional imaging modalities when it comes to surgery simulation, analysis of condylar resorption and facial asymmetry evaluation" (Kau *et al.*, 2014). With the higher resolution images found today, condylar analysis using cone beam computed tomography offers much more information than previously could be seen from two-dimensional radiographs and is the method of choice when evaluating condylar morphology (Tsiklakis *et al.*, 2004).

There are several methods emerging with regards to analyzing three-dimensional data of mandibular condyles. Before widespread use of cone beam computed tomography, Kikuchi *et al.*, (2003) used tomograms and lateral cephalograms to examine the relationship between craniofacial morphology and condylar position and joint morphology. They found that the condyle was more likely to exhibit a posterior position in the glenoid fossa

when the mandible exhibited a clockwise rotation, suggesting that the vertical dimension of the craniofacial complex shares an intimate relationship with temporomandibular joint morphology. While this study did use three-dimensional data, it used slices to make its evaluation, essentially converting three-dimensional data into two-dimensional data. This conversion detracts from the value of the morphological data as it confines it into discrete planes of space. Cevitanes *et al.*, explored changes to the condyle after surgical manipulation of the maxilla and mandible by using three-dimensional color mapping and thereby maintaining their data in its raw form for analysis. They found this method allowed for clear identification of the location, magnitude, and direction of mandibular displacement as a result of the treatment (Cevitanes *et al.*, 2007). This method, however, gives a general idea of changes seen but fails to evaluate three-dimensional changes on a more descriptive scale. Schilling *et al.*, (2014) saw the value of maintaining three-dimensional data in its raw form for analysis when they explored the reliability of three-dimensional registration and superimposition methods for assessment of temporomandibular joint condylar morphology across subjects and longitudinally. They found landmark-based and voxel-based techniques to be reliable and useful to quantify subtle bony differences in the three-dimensional condylar morphology.

The mandibular condyle can be mapped in three-dimensions, and one such program that can do that is Checkpoint (Stratovan Corporation,

Sacramento, CA). This semi-automated three-dimensional analysis maps the head of the condyle to give an accurate three-dimensional representation. While placing landmarks in two-dimensional slices of three-dimensional data has been shown to be reliable (Ikeda *et al.*, 2014), it has not been shown to be reliable in three-dimensional surface data. It is the intention of this study to show that Checkpoint offers a predictable and reliable method for placing landmarks on three-dimensional surface data through the use of semi-automation.

While no two condyles may be exactly the same in shape and form, groups of them look similar. Being a main growth site for the mandible, which, in turn, can dictate the malocclusion that presents, it becomes highly important to establish norms for condylar shape. This variation in condylar shape is due to the fact that the mandibular condyle is a growth site for the mandible. Condylar growth is genetically determined in each patient. Direction of condylar growth has a direct impact on an individual's skeletal vertical pattern. Typically, people with a hypodivergent skeletal pattern have upward and forward growth of the condyle, while people with a hyperdivergent skeletal pattern have upward and backward growth of the condyle. It stands to reason that these types of growth patterns would lead to differences in shape development of the condyle (Figures 1 and 2).




Figure 1: Lower border of the mandible curvature consistent with (a) forward and (b) backward growth rotations, respectively taken from Skieller *et al.*, 1984.

Skieller, Bjork, and Linde-Hansen (1984) showed this to be the case in their study of measurements that, when taken together, gave an 86% prognostic estimate of mandibular growth rotation. They placed metallic implants on 21 pre-pubescent children to observe mandibular growth rotation. They found that the majority of the prognostic ability depended on the following four cephalometric values: mandibular plane angle, intermolar angle, mandibular lower border curvature, and the mandibular symphysis inclination (Figures 1 and 2).

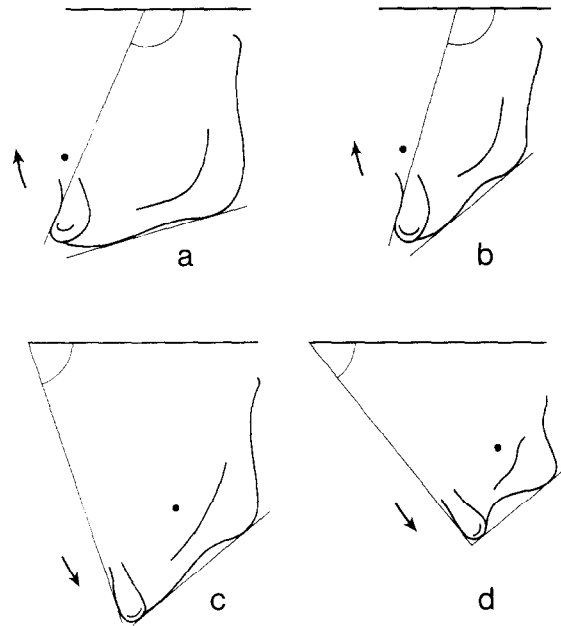


Figure 2: Forward leaning symphyseal inclinations (a & b) and backward leaning symphyseal inclinations (c & d) and the corresponding mandibular growth rotations taken from Skieller *et al.*, 1984.

Skieller *et al.*, (1984) found that a subject was more likely to exhibit a backward growth rotation of the mandible with a mandibular lower border that is straight and a symphysis characterized by proclination. Conversely, a subject was more likely to exhibit a forward growth rotation of the mandible when he or she exhibited a curved mandibular lower border and retroclination of the symphysis.

The purpose of this present study is to evaluate three-dimensional differences in mandibular condylar morphology based on skeletal vertical pattern as well as specific two-dimensional mandibular morphological

characteristics, using the Checkpoint landmark software. We hypothesize that condylar head morphology will vary based on skeletal vertical pattern (*i.e.*, mandibular plane angle), as well as mandibular morphology, as recognized by symphyseal inclination. The intent of the study is to show that long-faced and short-faced individuals will differ in condylar shape; specifically, long-faced and obtuse chin angle individuals will on average have a condylar head with more posterior lean while short-faced, and acute chin angle individuals will on average have a condylar head with more anterior lean.

The aims of this study are as follows:

1. To determine the reliability of the three-dimensional semi-automated landmark software, Checkpoint, within and between raters.
2. To determine qualitative three-dimensional differences in condylar morphology in healthy adults seeking cone beam computed tomography scans, based on skeletal vertical pattern
3. To determine differences in condylar morphology in healthy adults seeking cone beam computed tomography scans, based on two-dimensional mandibular symphyseal inclination

MATERIALS AND METHODS

Subjects:

An initial retrospective, convenience sample of 606 anonymous DICOM cone beam CT data was obtained from DDI Imaging Center in Sacramento, CA. All scans were taken using the i-CAT Cone Beam 3D Imaging System (Imaging Sciences International Inc., Hartfield, PA) with the subjects in an upright sitting position and with the patients' Frankfort horizontal plane parallel to the floor. The scanning settings for the CBCT machine were as follows: 120 kVP tube voltage, 18.45 to 47.74 mA tube current, and 20-second scan time. Of this sample, 423 were female and 183 were males, ranging in age from 18 years to 90 years old. The initial sample was organized by the imaging center by decades of age as well as gender. Other than that, no other demographic information was available on the subjects. Using the following inclusion and exclusion criteria, a sample of 242 subjects was compiled. This sample included 169 females and 73 males, which were considered eligible for the purpose of this study.

Inclusion Criteria:

Adult patients of 18 years of age or older

Scans that included the entire mandible as well as up to the cephalometric landmark nasion

Exclusion Criteria:

Radiographically visible condylar pathology past or present (*i.e.*, decortication, flattening, etc)

Radiographically visible mandibular asymmetry

Post-orthognathic surgery scans

Subjects with craniofacial anomalies (*i.e.*, cleft lip/palate, hemifacial microsomia, etc.)

Subjects lacking posterior vertical dental stops (affects vertical dimension of occlusion)

Scans taken with dental splints (affects vertical dimension of occlusion)

Anomalous condylar morphology (*i.e.*, heart-shaped condyle)

Poor scan resolution

Scans not taken in MIP

Apparent history of craniofacial trauma seen in CBCT

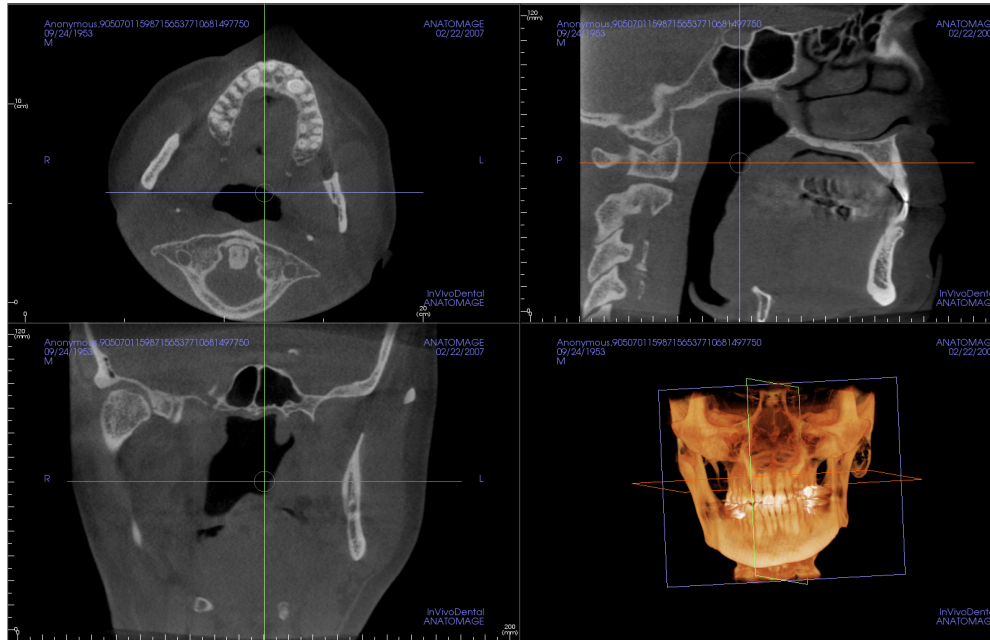


Figure 3: Sample individual excluded for obvious mandibular asymmetry and possible condylar hyperplasia

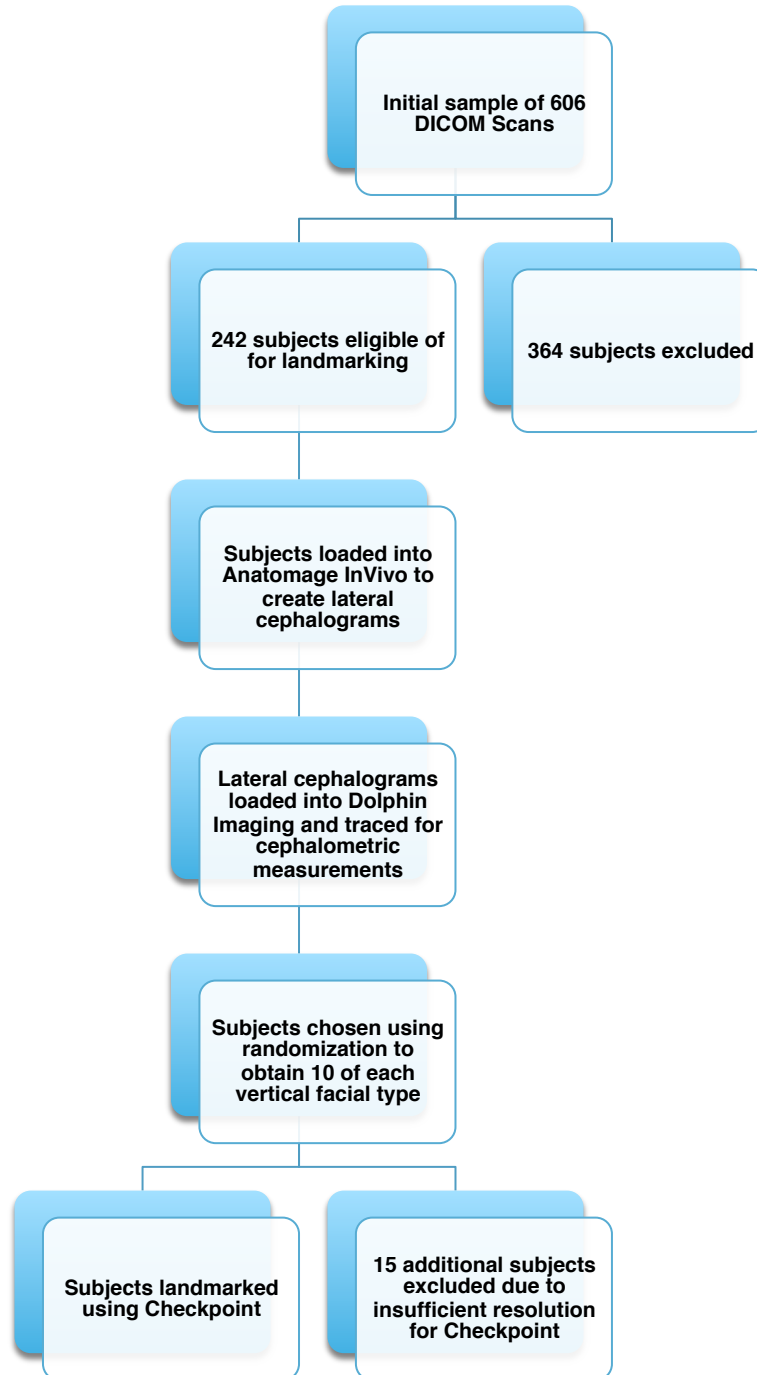


Figure 4: Flow of study up to the point of obtaining subjects to landmark

Cephalometrics:

Each of the 242 CBCT scans was loaded into the Anatomage InVivo software (Anatomage, San Jose, CA) to generate traditional lateral cephalograms from the three-dimensional data. This was done aligning the three-dimensional scan facing right with malar prominences and each sides of the mandible lined up to best fit. Next the lateral cephalograms were loaded into Dolphin Imaging (Dolphin, Chatsworth, CA) and digitally traced. The following measurements were obtained on each subject's skeletal vertical pattern: MP-SN^o, Ar-Go-Me^o, as well as the ratio between posterior face height (S-Go) and anterior face height (N-Me). The following angle, under the Bjork II analysis in Dolphin Imaging software, was used to classify mandibular symphysis morphology: Id-Pg-MP^o.

Semi-automated Three-dimensional Condylar Landmark Placement

The computer software Checkpoint (Stratovan Corporation, Davis, CA) was used to map the condylar head by two different investigators according to the methods seen in the recent study done by Ikeda (Ikeda *et al.*, 2014). Subjects were loaded, adjusted for proper contrast, and oriented into natural head position. Next the scans were cropped to include the entire condylar head and full surface of the glenoid fossa. The cropped volumes were then adjusted for proper contrast and oriented through the medial and lateral poles in the axial plane. Next the isosurface was adjusted for optimal

condylar head and fossa surface representation. Then the anchor points were placed on the medial and lateral poles as well as the posterior point described by Ikeda *et al.*, (2014). From these equator points, the program extrapolated 119 additional points according to a patch density of 11 x 11. Each semi-automated landmark was then manually adjusted for accuracy.

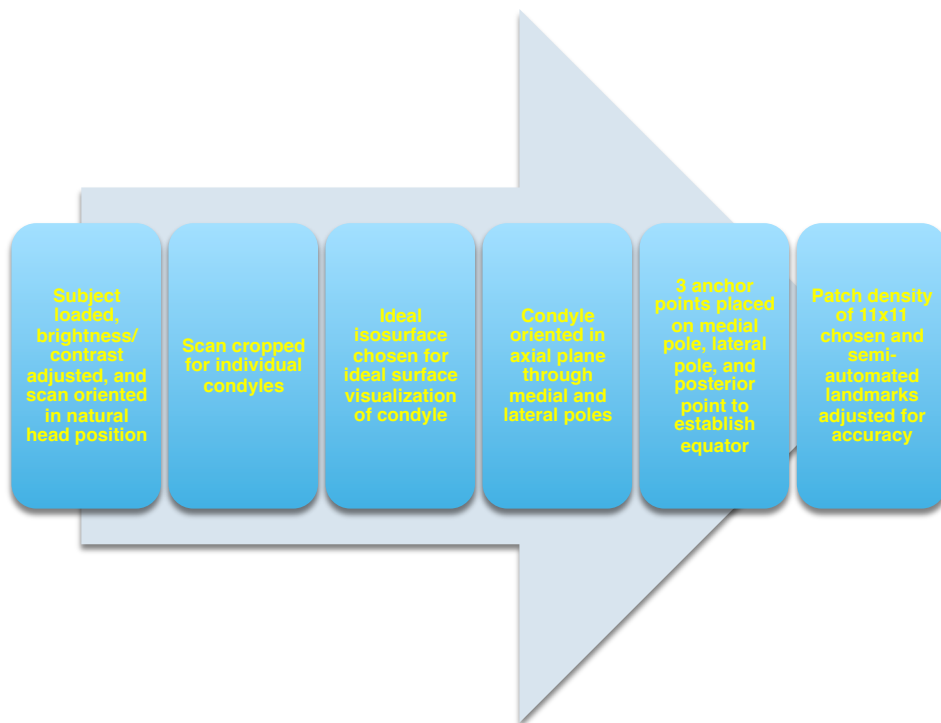


Figure 5: Process flow for Checkpoint software use

A random number generator was used to determine which patients would be landmarked. 10 dolichofacial subjects, 10 mesofacial subjects, and 10 brachyfacial subjects were obtained for landmark placement from the original sample of 242 subjects. 15 additional subjects were excluded from the study after their random selection due to incompatible scan resolution

with the landmark software. Of these 30 subjects, 27 were female and 3 were male. 14 of the 30 subjects were between the ages of 18 and 30 at the time of scan. 8 were between the ages of 31 and 40 at the time of scan. 5 were between the ages of 41 and 50 at the time of scan. One subject was between the age of 51 and 60 at the time of scan. Two subjects were between the ages of 51 and 60 at the time of scan. Inter/intra-rater reliability testing was performed using 5 subjects measured by two different investigators, at 2 different time points.

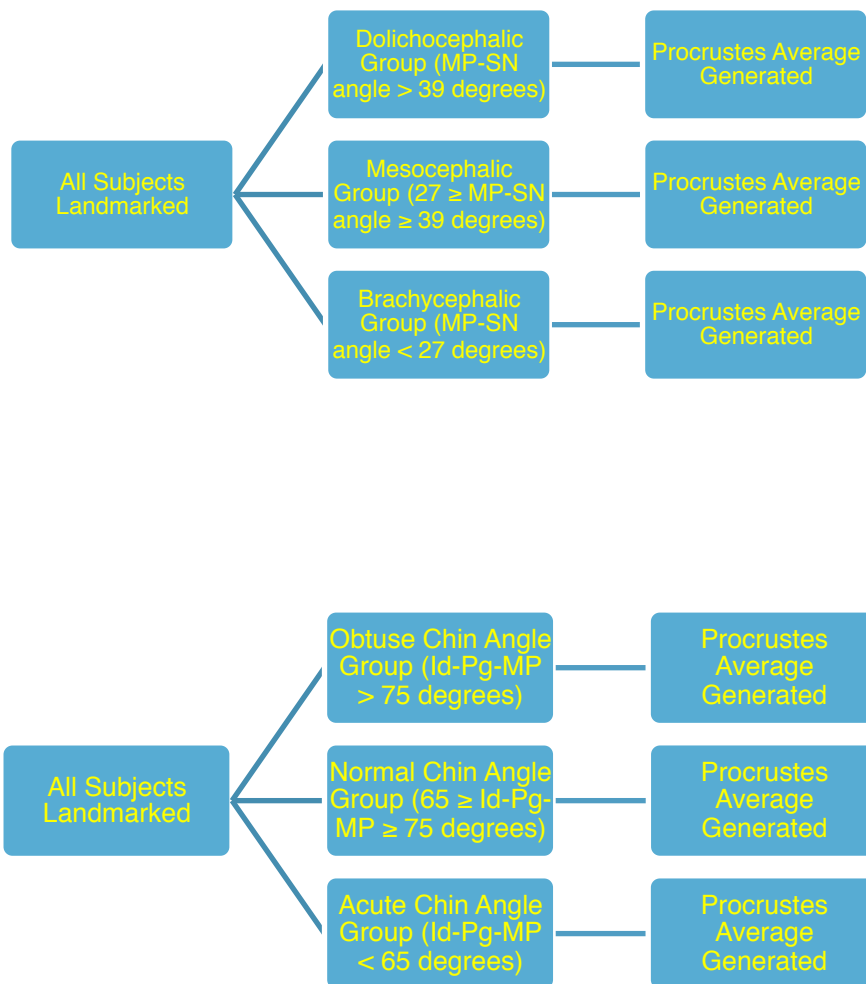


Figure 6: Breakdown of how different groups were created for Procrustes average morphologies.

A qualitative analysis was done by dividing the sample into 3 different groups, based on MP-SN°. The brachyfacial group was defined as any measurement that was more than one standard deviation below the norm. The dolichofacial group was defined as any subject that was more than one

standard deviation above the norm. The mesofacial group was defined as everything in between the previously mentioned groups. The same was done to create the chin angle groups based on the Id-Pg-MP°. The obtuse chin angle group was subjects with the chin angle more than one standard deviation above the norm. The acute chin angle group was created based on a chin angle that was more than one standard deviation below the norm. The normal chin angle group was all the subjects between those two groups. A Procrustes analysis was used to generate a mean condylar shape for each of the six groups. These six groups were then compared qualitatively for differences in morphology.

RESULTS

Reliability Testing

The interobserver reliability was compared between two judges over two timepoints and demonstrated a low coefficient of variation of 1.81% (SD/mean). The Bland-Altman indicated a mean difference of 0.344mm on

average

measurements

of

55.232.

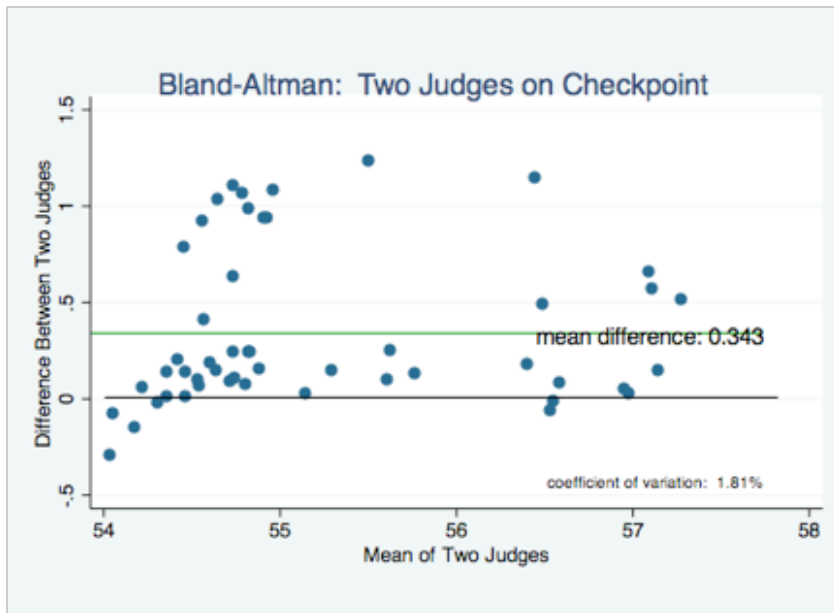


Figure 7: Bland-Altman of the two raters

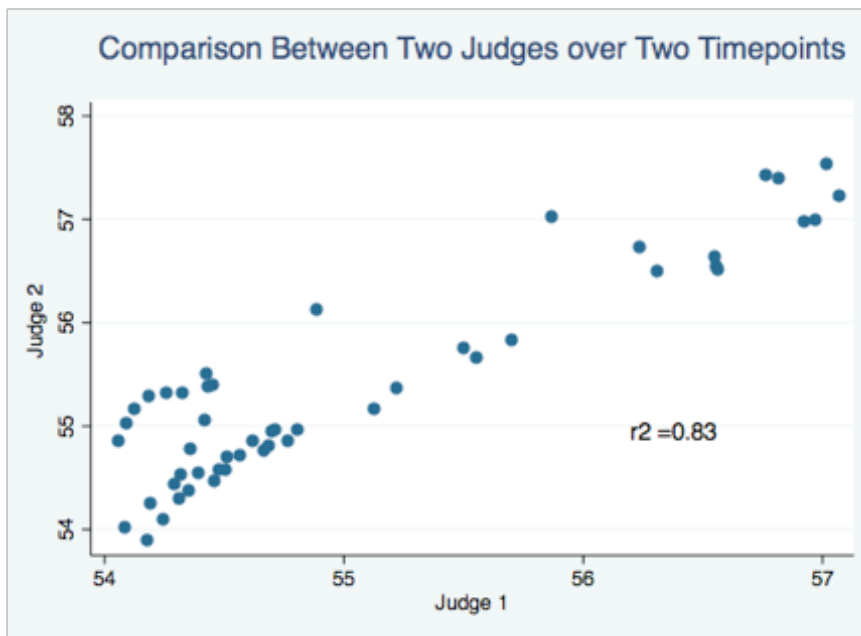


Figure 8: Correlation of the two raters

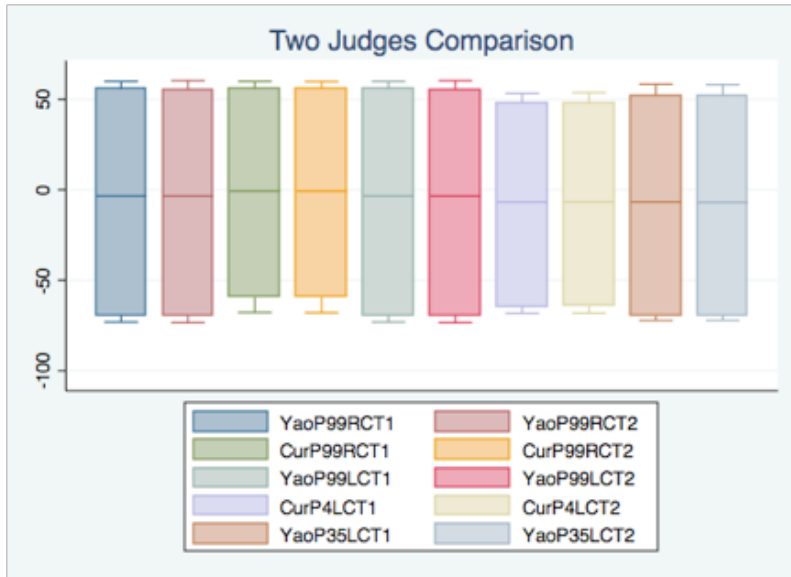


Figure 9: Medians and quartiles of 10 measurements across five subjects by two judges.

Sample Characteristics

The average mandibular plane angle for all 30 subjects was 32.3 degrees. For the dolichofacial subjects, the mean mandibular plane angle was 41.6 degrees. For the mesofacial subjects, the mean mandibular plane angle was 32.7 degrees. For the brachyfacial subjects, the mean mandibular plane angle was 22.8 degrees.

The mean gonial angle for all landmarked subjects was 120 degrees. The gonial angle varied for each of the groups with a mean angle of 125.2, 120, and 114.8 degrees for dolichofacial, mesofacial, and brachyfacial, respectively.

The mean posterior-anterior face height ratio for all landmarked subjects was 66.9. This ratio also varied based on subject group with a mean of 59.9, 66, and 74.7 for the dolichofacial, mesofacial, and brachyfacial groups respectively.

The cephalometric measurement that did not vary between the groups was the chin angle. The mean angle for all the subjects was 71.9 while it was 71.9, 72, and 71.8 degrees for the dolichofacial, mesofacial, and brachyfacial groups respectively.

Vertical Cephalometrics of All Subjects (n = 30)				
	Mandibular Plane Angle (MP-SN)	Gonial Angle (Ar-Go-Me)	P-A Face Height Ratio (S-Go/N-Me)	Chin Angle (Id-Pg-MP)
Mean	32.34	120.03	66.86	71.89
SD	8.32	7.48	6.78	7.99
Max	48.50	142.10	81.10	90
Min	15.50	107	56.70	58.90

Figure 9: Vertical cephalometrics for all subjects landmarked

Vertical Cephalometrics of Dolichofacial Group (n = 10)				
	Mandibular Plane Angle (MP-SN)	Gonial Angle (Ar-Go-Me)	P-A Face Height Ratio (S-Go/N-Me)	Chin Angle (Id-Pg-MP)
Mean	41.60	125.24	59.90	71.87
SD	2.96	7.25	2.26	9.88
Max	48.50	142.10	64	90
Min	39.10	114.70	56.70	58.90

Figure 10: Vertical cephalometrics for dolichofacial subjects

Vertical Cephalometrics of Mesofacial Group (n = 10)				
	Mandibular Plane Angle (MP-SN)	Gonial Angle (Ar-Go-Me)	P-A Face Height Ratio (S-Go/N-Me)	Chin Angle (Id-Pg-MP)
Mean	32.65	120.02	65.96	71.97
SD	1.97	5.91	2.67	6.88
Max	36.70	128.50	70	86.20
Min	30.50	113	61.80	62.50

Figure 11: Vertical cephalometrics for mesofacial subjects

Vertical Cephalometrics of Brachyfacial Group (n = 10)				
	Mandibular Plane Angle (MP-SN)	Gonial Angle (Ar-Go-Me)	P-A Face Height Ratio (S-Go/N-Me)	Chin Angle (Id-Pg-MP)
Mean	22.78	114.84	74.71	71.83
SD	3.67	5.71	3.55	7.80
Max	26.60	124.40	81.10	84.10
Min	15.50	107	71.20	60.60

Figure 12: Vertical cephalometrics for brachyfacial subjects

When subject groups were formed on the basis of chin angle, mean mandibular plane angles varied minimally at 34, 30.9, and 34.3 degrees for the acute chin angle, normal chin angle, and obtuse chin angle groups, respectively. The gonial angle showed a decreasing trend from 124.2, 119.2, and 117.2 degrees for the acute chin angle, normal chin angle, and obtuse chin angle groups respectively. Posterior-anterior face height ratio showed no such trend with the means being 65, 68.2, and 65.3 for the acute, normal, and obtuse chin angle groups respectively.

Vertical Cephalometrics of Acute Chin Angle Group (n = 6)				
	Mandibular Plane Angle (MP-SN)	Gonial Angle (Ar-Go-Me)	P-A Face Height Ratio (S-Go/N-Me)	Chin Angle (Id-Pg-MP)
Mean	34.03	124.18	64.92	60.47
SD	12.03	11.62	9.77	1.25
Max	48.50	142.10	81.10	62.50
Min	15.50	110.10	56.70	58.90

Figure 13: Vertical cephalometrics for acute chin angle subjects

Vertical Cephalometrics of Normal Chin Angle Group (n = 17)				
	Mandibular Plane Angle (MP-SN)	Gonial Angle (Ar-Go-Me)	P-A Face Height Ratio (S-Go/N-Me)	Chin Angle (Id-Pg-MP)
Mean	30.94	119.74	68.20	71.45
SD	7.43	6.58	6.06	2.72
Max	42.90	128.20	80.50	75
Min	17.70	107	59.80	65.60

Figure 14: Vertical cephalometrics for normal chin angle subjects

Vertical Cephalometrics of Obtuse Chin Angle Group (n = 7)				
	Mandibular Plane Angle (MP-SN)	Gonial Angle (Ar-Go-Me)	P-A Face Height Ratio (S-Go/N-Me)	Chin Angle (Id-Pg-MP)
Mean	34.30	117.19	65.26	82.74
SD	7.33	3.90	5.71	4.39
Max	44.50	123.10	72.20	90
Min	25.80	111.60	57.70	77.80

Figure 15: Vertical cephalometrics for obtuse chin angle subjects

Procrustes Averages of the Vertical Facial Groups

A generalized Procrustes analysis was performed on each subject group, and the Procrustes averages of each were compared qualitatively from various views for differences in shape and morphology. Differences between right and left condyles were minimal. Subtle differences can be seen between the three vertical facial pattern groups. From a frontal view of the condylar heads, the dolichofacial group average shows a more uniform and symmetrical half-dome appearance than the other two group averages. The mesofacial group average is squatter in height than the other two groups. The brachyfacial group displays a lean of the apex of the half-dome towards the medial (Figure 16).

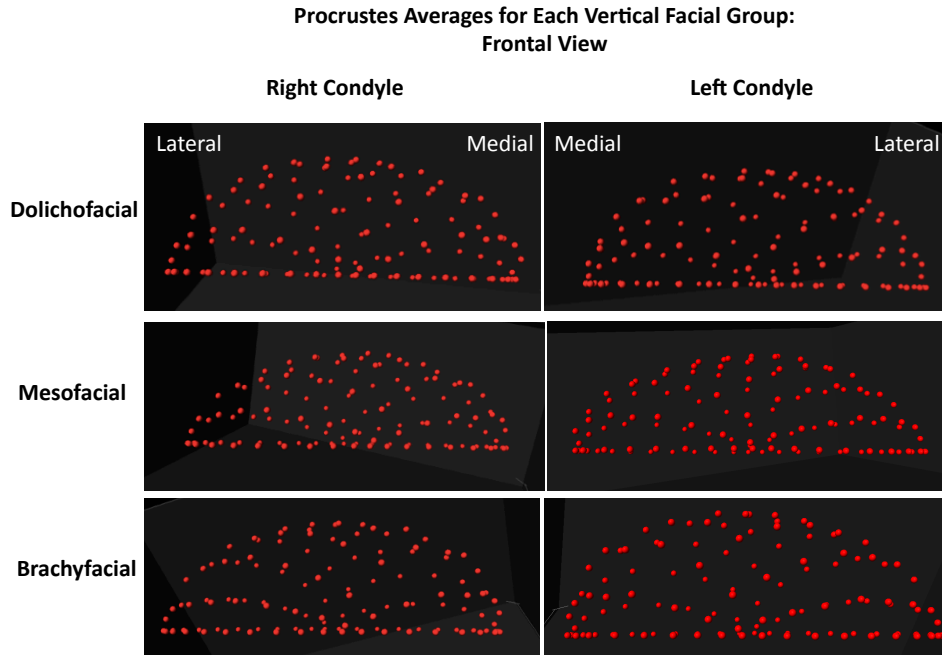


Figure 16: Comparison of skeletal vertical group Procrustes average morphologies, as seen from a frontal view of the condylar head

The lateral view also shows differences between the averages. All groups show a lean of the superior part of the condylar head towards the anterior. The mesofacial and brachyfacial groups display a more pronounced lean towards the anterior than the dolichofacial but no discernable difference from each other (Figure 17).

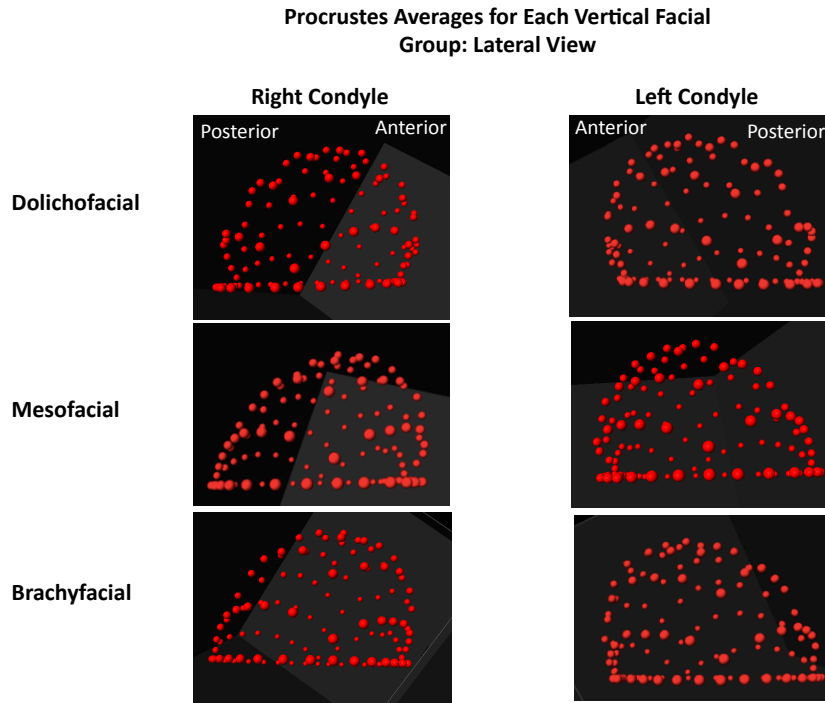


Figure 17: Comparison of skeletal vertical group Procrustes average morphologies, as seen from a lateral view of the condylar head.

Differences between the Procrustes averages were noted from the superior view as well, particularly on the anterior surface of the condylar head. The dolichofacial group showed a pronounced anterior concavity with anterior projections of the medial and lateral sides of the anterior surface. This concavity turns to a flat anterior surface as we look at the average shape of the mesofacial group. The brachyfacial group then shows a rounded, convex anterior surface with an overall oval shape, when viewed from the superior (Figure 18).

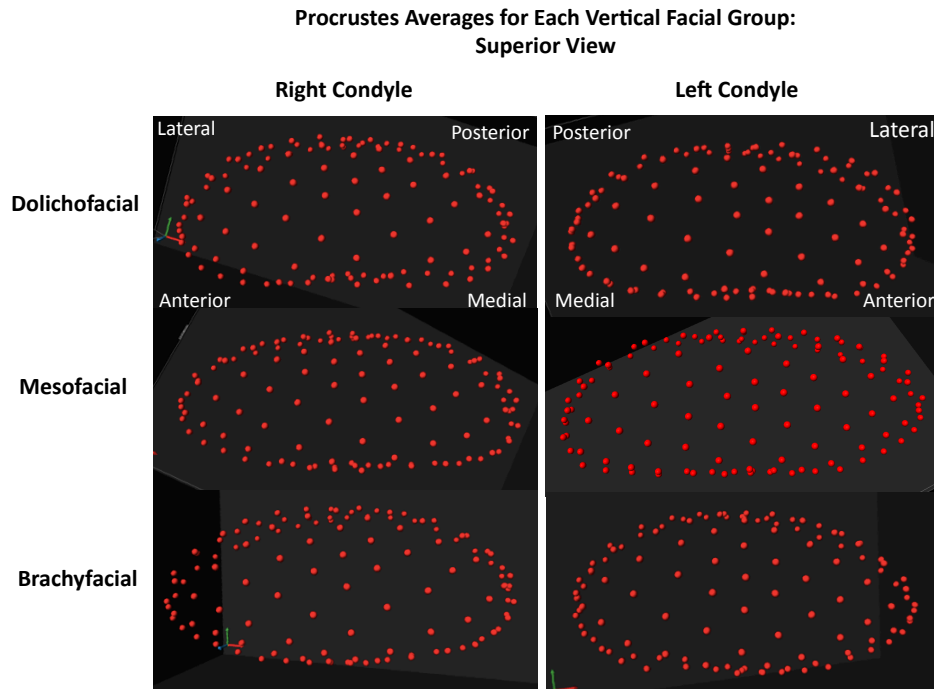


Figure 18: Comparison of skeletal vertical group Procrustes average morphologies, as seen from a superior view of the condylar head

Procrustes Averages of the Chin Angle Groups

From the frontal view the acute and obtuse chin angle group averages show no obvious shape differences between their averages but like the mesofacial group, the normal chin angle average is a mildly squatter half-dome than the acute and obtuse chin angle group averages (Figure 19).

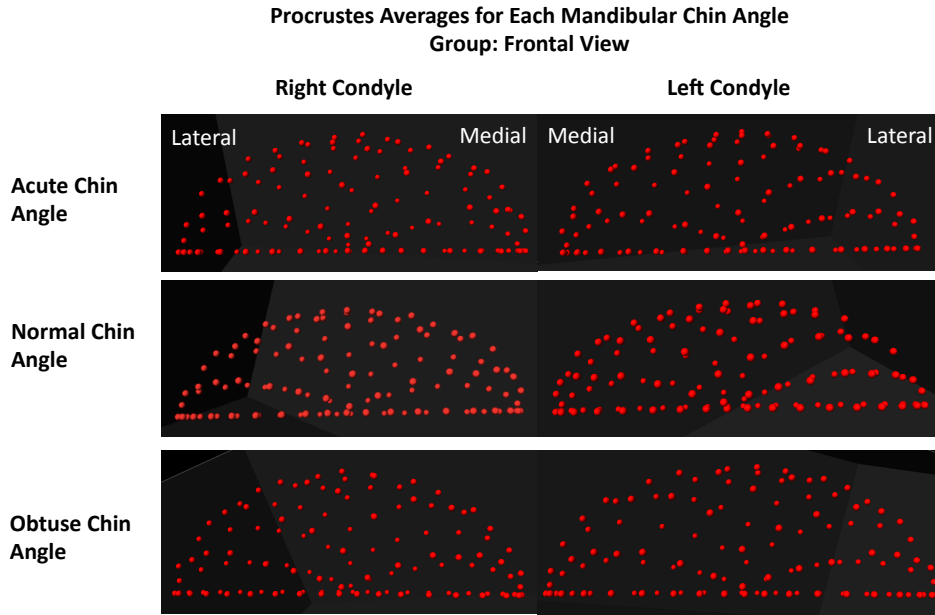


Figure 19: Comparison of chin angle group Procrustes average morphologies, as seen from a frontal view of the condylar head

From the lateral view, the normal chin angle group average is squatter in height as well. In addition, all 3 groups show an anterior lean of the apex of the half-dome of the condylar head with a more pronounced lean in the normal and obtuse chin angle group averages (Figure 20).

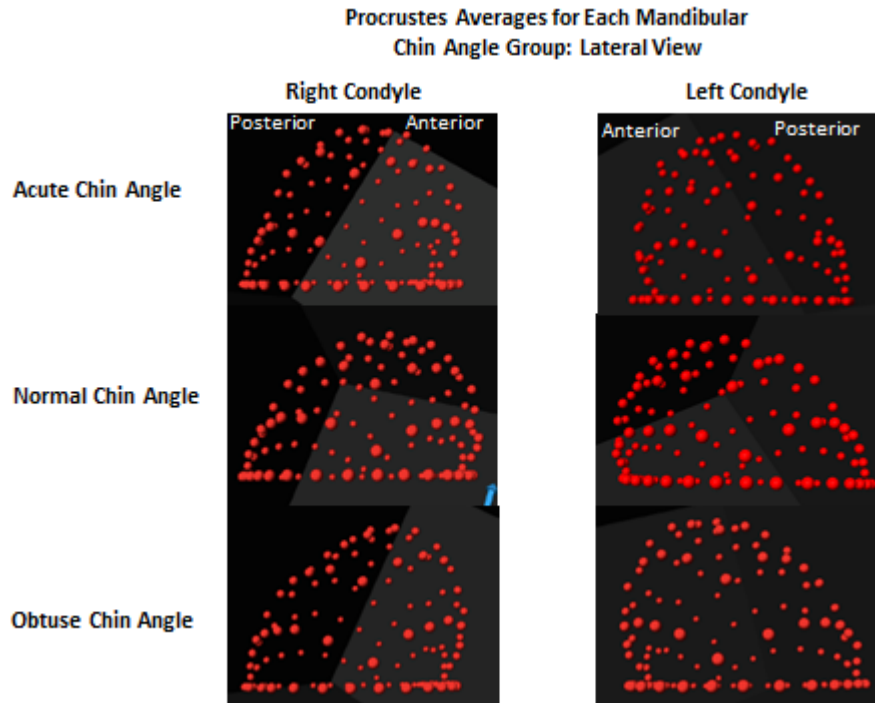


Figure 20: Comparison of chin angle group Procrustes average morphologies, as seen from a lateral view of the condylar head

From the superior view, the acute chin angle group average shows morphology similar to the dolichofacial group average with a slight anterior concavity and medial and lateral anterior projections. The normal chin angle group average displays similar morphology to the brachyfacial group average with a rounded anterior surface and overall oval shape. The obtuse chin angle average shows morphology similar to the mesofacial group average with a flat anterior surface (Figure 21).

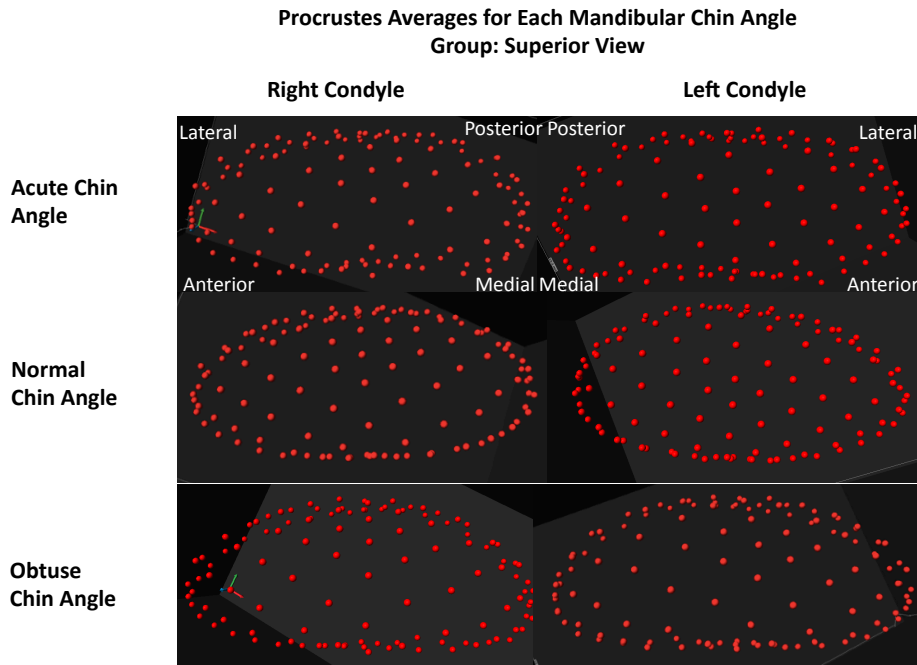


Figure 21: Comparison of chin angle group Procrustes average morphologies, as seen from a superior view of the condylar head

Variation Within Sample Groups

All six groups show much variation within the group with regards to the morphology of the condylar head. While the Procrustes average shape for the dolichofacial group shows an anterior concavity from the superior view, the group contained individuals with no such concavity, as well as individuals with a more pronounced concavity than the average (Figure 22). The mesofacial group shows similar variation with individuals showing a pronounced anterior concavity as well as an individual with an anterior convexity. One individual even shows a posterior lean of the apex when viewed from the lateral, differing greatly from the average (Figure 23). The

brachyfacial group also has individual variations in morphology, with subjects displaying anterior concavity as well as anterior convexity (Figure 24).

Variation of Right Condyle of Subjects in Dolichofacial Group




Figure 22: Lateral and inferior views of landmarks of the right condyle of two different subjects both within the dolichofacial group. Top row shows first subject and bottom row shows second subject. Selected subject in yellow, Procrustes average for group in red, all other subjects in gray.

Variation of Right Condyle of Subjects in Mesofacial Group

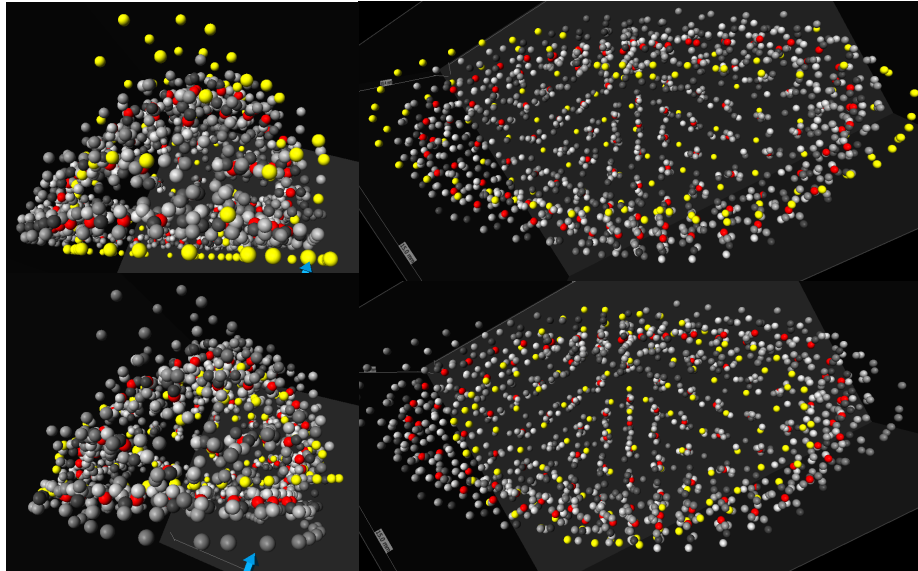


Figure 23: Lateral and inferior views of landmarks of the right condyle of two different subjects both within the mesofacial group. Top row shows first subject and bottom row shows second subject. Selected subject in yellow, Procrustes average for group in red, all other subjects in gray.

Variation of Right Condyle of Subjects in Brachyfacial Group




Figure 24: Lateral and inferior views of landmarks of the right condyle of two different subjects both within the brachyfacial group. Top row shows first subject and bottom row shows second subject. Selected subject in yellow, Procrustes average for group in red, all other subjects in gray.

In the acute chin angle group, all subjects displayed some degree of anterior concavity but notably varied in amount of anterior lean that could be seen on a lateral view (Figure 25). In the normal chin angle group, the amount of variation was dramatic with some subjects exhibiting a pronounced anterior concavity and some a pronounced anterior convexity. Similarly the amount of anterior or posterior lean variation was dramatically different as well.

(Figure 26). The obtuse chin angle group showed the same dramatic individual variation in the anterior surface (Figure 27).

Variation of Right Condyle of Subjects in Acute Chin Angle Group

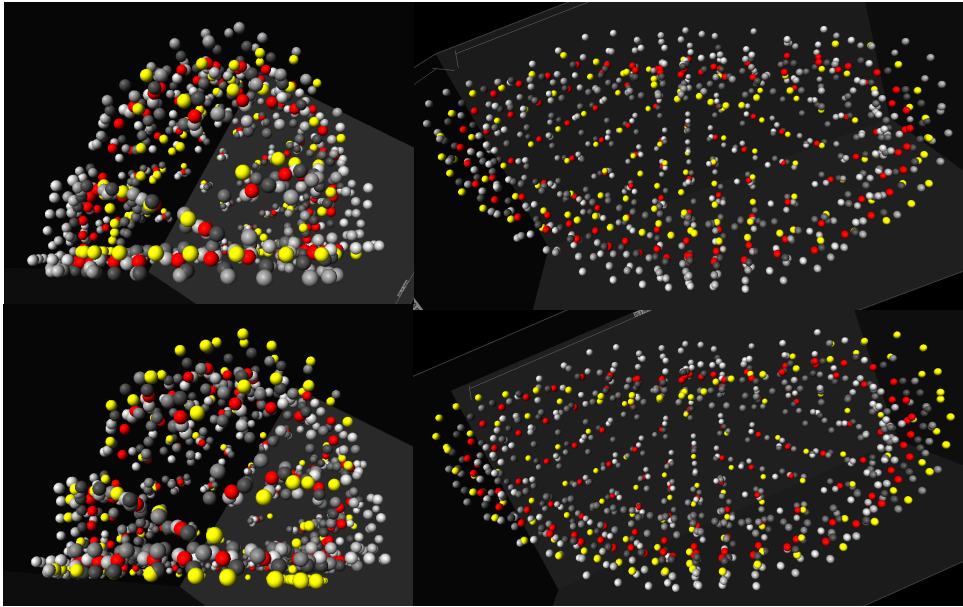


Figure 25: Lateral and inferior views of landmarks of the right condyle of two different subjects both within the acute chin angle group. Top row shows first subject and bottom row shows second subject. Selected subject in yellow, Procrustes average for group in red, all other subjects in gray.

Variation of Right Condyle of Subjects in Normal Chin Angle Group

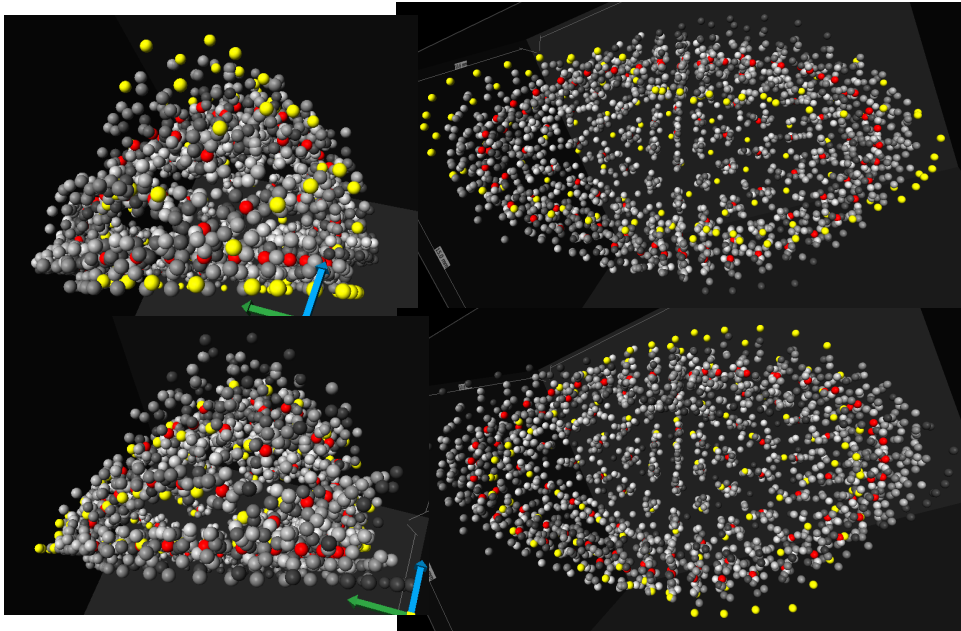


Figure 26: Lateral and inferior views of landmarks of the right condyle of two different subjects both within the normal chin angle group. Top row shows first subject and bottom row shows second subject. Selected subject in yellow, Procrustes average for group in red, all other subjects in gray.

Variation of Right Condyle of Subjects in Obtuse Chin Angle Group




Figure 27: Lateral and inferior views of landmarks of the right condyle of two different subjects both within the obtuse chin angle group. Top row shows first subject and bottom row shows second subject. Selected subject in yellow, Procrustes average for group in red, all other subjects in gray.

DISCUSSION

This multiple landmark method was found to be a reliable method of placing landmarks on the condylar head. The landmarks used by Ikeda *et al.*, (2014) served as reliable anchor points that could be used to produce a reproducible equator at the height of the medial and lateral poles from which semi-automated landmarks could be extrapolated. Despite manipulations

required for contrast and isosurface, the movement of the semi-landmarks to approximate the edge of condylar head cortication proved to be accurate within and between two different judges, and this study shows its reliability in three-dimensions.

Skeletal Vertical Groups

Bjork's implant studies on growth rotation would suggest that subjects exhibiting short-face characteristics, *i.e.*, low mandibular plane angle, low gonial angle, high posterior-anterior face height ratio, and low chin angle with a forward leaning mandibular symphysis, would display a condylar morphology reflecting that upward and forward growth. While it was anticipated that the brachyfacial group would have a pronounced anterior lean of the condylar head, it was not anticipated that the lean would be so subtle between groups. All skeletal vertical groups exhibited a lean with only mild differences discernable between them.

More interesting is the differences seen between the skeletal vertical groups when viewing the Procrustes averages from a superior view. The progressive change in morphology from one with an anterior concavity, as seen in the dolichofacial group, to one with an anterior convexity, as seen in the brachyfacial group, suggests that perhaps the anterior lean of the condylar head seen in traditional radiography of brachyfacial individuals is related to the lack of anterior growth at the lateral aspects of the condyle. It

is also possible that the converse is true for dolichofacial individuals – the lack of an anterior lean could be reflective of deficient anterior growth of the center of the anterior surface of the condyle. In a recent study by Park I-Y *et al.*, (2015), it was found the hyperdivergent condyles were round from a superior view while hypodivergent condyles were oval in shape. The findings of their hypodivergent condyles are consistent with the findings of this study, but the findings of the hyperdivergent condyles are not consistent.

As for the differences seen between the group averages from the frontal view, the squatter appearance of the mesofacial group average when compared to the other two group averages can perhaps be explained by the high degree of variation that was seen in the mesofacial group. This group had outlier morphologies, which would affect the Procrustes average shape.

Chin Angle Groups

The findings of the chin angle group averages were in many ways contrary to expectations. An acute chin angle, representing a forward leaning mandibular symphysis, is typically thought of as a brachyfacial characteristic. The Procrustes averages for this group, however, more closely resembled those of the dolichofacial Procrustes averages. Additionally an obtuse chin angle, representing a backward leaning mandibular symphysis, is typically thought of as a dolichofacial characteristic. The results are inconsistent with this, in that the Procrustes

averages for this group most closely resembled those of the brachyfacial Procrustes averages.

Limitations

This study has significant limitations that could have affected the results. The most significant limitation of this study is with the sample sizes of the six different groups. None of the samples were over 10 and one of the chin angle groups was as low as six. With larger sample sizes, Procrustes average shapes would likely be more distinct from one another and give the study more power. This would also help elucidate whether the amount of variation seen in each group is due to small sample size or true morphological variation among the different skeletal vertical patterns and symphyseal inclination. Future studies should add more subjects to each group from the initial sample of eligible subjects.

The second limitation is the lack of a quantifiable difference between groups. All assessments are qualitative observations which lack objectivity. Future studies should employ numerical methods to compare morphologies such as principle component analysis.

Lastly, the 606 subjects were acquired from an imaging center. Often patients are referred to this center for evaluation of the TMJ for possible pathology. Therefore, many of these subjects could have temporomandibular dysfunction symptoms in common. As TMD symptoms

are most commonly seen in women, I believe this also explains the smaller amount of men in the study than women. While pathology that was obvious on the radiographs was excluded from study eligibility, it is possible that this sample is not representative of the general population.

CONCLUSIONS

- By using the anchor points described by Ikeda *et al.*, (2014), Checkpoint has been shown to be reliable and predictable with good inter-rater and intra-rater correlation.
- Discernable differences in morphology can be seen between dolichofacial, mesofacial, and brachyfacial condylar head averages.
- When viewed from the lateral, only a subtle difference in amount of anterior lean of the condylar head could be discerned.
- When viewed from the superior, the anterior surface progresses from concave with dolichofacial individuals to convex with brachyfacial individuals.
- The chin angle groups showed morphologies inconsistent with study expectations: acute chin angle group averages most closely resembled dolichofacial group averages while obtuse chin angle group averages more closely resembled brachyfacial group averages.
- Further research is needed with larger sample sizes and quantifiable differences between morphologies.

REFERENCES

Barghan, S, Merrill, R, & Tetradis, S. (2012). Cone beam computed tomography imaging in the evaluation of the temporomandibular joint. *Texas Dental Journal*, 129(3), 289-302.

Bush K, Antonyshyn OM. 3-Dimensional facial anthropometry using a laser-surface scanner-validation of the technique. *Plastic and Reconstructive Surgery* 1996;98(2):226–235.

Cevidanes, L H, Bailey, L J, Tucker, S F, et al. (2007). Three-dimensional cone-beam computed tomography for assessment of mandibular changes after orthognathic surgery. *American Journal of Orthodontics and Dentofacial Orthopedics*, 131(1), 44-50.

Dalili Z, Khaki N, Kia SJ, Salamat F. Assessing joint space and condylar position in the people with normal function of temporomandibular joint with cone-beam computed tomography. *Dental Research Journal (Isfahan)* 2012;9:607-12.

Hayashi T, Ito J, Koyama J, Hinoki A, Kobayashi F, Torikai Y, et al. Detectability of anterior displacement of the articular disk in the temporomandibular joint on helical computed tomography: the value of open

mouth position. *Oral Surgery, Oral Medicine, Oral Pathology, Oral Radiology, and Endodontology* 1999;88:106-11.

Farkas L. *Anthropometry of the Head and Face*. New York: Raven Press; 1994.

Ackerman, James; Nguyen, Tung; Proffit, William: The decision-making process in orthodontics. In Graber, LW, Vanarsdall, R, Vig, KWL (Eds.): *Orthodontics: Current Principles and Techniques*. 5th Ed, 2011, Elsevier, St. Louis.

Hilgers, M L, Scarfe, W C, Scheetz, J P, et al. (2005). Accuracy of linear temporomandibular joint measurements with cone beam computed tomography and digital cephalometric radiography. *American Journal of Orthodontics and Dentofacial Orthopedics*, 128(6), 803-11.

Kau, C H, Li, J, Li, Q, et al. (2014). Update on cone beam technology and orthodontic analysis. *Dental Clinics of North America*, 58(3), 653-69.

Kikuchi, K, Takeuchi, S, Tanaka, E, et al. (2003). Association between condylar position, joint morphology and craniofacial morphology in

orthodontic patients without temporomandibular joint disorders. *Journal of Oral Rehabilitation*, 30(11), 1070-5.

Lieberman DE, Ross CF, Ravosa MJ. The primate cranial base: ontogeny, function, and integration. In: *Yearbook of Physical Anthropology*. Vol 43. Hoboken, NJ: Wiley-Liss; 2000.

Park I-Y, Kim J-H, Park Y-H. Three-dimensional cone-beam computed tomography based comparison of condylar position and morphology according to the vertical skeletal pattern. *Korean Journal of Orthodontics*. 2015;45(2):66-73. doi:10.4041/kjod.2015.45.2.66.

Proffit WR. *Contemporary Orthodontics*. 5th ed. St Louis: Mosby; 2013.

Schilling, J, Gomes, L C, Benavides, E, et al. (2014). Regional 3D superimposition to assess temporomandibular joint condylar morphology. *Dentomaxillofacial Radiology*, 43(1), 20130273-.

Skieller, V, Björk, A, & Linde Hansen, T. (1984). Prediction of mandibular growth rotation evaluated from a longitudinal implant sample. *American Journal of Orthodontics*, 86(5), 359-70.


Tsiklakis, K, Syriopoulos, K, & Stamatakis, H C. (2004). Radiographic examination of the temporomandibular joint using cone beam computed tomography. *Dentomaxillofacial Radiology*, 33(3), 196-201.

Publishing Agreement

It is the policy of the University to encourage the distribution of all theses, dissertations, and manuscripts. Copies of all UCSF theses, dissertations, and manuscripts will be routed to the library via the Graduate Division. The library will make all theses, dissertations, and manuscripts accessible to the public and will preserve these to the best of their abilities, in perpetuity.

Please sign the following statement:

I hereby grant permission to the Graduate Division of the University of California, San Francisco to release copies of my thesis, dissertation, or manuscript to the Campus Library to provide access and preservation, in whole or in part, in perpetuity.



Author Signature

6/12/15
Date