

UC San Diego

UC San Diego Previously Published Works

Title

Systematic review and quality analysis of emerging diagnostic measures for calcium pyrophosphate crystal deposition disease

Permalink

<https://escholarship.org/uc/item/7973x3fr>

Journal

RMD Open, 2(2)

ISSN

2056-5933

Authors

Wu, Y

Chen, K

Terkeltaub, R

Publication Date

2016-11-01

DOI

10.1136/rmdopen-2016-000339

Copyright Information

This work is made available under the terms of a Creative Commons Attribution-NonCommercial License, available at <https://creativecommons.org/licenses/by-nc/4.0/>

Peer reviewed

RMD
OpenRheumatic &
Musculoskeletal
Diseases

ORIGINAL ARTICLE

Systematic review and quality analysis of emerging diagnostic measures for calcium pyrophosphate crystal deposition disease

Y Wu,¹ K Chen,² R Terkeltaub¹

To cite: Wu Y, Chen K, Terkeltaub R. Systematic review and quality analysis of emerging diagnostic measures for calcium pyrophosphate crystal deposition disease. *RMD Open* 2016;**2**:e000339. doi:10.1136/rmdopen-2016-000339

► Prepublication history for this paper is available online. To view these files please visit the journal online (<http://dx.doi.org/10.1136/rmdopen-2016-000339>).

Received 18 July 2016
Revised 16 September 2016
Accepted 10 October 2016



CrossMark

¹Department of Rheumatology, VAMC/UCSD, San Diego, California, USA

²Department of Radiology, VAMC/UCSD, San Diego, California, USA

Correspondence to
Dr R Terkeltaub;
rterkeltaub@ucsd.edu

ABSTRACT

Objectives: Calcium pyrophosphate crystal deposition disease (CPPD) is common, yet prevalence and overall clinical impact remain unclear. Sensitivity and specificity of CPPD reference standards (conventional crystal analysis (CCA) and radiography (CR)) were meta-analysed by EULAR (published 2011). Since then, new diagnostic modalities are emerging. Hence, we updated 2009–2016 literature findings by systematic review and evidence grading, and assessed unmet needs.

Methods: We performed systematic search of full papers (PubMed, Scopus/EMBASE, Cochrane 2009–2016 databases). Search terms included CPPD, chondrocalcinosis, pseudogout, ultrasound, MRI, dual energy CT (DECT). Paper selection, data abstraction, EULAR evidence level, and Quality Assessment of Diagnostic Accuracy Studies (QUADAS)-2 bias and applicability grading were performed independently by 3 authors.

Results: We included 26 of 111 eligible papers, which showed emergence in CPPD diagnosis of ultrasound (U/S), and to lesser degree, DECT and Raman spectroscopy. U/S detected CPPD crystals in peripheral joints with sensitivity >80%, superior to CR. However, most study designs, though analytical, yielded low EULAR evidence level. DECT was marginally explored for CPPD, compared with 35 published DECT studies in gout. QUADAS-2 grading indicated strong applicability of U/S, DECT and Raman spectroscopy, but high study bias risk (in ~30% of papers) due to non-controlled designs, and non-randomised subject selection.

Conclusions: Though CCA and CR remain reference standards for CPPD diagnosis, U/S, DECT and Raman spectroscopy are emerging U/S sensitivity appears to be superior to CR. We identified major unmet needs, including for randomised, blinded, controlled studies of CPPD diagnostic performance and rigorous analyses of 4 T MRI and other emerging modalities.

INTRODUCTION

Calcium pyrophosphate dihydrate crystal deposition (CPPD) in the extracellular

Key messages

What is already known about this subject?

- The reference standards of calcium pyrophosphate crystal deposition disease (CPPD) diagnosis are conventional radiography for chondrocalcinosis, and synovial fluid compensated polarised light microscopy, but, in recent years, ultrasound has been established to have strong diagnostic performance for CPPD, and sensitivity higher than plain radiography.

What does this study add?

- Systematic search of full publications on CPPD diagnostic approaches, published since the drafting of EULAR CPPD diagnostic recommendations, point to the potential value for not only ultrasound, but also of DECT, the relatively unvalidated utility of emerging modalities such as Raman spectroscopy for crystal analysis (including an approach adapted for 'point of care' use).
- Quality and inherent risks of bias were highly variable in the studies reviewed, and the volume of CPPD diagnosis investigation is dwarfed by the number of studies of urate crystal detection in gout.
- Overall, there remains major, unmet need for randomised, blinded and controlled studies of CPPD diagnostic performance of advanced imaging and emerging crystal analytic modalities, in patient samples in 'real-world' clinical scenarios, with comparison to the reference standards.

How might this impact on clinical practice?

- New criteria that incorporate advanced imaging and emerging crystal analytic methods should advance clinical practice by improving recognition of CPPD, and thereby leading to more understanding in clinical practice of how CPPD can impact on phenotypes of joint pathology.

matrix of articular hyaline and fibrocartilages, and of certain articular and periarticular connective tissues is very common as an idiopathic disorder in ageing.¹ CPPD also can occur in association with osteoarthritis (OA), certain metabolic disorders (including hyperparathyroidism, haemochromatosis, hypomagnesaemia), and as a heritable disorder, whose common thread may be excessive cartilage extracellular inorganic pyrophosphate (PP_i).² Contributing factors to the disorder include PP_i generation and transport, imbalances in chondrocyte growth factors, and alterations in the connective tissue matrix.²

CPPD manifests substantially more often as joint pathology than it does as a symptomatic arthropathy. Recent epidemiological studies suggest growing CPPD prevalence in developed countries, not simply due to increased longevity of the population and particularly high prevalence of OA, but also potentially promoted by iatrogenic factors; these factors include hypomagnesaemia associated with loop and thiazide diuretics and proton pump inhibitors.¹ The original diagnostic criteria for CPPD were proposed by McCarty³ in 1994. European League Against Rheumatism (EULAR) recommendations for diagnosis in 2011 reinforced these criteria,⁴ including that the gold standard for diagnosis of CPPD crystal deposition disease, particularly for acute CPP crystal-associated inflammatory arthritis, is identification of CPPD crystals by compensated polarised light microscopic analysis of synovial fluid, in the absence of joint infection or other cause of arthritis. EULAR also seminally highlighted evidence on the utility of ultrasound (U/S) in CPPD diagnosis in 2011.⁴ As U/S and other CPPD diagnostic modalities are rapidly emerging since 2011, we systematically reviewed the literature on the diagnostic approach modalities, including the conventional standard of plain radiography. We examined new evidence on high-resolution U/S, dual-energy CT (DECT) and specialised crystal analytic approaches such as Raman spectroscopy. To bring focus onto the most recent developments in CPPD diagnosis, we used the 2011 EULAR systematic review as a starting point, and simply updated 2009–2016 literature findings not cited in 2011 by EULAR.⁴ We also performed evidence grading, and assessed unmet needs in the field.

METHODS

Literature search

We conducted a literature search of PUBMED (1 January 2009 to 30 April 2016), SCOPUS/EMBASE (1 January 2009 to 30 April 2016) and COCHRANE (1 January 2009 to 30 April 2016) databases. Our search strategies used a combination of controlled terms, subject headings and keywords to locate studies related to the themes of CPPD crystal deposition and diagnosis. The major search terms and concepts included (but were not limited to) *CPPD crystal deposition, pseudogout, chondrocalcinosis, diagnosis, diagnostic imaging, ultrasound, plain x-ray, computed tomography, dual-energy computed tomography, magnetic resonance*

imaging, crystal analysis and Raman spectroscopy. We identified additional articles through manual searches of the references in relevant papers.

Review of literature

After the initial searches were completed, YW reviewed all the resulting titles and abstracts. Citations were excluded if the title or abstract was not relevant to the goals of the review. Full manuscripts of the remaining citations were reviewed by YW and RT. Review articles were excluded; selected articles were manually searched to identify additional relevant reports.

Selection criteria

We reviewed titles and abstracts to identify published studies that met our systematic review inclusion criteria of: (1) diagnostic performance of ≥ 1 imaging or tissue/fluid sample crystal analytic modalities; (2) ≥ 1 group of patient±human specimens; (3) sensitivity or specificity measure (original or meta-analytic). We excluded: (1) non-English text; (2) non-original literature (eg, reviews without meta-analysis or comparable statistical analyses, editorials, opinions, letters, non-analytical); (3) case report; (4) not pertaining to diagnosis; (5) simple prevalence survey by conventional crystal analysis (CCA) or conventional radiography (CR); (6) use of synthetic crystals.

Data extraction and quality assessment

Two authors (YW and RT) independently reviewed the articles identified from the literature search. Then the following information was collected: index diagnostic modality, overall study design, modality compared with CCA or CR reference standard and EULAR level of evidence. Methodological quality was assessed by the Quality Assessment of Diagnostic Accuracy Studies (QUADAS)-2 tool.⁵ QUADAS-2 is the current version of QUADAS and the tool for use in systematic reviews to evaluate the risk of bias and applicability of primary diagnostic accuracy studies. When there were differences in QUADAS-2 scores, a third author (KC) reviewed the paper to settle discrepancies.

RESULTS

Study identification

A total of 111 articles were reviewed (figure 1). Among articles identified, 65 were excluded after review of the title and/or abstract, 19 were excluded after review of manuscript, and 1 duplicate was excluded. A total of 26 articles were included in the analysis, all of them are full length manuscripts (tables 1–3). Table 1 provides information on the diagnostic modalities and EULAR evidence levels. Two studies examined CR,^{6 7} 12 studies examined U/S,^{8–19} 1 study examined CT,²⁰ 1 study examined DECT,²¹ 3 studies examined CCA,^{22–24} 4 studies examined Raman spectroscopy,^{25–28} 1 study examined

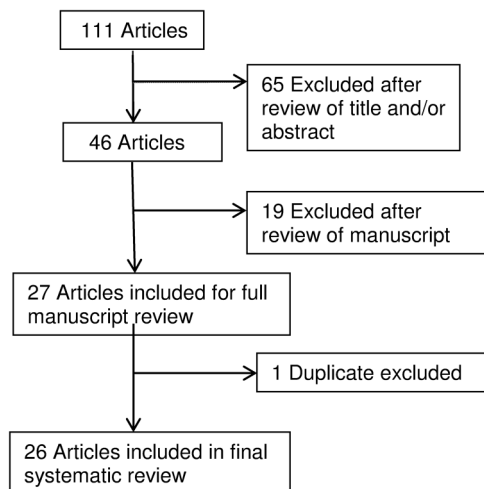


Figure 1 Systematic review study flow. A total of 111 articles were reviewed. Among articles identified, 65 were excluded after review of the title and/or abstract, 19 were excluded after review of manuscript, and 1 duplicate was excluded. A total of 26 articles were included in the analysis.

elemental bioanalysis²⁹ and 2 studies examined metabolic or other mass spectrometry.^{30 31}

Quality assessment

Overall, the included studies met most of the quality indicators of the QUADAS-2 tool (figure 2). The most common quality issues were non-randomised patient selection without case-control or appropriate exclusion, and index test results being interpreted without knowledge of the results of the reference standard.

Study design, modality and level of evidence

Study design, modality and level of evidence are shown in table 1. Most studies were case-control or cross-sectional studies with exceptions of three descriptive studies.^{13 16 31} Among the 26 diagnostic studies, all but 2^{29 30} used comparison to CCA or CR reference standard; the remaining 2 studies^{29 30} did not use any reference standard for comparison. Modalities examined, and numbers of studies for each are cited in table 1.

Table 1 Modalities and EULAR evidence levels

Index diagnostic modality:	Overall study design:	Modality compared with CA or CR Reference standard?	EULAR level of evidence*:
CR ^{6 7} : n=2	Analytical: case-control, n=3 Analytical: cross-sectional, n=20 Descriptive, n=3	Yes: n=24 No: n=2	I: n=0 II: n=23 III: n=3 IV: n=0
U/S ⁸⁻¹⁹ : n=12	Analytical: case-control, n=1 Analytical: cross-sectional, n=9 Descriptive: n=2	Yes: n=2 Yes: n=12	II: n=2 II: n=10 III: n=2
CT ²⁰ : n=1	Analytical: cross-sectional, n=1.	Yes: n=1	II: n=1
DECT ²¹ : n=1	Analytical: cross-sectional, n=1	Yes: n=1	II: n=1
CCA ²²⁻²⁴ : n=3	Analytical: case-control, n=1 Analytical: cross-sectional, n=2	Yes: n=3	II: n=3
Raman spectroscopy ²⁵⁻²⁸ : n=4	Analytical: case-control, n=1. Analytical: cross-sectional, n=3	Yes: n=4	II: n=4
Elemental bioanalysis ²⁹ : n=1	Analytical: cross-sectional, n=1	No: n=1	II: n=1
Metabolomic ³⁰ or other mass spectrometry ³¹ : n=2	Analytical: cross-sectional, n=1 Descriptive: n=1	Yes: n=1 No: n=1	II: n=1 III: n=1

II: Cohort or case-control studies; III: non-comparative, descriptive studies; IV: expert opinion.

*EULAR level of evidence: I: meta-analysis of cohort or case-control studies.

CCA, conventional crystal analysis; CR, conventional radiography; DECT, dual-energy CT; U/S, ultrasound.

Table 2 Imaging study (CR, U/S, DECT, CT, MRI) characteristics and features

Study	Modality	Diagnosis of CPPD	Publication date	Patients (N)	Features examined	Prevalence of pattern by site	Sensitivity	Specificity
Abhishek <i>et al</i> ⁶	CR	X-rays	7/2013	435	CC at knee, hip, wrist, symphysis pubis, and MCP	Knee 8%, hip 5%, wrist 6.9%, symphysis pubis 3.6%, MCP 1.5%	ND	ND
Abhishek <i>et al</i> ⁷	CR	X-rays	10/2012	428	CC at hip, wrist, symphysis pubis, and MCP without knee CC	Hip 45.9%, wrist 44.4%, symphysis pubis 45.5%, MCP 31.3%	ND	ND
Barskova <i>et al</i> ⁸	U/S	McCarty criteria	6/2013	25	Linear hyperechoic deposits in hyaline cartilage	Knee: U/S 100% CT 72% CR 52%	ND	ND
Filippou <i>et al</i> ⁹	U/S	McCarty criteria	11/2013	42	Hyperechogenic bands and spots in hyaline cartilage and fibrocartilage; linear deposits along the tendon	Knee 97.6%, wrist 88%, Achilles tendon 54.8%, plantar fascia 26.1%, MCP 9.5%	ND	ND
Filippucci <i>et al</i> ¹⁰	U/S	CPPD crystal analysis	9/2013	88	Hyperechoic spots within the fibrocartilage and hyaline cartilage of the humeral head	Fibrocartilage 42.4%, hyaline cartilage 16.3%	ND	ND
Filippucci <i>et al</i> ¹¹	U/S	McCarty criteria	2/2009	48	Intracartilaginous hyperechoic spots	ND	Knee 68.7%	Knee 97.6%
Filippucci <i>et al</i> ¹²	U/S	McCarty criteria	1/2010	70	Intracartilaginous hyperechoic spots	Knee 64.2%	ND	ND
Gutierrez <i>et al</i> ¹³	U/S	CPPD crystal analysis	12/2010	2	Calcification within femoral hyaline cartilage, hyperechoic spots in wrist	ND	ND	ND
Lamers-Karnebeek <i>et al</i> ¹⁴	U/S	CPPD crystal analysis	4/2014	54	Hyperechoic band within the cartilage	0	ND	ND
Loffler <i>et al</i> ¹⁵	U/S	CPPD crystal analysis	3/2015	225	Hyperechoic spots within the cartilage	ND	78.9%	51.7%
Russell <i>et al</i> ¹⁶	U/S	CPPD crystal analysis	3/2013	4	Hyperechoic foci within the cartilage	ND	ND	ND
Ruta <i>et al</i> ¹⁷	U/S	McCarty criteria	4/2016	75	Hyperechoic bands within the femoral hyaline cartilage and hyperechoic spots in meniscal fibrocartilage	ND	60%	96.7%
Zufferey <i>et al</i> ¹⁸	U/S	CPPD crystal analysis	7/2015	109	Intracartilaginous, meniscus, synovial or tendon hyperechoic deposits	ND	60%	80%
Ottaviani <i>et al</i> ¹⁹	U/S	CPPD crystal analysis	8/2015	51	Hyperechoic spots in knee cartilage	ND	100%	92.3%
Kobayashi <i>et al</i> ²⁰	CT	CPPD crystal analysis	9/2014	27	Calcification of the transverse ligament and longus colli muscle	Neck: transverse ligament 81.5%, longus colli 7.4%	ND	ND
Misra <i>et al</i> ²¹	DECT	X-rays	2/2015	16	Intra-articular calcium crystal in meniscal and hyaline cartilage and deeper structures cruciate ligaments and joint capsules	Meniscus 66.6–95.8%, hyaline cartilage 8.3–91.6%, cruciate ligament 0–79.1%, joint capsule 58.3–62.5%	ND	ND

CC, chondrocalcinosis; CPPD, calcium pyrophosphate crystal deposition disease; CR, conventional radiography; DECT, dual-energy CT; MCP, metacarpophalangeal joint; ND, not defined; U/S, ultrasound.

Table 3 Crystal analytic study (CCA, Raman spectroscopy, elemental bioanalysis, metabolomic, mass spectrometry) characteristics and features

Study	Modality	Diagnosis of CPPD	Publication date	Patients (N)	Features examined	Prevalence of pattern by site	Sensitivity	Specificity
Pollet <i>et al</i> ²²	CCA	CPPD crystal analysis	5/2015	180	Synovial fluid crystal analysis	ND	66.7%	93.2%
Robier <i>et al</i> ²³	CCA	CPPD crystal analysis	6/2014	50	Synovial CCP crystal count with cytopsin and smear	Cytospin 96/10HPF, smear 2.5/10HPF	ND	ND
Tausche <i>et al</i> ²⁴	CCA	CPPD crystal analysis	8/2013	75	CCP crystals/field day 0 and stored for 1–3 days	>5/field 33.3%, <5/field 66.6%	ND	ND
Cheng <i>et al</i> ²⁵	Raman spectroscopy	CPPD crystal analysis	4/2009	35	CCP crystal analysis with Raman and PLM	Agreement 91.4%, discrepancy 8.5%, confirmation 100% correct with Raman, 33.3% correct with PLM	ND	ND
Li <i>et al</i> ²⁶	Raman spectroscopy	CPPD crystal analysis	2/2014	ND	CPPD crystals concentrations detected by CARD and PLM	CARD 1 ug/mL, PLM 10–100 ug/mL	ND	ND
Fuerst <i>et al</i> ²⁷	Raman spectroscopy	CPPD crystal analysis	3/2010	4	CPPD crystal analysis by Raman spectra	CPPD 25%, HA 75%	ND	ND
Li <i>et al</i> ²⁸	Raman spectroscopy	CPPD crystal analysis	2/2016	174	Rapid POCR compared with CPLM for CPPD and gout diagnoses	Overall 89.7% POCR and CPLM agreement; κ coefficient for POCR and CPLM: 0.61 (95% CI 0.42 to 0.81) in CPPD; 0.84 (CI 0.75 to 0.94) in gout	ND	ND
Nguyen <i>et al</i> ²⁹	Elemental bioanalysis	CPPD crystal analysis	2013	20 (141 cartilage samples)	CaC crystals and CPP crystals in patients with OA by FT-IR	CaC crystals 68.3%, CPP crystals 14.1%	ND	ND
Hugle <i>et al</i> ³⁰	Metabolomic	CPPD crystal analysis	3/2012	59	Metabolomic profiling of knee synovial fluid with NMR	35 different metabolites identified, no difference compared with OA	ND	ND
Austin <i>et al</i> ³¹	Mass spectrometry	CPPD crystal analysis	3/2009	ND	CPP crystal identification with LA ICP-MS	High calcium, phosphorus, magnesium, strontium intensities in cartilage and synthetic synovial fluid	ND	ND

CaC, calcium-containing; CARD, cost-efficient automated Raman device; CCA, conventional crystal analysis; CCP, cyclic citrullinated peptide; CPLM, compensated polarised light microscopy; CPPD, calcium pyrophosphate crystal deposition disease; FT-IR, Fourier-transform infrared spectroscopy; HA, hydroxyapatite; LA ICP-MS, laser ablation inductively coupled plasma mass spectrometry; ND, not defined; NMR, nuclear MR; OA, osteoarthritis; PLM, polarised light microscopy; POCR, point of care Raman.

Most studies (23 of 26)^{6–12 14 15 17–30} yielded EULAR evidence level of II, and 3^{13 16 31} of 26 studies provided lower EULAR evidence of III.

Study characteristics and features

Detailed study characteristics and features are shown in tables 2 and 3. We included only studies (from 1 January 2009 to 30 April 2016) after the EULAR recommendations for calcium pyrophosphate deposition terminology and diagnosis. Among all 26 studies, 12 (7 U/S, 2 CCA, 3 Raman spectroscopy)^{10–12 14–16 18 22 24–26 28} included patients with CPPD and gout, 7 (5 U/S, 1 CT, 1 CCA)^{8 9 13 17 19 20 23} studied patients with CPPD only and 6 (2 CR, 1 DECT, 1 Raman spectroscopy, 1 elemental bioanalysis, 1 mass spectrometry)^{6 7 21 27 29 31} included patients with CPPD and significant coexisting OA. The articular or periarticular sites studied were mostly knees,^{6–9 11–19 21–23 29–31} as well as wrists,^{6 7 9 13 22} ankles,^{14 15 18 22} hips,^{6 7 22 31} metacarpophalangeal joints (MCPs),^{6 7 9 16} shoulders,^{10 22 23} metatarsophalangeal joints (MTPs),^{14 18 22} symphysis pubis,^{6 7} elbows,^{16 22} neck²⁰ and Achilles tendon/plantar fascia.⁹ The age of patients ranged from 18²⁸ to 98²² years, and the proportion of males ranged from 22.9%¹¹ to 70.4%.¹⁴ The mean disease duration was described in three studies^{8 10 12} and ranged from 5.6 to 6 years.

As previously described, the U/S patterns evaluated were linear hyperechoic deposits or bands in the hyaline cartilage,^{8 9 14 17} hyperechoic spots in fibrous cartilage

or in tendons.^{9–13 15–19} The sensitivity of U/S studies ranged from 60%^{17 18} to 100%¹⁹ and specificity from 51.7%¹⁵ to 97.6%.¹¹ One study of CCA claimed sensitivity of 66.7%²² and specificity of 93.2%.²² Meta-analysis, in one systematic review study, concluded sensitivity and specificity for U/S in CPPD of 87.9%³² and 91.5%,³² respectively.

Diagnosis of CPPD relies on identification of CPPD crystals by compensated polarised light microscope (CPLM) in synovial fluid aspirates, enhanced by birefringent properties of CPPD. However, the relatively small field of view limits the efficiency and accuracy of CPPD diagnosis by CPLM. Raman spectroscopy is a chemical analysis technique that is 100% specific in fingerprinting species based on the identification of chemical bonds unique to each material.²⁸ We reviewed four major studies^{25–28} comparing Raman spectroscopy and CPLM. It was found that point of care Raman (POCR) spectroscopy can detect monosodium urate and CPPD crystals with good sensitivity and specificity at concentrations as low as 5 and 2.5 µg/mL,²⁵ and 0.1 and 1 µg/mL.²⁶ The detection limit of Raman spectroscopy is lower than that reported for CCA. Further study using a larger clinical sample set revealed that CPLM and POCR analyses agreed in 89.7% of samples (156 of 174), κ coefficients indicated that POCR and CPLM had excellent agreement in diagnosing gout (0.84 with 95% CI 0.75 to 0.94), and good, but less broad agreement in diagnosing acute CPP crystal arthritis (pseudogout; 0.61 with 95% CI 0.42 to 0.81).²⁸ The results suggested that POCR can be used in settings where there are

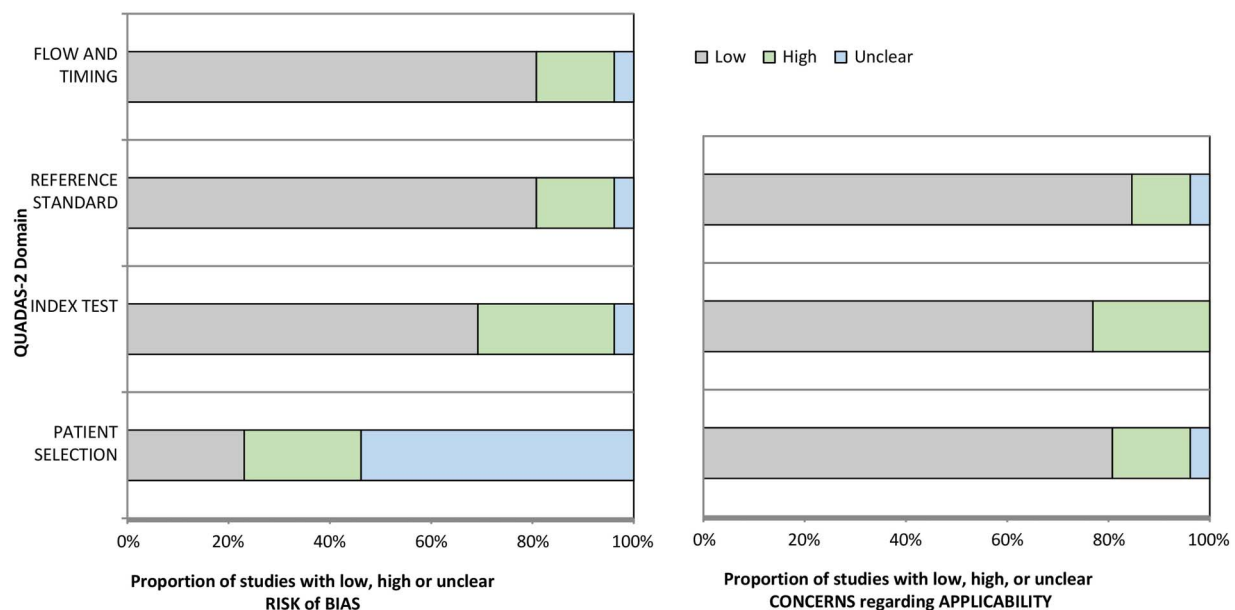


Figure 2 Graphical display for QUADAS-2 results. We assessed methodological quality by the QUADAS-2 tool, to evaluate the risk of bias and applicability of primary diagnostic accuracy studies, as described in the text. As the data show in the figure, the overall quality of the studies was satisfactory, with most QUADAS-2 grading in the low-risk range. The QUADAS-2 grading strongly supported applicability of U/S, DECT, and Raman spectroscopy, but there was moderate study bias risk overall; specifically ~30% studies lacked proper knowledge of the results of the reference standard; and ~25% studies without proper patient selection due to non-controlled study designs, and non-randomized subject selection. DECT, dual-energy CT; QUADAS, Quality Assessment of Diagnostic Accuracy Studies; U/S, ultrasound.

limited time, resources or staff to execute CPLM, also can be used in conjunction with CPLM when there is ambiguity in identifying the type of crystal microscopically. Such ambiguity exists more often for CPP crystals which appear to evade detection by CPLM.³³ However, the study refrained from deriving a sensitivity value for POCHR or CPLM because there is no gold standard method that gives 100% accurate diagnosis.

We found only three small studies on elemental bioanalysis,²⁹ metabolomics³⁰ and mass spectroscopy.³¹ Nguyen *et al.*²⁹ carried out elemental bioanalysis using Fourier-transform infrared (FT-IR) spectrometry and scanning electron microscopy (SEM) of 8–10 cartilage zones of the knees from 20 patients with OA, including medial and lateral femoral condyles and tibial plateau and the intercondyle zone. Differential expression of genes involved in the mineralisation process between cartilage with and without calcification was assessed by RT-PCR; immunohistochemistry and histology studies were performed as well.²⁹ Among 141 cartilage samples from 20 patients with OA,²⁹ FT-IR spectroscopy detected calcium-containing (CaC) crystals in 63.8% (90/141) and revealed 4 distinct CaC crystal spectra: CA crystals in 71 samples; CPP crystals were detected in 20 samples from 8 patients; amorphous Ca²⁺ carbonated phosphate crystals in 3 samples from 3 patients, and whitlockite crystals in 4 samples from the same patient. Although preoperative X-rays showed joint calcifications (chondrocalcinosis) in four cases only, the CaC crystal deposition is a widespread phenomenon in human OA articular cartilage. Interestingly, the expression of several genes involved in mineralisation, including human homologue of progressive ankylosis, ectonucleotide pyrophosphatase phosphodiesterase I and tissue non-specific alkaline phosphatase, were upregulated in OA chondrocytes isolated from CaC crystal-containing cartilages.²⁹

Synovial fluid metabolomics by proton (1H) nuclear MR (1H-NMR) spectroscopy was analysed in a study of 59 samples from patients with OA, gout, CPPD, spondyloarthritis, septic arthritis and rheumatoid arthritis.³⁰ Although a distinctive metabolism signature was observed in septic arthritis, metabolites in OA were similar to those in inflammatory arthritis using 1H-NMR.

Last, an elemental bioimaging method with laser ablation inductively coupled plasma mass spectrometry (LA ICP-MS) using a focused laser beam to mobilise sample material as droplets or vapour from the sample surface. The material is then transported to the plasma where the material is ionised and carried through to the mass spectrometer, which selectively detects ions at a given mass-to-charge ratio.³¹ The study obtained cartilage sections from knee or hip arthroplasty and were imaged by LA ICP-MS for the presence of crystal-associated elements. In addition, eight synovial fluid samples, six from patients diagnosed with OA and two from patients diagnosed with rheumatoid arthritis were analysed by the same method. There were corresponding regions of relatively high calcium and phosphorus intensities in the

cartilage section and synovial fluids taken from patients with OA, which may be representative of CPPD crystals. This preliminary study gives a good indication of the potential of LA ICP-MS to detect CPPD crystals in cartilage and synovial fluid samples. However, further studies are needed to confirm crystal presence by SEM.³¹

DISCUSSION

This is the first systematic review, since that of EULAR published in 2011, to examine diagnostic performance of the broad field of established and emerging imaging and crystal analytic measures. We found 26 new studies since 2009 that examined the sensitivity and/or specificity of imaging and crystal analytic diagnostic measures for CPPD. Most studies used comparison to CCA or CR reference standard. Collectively, 7⁸ 9¹¹ 15^{17–19} of the 12 U/S studies suggest that U/S for CPPD may have higher sensitivity and/or specificity compared with CCA.

U/S also is particularly well established in gout.³⁴ Significantly, a recent systematic review/meta-analysis focused on U/S in CPPD, reviewing studies up to 31 December 2014.³² Our report shows similar findings.³² Specifically, the most frequently reported CPPD pattern was hyperechoic foci within fibrocartilage or tendons but with a large range of sensitivity and specificity depending on the examined site: knees better than wrists, ankles, shoulders and hands (MCPs); hyperechoic spots identified more frequently within fibrocartilage than in hyaline cartilage and tendons.

Three U/S studies from 2015 reported moderate-to-high diagnostic performance of U/S with similar sensitivity of 60–100% and specificity of 80–96.7%^{17–19} compared with 87.9% and 91.5%³² in the preceding analysis by Gamon and colleagues. However, prior reports of high sensitivity and specificity performance of U/S for CPPD may be due to evaluation of a combination of several patterns and several sites during the same examination. Whether a specific number of joint sites is required for examination, and which joints to examine by U/S when CPPD is suspected, remain to be determined.⁹ Nevertheless, compared with CCA and CR, U/S results had better specificity and sensitivity for CPPD.^{8 17 19}

Up to this point, there were no studies comparing U/S and Raman or FTIR spectroscopy, and most of the U/S studies used CCA or CR as gold standard for diagnosis of CPPD. Additionally, concurrence of basic calcium phosphate (BCP) and CPPD crystals, and degenerative joint disease has been well established.³¹ BCP deposits can also appear as hyperechoic spots on U/S particularly in tendons, whereas CPPD deposits may be misinterpreted as BCP aggregates because of limitations of the other imaging techniques (ie, X-rays and MRI).¹⁰

A striking observation of our systematic review was that, compared with over 35³⁴ published DECT studies in gout, DECT has only been marginally explored for CPPD. Misra *et al.*²¹ reported that intra-articular calcification in CPPD was seen broadly, including in meniscal fibrocartilage (the

single most common site involved), hyaline cartilage, cruciate ligaments, medial collateral ligament and joint capsule. DECT enables detection of CaC crystals in deeper intra-articular structures. DECT for CPPD appears highly specific, and informative on crystal distribution in various joint tissues, but it is not yet clear whether DECT is superior to CT to detect CaC crystal deposition in the joint. More studies of DECT in CPPD are needed.

In contrast to previously reported work, Abhishek *et al*⁷ observed that chondrocalcinosis (CC) was frequently detected in the wrist (44.4%), hip (45.9%), symphysis pubis (45.5%) and MCP joint (31.3%) in the absence of knee CC. Further imaging studies are needed to replicate the findings about signal characteristics of CC using imaging modalities other than CR.

There has only been one study, to date, on 4 T MRI in CPPD. Specifically, a report of three patients with CC (one woman and two men, age range 54–68 years), and retrospective review of the imaging results of the knees with high-field MRI (4 T MRI), high-resolution three-dimensional CT, conventional radiography and arthroscopy, revealed that high-field MRI demonstrated a greater number of involved articular surfaces and meniscal bodies than CT, radiography and arthroscopy.³⁵ Given that the case series represents a small sample size, and pathological correlation was not available for this study, definitive conclusions regarding sensitivity, specificity, accuracy and direct comparison of the techniques could not be made.³⁵

Methods employed by studies analysed here were satisfactory overall. However, some studies^{15–24–27} used a case–control design. Such designs may exaggerate the diagnostic properties (sensitivity and specificity). Also, the majority of the studies used cross-sectional designs in which patients for whom the clinical question ‘Does this patient have CPPD?’ are referred for participation.

Last, there was great variability in the study protocols used. Standardisation of the methodology used for both U/S, DECT, and Raman spectroscopy are needed. At present, it remains unclear which joints and other sites are optimal for U/S or DECT imaging, and also which scanner settings are most appropriate to achieve optimal sensitivity and specificity for CPPD deposition.

Certain limitations of our analyses should be acknowledged: first the number of studies of U/S, DECT, Raman spectroscopy for CPPD is limited, particularly as compared with U/S in rheumatoid arthritis (RA) or DECT in gout. Second, the number of patients in the selected studies was often low, and comparators used had wide differences (ie, inflammatory arthritis, OA, asymptomatic). To evaluate this limitation, we used the QUADAS-2 tool. Overall, the quality of the studies was satisfactory with most QUADAS-2 grading in the low-risk range. The QUADAS-2 grading strongly supported applicability of U/S, DECT and Raman spectroscopy, but there was moderate study bias risk overall; specifically ~30% studies lacked proper knowledge of the results of the reference standard; and ~25% studies without proper patient

selection due to non-controlled study designs, and non-randomised participant selection (figure 2).

A larger limitation in recent literature is that there has been little discussion and analysis of cost and resource issues for crystal arthropathy diagnostics. In this context, the applicability and efficiency of CPLM, and most other analytic methods for CPPD crystals remain burdened by cost issues of ‘point of care’ access to CPLM equipment. Diagnostic approaches to crystal arthropathies include emerging ‘point of care’ methodologies, exemplified by adaptation of Raman spectroscopy.²⁸ As the field moves forward, we anticipate seeing similar adaptation of other, highly specific crystal analytic methods, such as FTIR spectroscopy.²⁹ However, cost-effectiveness relative to CPLM is not assured. One potential approach to the cost issue may be via lens-free polarised microscopy, with wide-field holographic imaging of birefringent objects, as recently tested, with success, for identification of urate crystals from a tophus.³⁶ This approach employs sensing and imaging methodology that can potentially be broadly adapted to use in conventional mobile electronic devices.³⁶ However, it has not yet clear whether it will be reliable for synovial fluid samples or for identification of CPPD crystals, which can include both non-birefringent and highly polymorphic particulates.

In summary, systematic review of CPPD diagnostic studies since EULAR 2011⁴ indicated that U/S is a highly sensitive and specific tool for the diagnosis of CPPD deposition. However, we identified major unmet needs, including for randomised, blinded, controlled studies of CPPD diagnostic performance and rigorous analyses of DECT, 4 T MRI and other emerging modalities, such as Raman spectroscopy.

Contributors RT is the corresponding author who conceived, and designed the study. In addition, RT supervised in assembling the manuscript, and critical revision of the manuscript for important intellectual content. YW is the first author who performed acquisition of data, literature search, analysis and interpretation of data. Furthermore, YW has drafted the manuscript, designed the tables/figures and conducted the statistical analysis by QUADAS-2 methodology tool. KC is the second author who contributed intellectually to the design and interpretation of the work, reviewed the paper, and participated in data gathering by being the deciding voter for discrepancies when there were differences in QUADAS-2 scores between RT and YW. All authors contributed to refinement of the study protocol and approved the final manuscript.

Competing interests None declared.

Provenance and peer review Not commissioned; externally peer reviewed.

Data sharing statement No additional data are available.

Open Access This is an Open Access article distributed in accordance with the Creative Commons Attribution Non Commercial (CC BY-NC 4.0) license, which permits others to distribute, remix, adapt, build upon this work non-commercially, and license their derivative works on different terms, provided the original work is properly cited and the use is non-commercial. See: <http://creativecommons.org/licenses/by-nc/4.0/>

REFERENCES

1. Terkeltaub R. Calcium crystal disease. Calcium pyrophosphate dihydrate and basic calcium phosphate: Epidemiology. In: Firestein GS, Budd RC, Gabriel SE, McInnes IB, O’Dell JR, eds. *Kelley’s*

- textbook of rheumatology*. 9th edn. Philadelphia: Elsevier Saunders, 2012;1576–7.
- Abhishek A, Doherty M. Pathophysiology of articular chondrocalcinosis —role of ANKH. *Nat Rev Rheumatol* 2011;7:96–104.
 - McCarty DJ. Calcium pyrophosphate dihydrate crystal deposition disease: nomenclature and diagnostic criteria. *Ann Intern Med* 1977;87:241–2.
 - Zhang W, Doherty M, Bardin T, *et al*. European League Against Rheumatism recommendations for calcium pyrophosphate deposition. Part I: terminology and diagnosis. *Ann Rheum Dis* 2011;70:563–70.
 - Whiting PF, Rutjes AWS, Westwood ME, *et al*. QUADAS-2: a revised tool for the quality assessment of diagnostic accuracy studies. *Ann Intern Med* 2011;155:529–36.
 - Abhishek A, Doherty S, Maciewicz R, *et al*. Evidence of a systemic predisposition to chondrocalcinosis and association between chondrocalcinosis and osteoarthritis at distant joints: a cross-sectional study. *Arthritis Care Res (Hoboken)* 2013;65:1052–8.
 - Abhishek A, Doherty S, Maciewicz R, *et al*. Chondrocalcinosis is common in the absence of knee involvement. *Arthritis Res Ther* 2012;14:R205.
 - Barskova VG, Kudaeva FM, Bozhieva LA, *et al*. Comparison of three imaging techniques in diagnosis of chondrocalcinosis of the knees in calcium pyrophosphate deposition disease. *Rheumatology (Oxford)* 2013;52:1090–4.
 - Filippou G, Filippucci E, Tardella M, *et al*. Extent and distribution of CPP deposits in patients affected by calcium pyrophosphate dihydrate deposition disease: an ultrasonographic study. *Ann Rheum Dis* 2013;72:1836–9.
 - Filippucci E, Delle Sedie A, Riente L, *et al*. Ultrasound imaging for the rheumatologist. XLVII. Ultrasound of the shoulder in patients with gout and calcium pyrophosphate deposition disease. *Clin Exp Rheumatol* 2013;31:659–64.
 - Filippucci E, Riveros MG, Georgescu D, *et al*. Hyaline cartilage involvement in patients with gout and calcium pyrophosphate deposition disease. An ultrasound study. *Osteoarthritis Cartilage* 2009;17:178–81.
 - Filippucci E, Scirè CA, Delle Sedie A, *et al*. Ultrasound imaging for the rheumatologist. XXV. Sonographic assessment of the knee in patients with gout and calcium pyrophosphate deposition disease. *Clin Exp Rheumatol* 2010;28:2–5.
 - Gutierrez M, Di Geso L, Filippucci E, *et al*. Calcium pyrophosphate crystals detected by ultrasound in patients without radiographic evidence of cartilage calcifications. *J Rheumatol* 2010;37:2602–3.
 - Lamers-Karnebeek FB, Van Riel PL, Jansen TL. Additive value for ultrasonographic signal in a screening algorithm for patients presenting with acute mono-/oligoarthritis in whom gout is suspected. *Clin Rheumatol* 2014;33:555–9.
 - Löffler C, Sattler H, Peters L, *et al*. Distinguishing gouty arthritis from calcium pyrophosphate disease and other arthritides. *J Rheumatol* 2015;42:513–20.
 - Russell E, Checa A. Potential pitfalls in the diagnosis of crystal-induced arthritis and in the sonographic measurement of hyaline cartilage due to the presence of joint effusion. *J Clin Rheumatol* 2013;19:98–100.
 - Ruta S, Catay E, Marin J, *et al*. Knee effusion: ultrasound as a useful tool for the detection of calcium pyrophosphate crystals. *Clin Rheumatol* 2016;35:1087–91.
 - Zufferey P, Valcov R, Fabreguet I, *et al*. A prospective evaluation of ultrasound as a diagnostic tool in acute microcrystalline arthritis. *Arthritis Res Ther* 2015;17:188.
 - Ottaviani S, Juge PA, Aubrun A, *et al*. Sensitivity and reproducibility of ultrasonography in calcium pyrophosphate crystal deposition in knee cartilage: a cross-sectional study. *J Rheumatol* 2015;42:1511–13.
 - Kobayashi T, Miyakoshi N, Konno N, *et al*. Acute neck pain caused by arthritis of the lateral atlantoaxial joint. *Spine J* 2014;14:1909–13.
 - Misra D, Guermazi A, Sieren JP, *et al*. CT imaging for evaluation of calcium crystal deposition in the knee: initial experience from the Multicenter Osteoarthritis (MOST) study. *Osteoarthritis Cartilage* 2015;23:244–8.
 - Pollet S, Coiffier G, Albert JD, *et al*. Concordance between fresh joint fluid analysis by the rheumatologist and joint fluid analysis at the laboratory: prospective single-center study of 180 samples. *Joint Bone Spine* 2015;82:161–5.
 - Robier C, Quehenberger F, Neubauer M, *et al*. The cytospin technique improves the detection of calcium pyrophosphate crystal in synovial fluid samples with a low leukocyte count. *Rheumatol Int* 2014;34:773–6.
 - Tausche AK, Gehrisch S, Panzner I, *et al*. A 3-day delay in synovial fluid crystal identification did not hinder the reliable detection of monosodium urate and calcium pyrophosphate crystals. *J Clin Rheumatol* 2013;19:241–5.
 - Cheng X, Haggins DG, York RH, *et al*. Analysis of crystals leading to joint arthropathies by Raman spectroscopy: comparison with compensated polarized imaging. *Appl Spectrosc* 2009;63:381–6.
 - Li B, Yang S, Akkus O. A customized Raman system for point-of-care detection of arthropathic crystals in the synovial fluid. *Analyst* 2014;139:823–30.
 - Fuerst M, Lammers L, Schäfer F, *et al*. Investigation of calcium crystals in OA knees. *Rheumatol Int* 2010;30:623–31.
 - Li B, Singer NG, Yeni YN, *et al*. A point-of-care Raman spectroscopy-based device for the diagnosis of gout and pseudogout: comparison with the clinical standard microscopy. *Rheumatol Int* 2016;68:1751–7.
 - Nguyen C, Bazin D, Daudon M, *et al*. Revisiting spatial distribution and biochemical composition of calcium-containing crystals in human osteoarthritic articular cartilage. *Arthritis Res Ther* 2013;15:R103.
 - Hügler T, Kovacs H, Heijnen IA, *et al*. Synovial fluid metabolomics in different forms of arthritis assessed by nuclear magnetic resonance spectroscopy. *Clin Exp Rheumatol* 2012;30:240–5.
 - Austin C, Hare D, Rozelle AL, *et al*. Elemental bio-imaging of calcium phosphate crystal deposits in knee samples from arthritic patients. *Metallomics* 2009;1:142–7.
 - Gamon E, Combe B, Barnetche T, *et al*. Diagnostic value of ultrasound in calcium pyrophosphate deposition disease: a systematic review and meta-analysis. *RMD Open* 2015;1:e000118.
 - Ivorra J, Rosas J, Pascual E. Most calcium pyrophosphate crystals appear as non-birefringent. *Ann Rheum Dis* 1999;58:582–4.
 - Ogdie A, Taylor WJ, Weatherall M, *et al*. Imaging modalities for the classification of gout: systematic literature review and meta-analysis. *Ann Rheum Dis* 2015;74:1868–74.
 - Suan JC, Chhem RK, Gati JS, *et al*. 4 T MRI of chondrocalcinosis in combination with three-dimensional CT, radiography, and arthroscopy: a report of three cases. *Skeletal Radiol* 2005;34:714–21.
 - Zhang Y, Lee SY, Zhang Y, *et al*. Wide-field imaging of birefringent synovial fluid crystals using lens-free polarized microscopy for gout diagnosis. *Sci Rep* 2016;6:28793.