

# UC Davis

## Dermatology Online Journal

### Title

A unique presentation of diffuse multiple eruptive milia

### Permalink

<https://escholarship.org/uc/item/78b6k3p6>

### Journal

Dermatology Online Journal, 31(1)

### Authors

DiLeo, Mckenzie

Moore, Reece

Nelson, Emelie E.

et al.

### Publication Date

2025

### DOI

10.5070/D331164967

### Copyright Information

Copyright 2025 by the author(s). This work is made available under the terms of a Creative Commons Attribution-NonCommercial-NoDerivatives License, available at

<https://creativecommons.org/licenses/by-nc-nd/4.0/>

Peer reviewed

# A unique presentation of diffuse multiple eruptive milia

Mckenzie DiLeo<sup>1</sup> MS, Reece Moore<sup>1</sup> BS, Emelie E. Nelson<sup>1</sup> BS, Rashid M. Rashid<sup>2</sup> MD PhD

Affiliations: <sup>1</sup>University of Texas Health Science Center at Houston McGovern Medical School, Houston, Texas, USA, <sup>2</sup>Mosaic Dermatology, Houston, Texas, USA

Corresponding Author: Rashid M. Rashid MD, Mosaic Dermatology, 2211 Norfolk Suite 405, Houston, TX, 77098. Tel: 281-941-5556, Email: [rashidmdphd@gmail.com](mailto:rashidmdphd@gmail.com)

## Abstract

Milia are small, benign firm white papules that commonly manifest on the face and torso. Several subtypes exist, including multiple eruptive milia—a condition characterized by the eruption of numerous milia that arise over the course of weeks to months. Although limited literature exists on this rare presentation, there seems to be no uniform patient demographic, etiology, or consistent anatomical localization of the milia. We describe a case of multiple eruptive milia presenting diffusely across the cheeks, forehead, superior neck, and preauricular and postauricular skin of an adult female. Additionally, this case is particularly unique as biopsies of representative lesions demonstrate a distinct lymphohistiocytic infiltrate. This atypical presentation underscores a gap in literature regarding multiple eruptive milia and calls into question whether a subtype of milia may exist with an inflammatory component.

*Keywords: inflammatory milia, multiple eruptive*

## Introduction

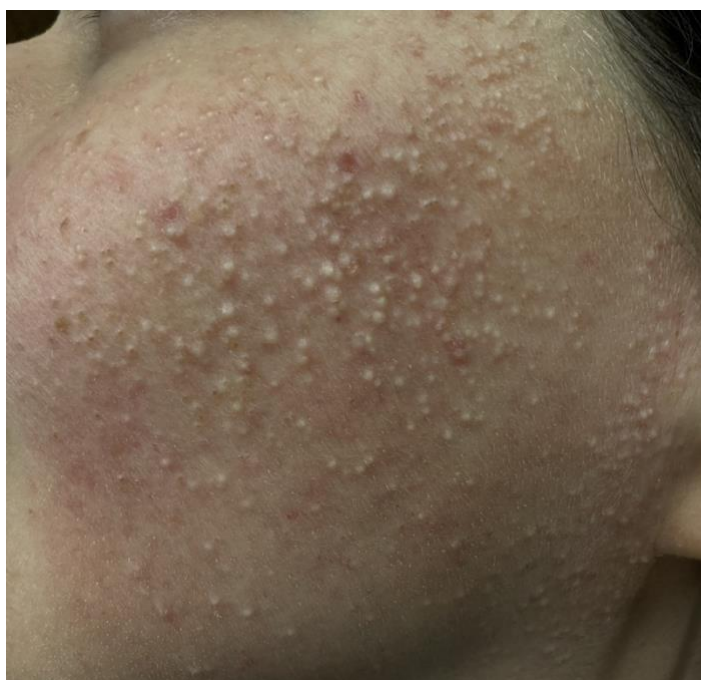Milia are subepidermal keratin cysts that manifest as benign, white, firm papules on the face, torso, and extremities [1]. Milia are subdivided into primary and secondary milia based on their etiology; primary milia arise from the sebaceous glands of vellus hairs, whereas secondary milia arise from eccrine sweat glands [2]. Histologically, they appear as cysts within hair follicles containing layers of stratified squamous epithelium, a granular cell layer, and keratinous

material [1]. Primary milia occur most commonly in children and are distributed across the scalp and face—especially the nose, eyelids, and cheeks. Secondary milia display a similar distribution pattern but arise in response to trauma from cryotherapy, laser therapy, dermabrasion, or chronic use of topical corticosteroids [1,3]. Multiple eruptive milia is a rare condition in which an extensive number of milia appear suddenly, often within weeks [4]. The literature surrounding multiple eruptive milia is extremely limited and individual cases are highly variable in terms of the age of presentation and affected anatomic distribution [5]. Herein, we present a case of spontaneous multiple eruptive milia occurring in an adult patient with a distinct distribution pattern and unique histopathologic findings.

## Case Synopsis

A 34-year-old woman presented to dermatology clinic for evaluation of bothersome bumps across her cheeks, neck, forehead, and behind the ears. The eruption appeared over one year prior, and the cysts increased in number over the first year. The patient's main concern was aesthetic, and she denied any related discomfort or pain. She demonstrated no significant past medical, dermatologic, or family history. Additionally, she was not taking any medications and denied changes in baseline sun exposure, previous trauma, or treatments such as dermabrasion or laser therapy to the area. Physical exam revealed numerous 1mm small white papules diffusely distributed across the cheeks, forehead,

superior neck, or preauricular and postauricular skin with underlying erythema (**Figure 1**). These papules were firm to palpation, with no content extraction with external pressure application. The biopsy showed cysts within hair follicles containing layers of stratified squamous epithelium, a granular cell layer, and inner keratinous material. There was additional background lymphohistiocytic infiltrate suggesting possible concomitant inflammation (**Figure 2**). These findings, paired with the clinical picture, led to the diagnosis of multiple eruptive milia (MEM). Glycolic facial peels and consistent use of topical tretinoin 0.025% showed no appreciable response. She has since been initiated on doxycycline 100mg daily with topical metronidazole 0.75%.

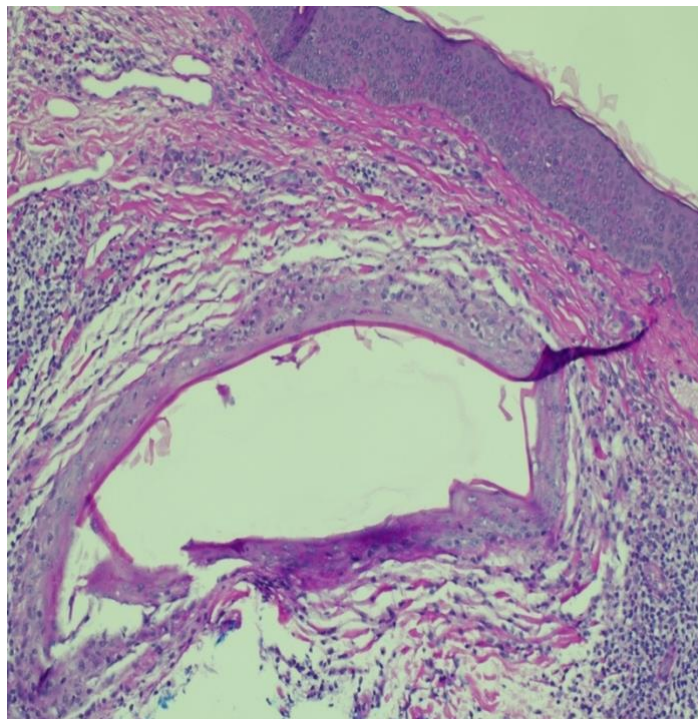


**Figure 1.** Numerous milia of the cheeks, forehead, superior neck, and preauricular and postauricular skin with underlying erythema in a woman.

## Case Discussion

In general, the etiology of milia is poorly understood and most cases of MEM are presumed to be idiopathic. However, a few causes have been identified, including an association with various genodermatoses, excessive sun exposure, and a

history of prior trauma [1,3,5]. These seem improbable given our patient's history. As such, the cause our patient's MEM is likely unclear.



**Figure 2.** Hematoxylin and eosin staining at 10x magnification depicts a cystic structure composed of layers of thick stratified squamous epithelium with a granular cell layer and central keratinous material. There is background lymphohistiocytic infiltrate.

The limited number of previous MEM cases were reviewed and do not present a consistent clinical picture (**Table 1**). This condition affects patients of all ages and does not seem to exhibit a gender predilection. Children, adolescents, and adults were represented, with the youngest patient being two years of age and the eldest 96 years of age. Of the previously documented cases, 8 patients were male and 9 were female.

Additionally, there is no classical pattern of distribution across the skin, as the previous cases report MEM on the face, trunk, arms, or a combination of these sites (**Table 1**). The most common site overall was the facial skin, with approximately 53% of the patients developing MEM on the cheeks, nose, chin, or orbital region. Approximately 47% of patients had milia on the chest or trunk. Notably, MEM did not manifest on the lower extremities but was occasionally present on the

arms and shoulders. Our patient's presentation involves the cheeks, forehead, superior neck, preauricular, and posterior auricular skin—a combined pattern of distribution that deviates from previous cases, further emphasizing the variability of the condition.

The other available case reports describing MEM were also explored to compare biopsy findings (**Table 1**). The majority of patients displayed the expected histopathology of milia, with subepidermal keratin-filled cysts lined with stratified epithelium [12]. Biopsy findings in our patient revealed a background of lymphohistiocytic infiltrate that further distinguished this patient from previous reports. The apparent inflammation resembled histopathologic features of milia en plaque, a condition characterized by erythematous plaques containing a large number of milia [22]. However, milia en plaque classically presents with defined aggregations of milia, whereas our patient's diffuse presentation better fits the description of multiple eruptive milia. The mention of similar histopathology is recorded in a case of a 9-year-old boy with MEM in which the cysts were associated with a chronic inflammatory infiltrate [7]. To our knowledge, these are two isolated findings that may suggest inflammation plays an etiological role in certain patients with MEM. Perhaps a small subclassification should exist to describe milia that presents with clinical features of multiple eruptive milia with concomitant inflammation. Evidence for this comes from the marked absence of inflammation in other cases.

It is important to distinguish this patient's presentation from acute cutaneous lupus erythematosus and facial lichen nitidus. Acute cutaneous lupus erythematosus most often presents with a malar rash across the cheeks and bridge of the nose. In contrast to the small white papules of milia, these lesions are erythematous and coalesce [23]. Lichen nitidus papules are often numerous and similar to the papules of multiple eruptive milia in size. However, they commonly present in younger patients and are typically pink,

brown, or flesh-colored, "shiny and flat-topped" papules [24]. The milia also resemble the epidermal cysts found in chloracne, a rare condition in which dioxin and its toxic metabolites accumulate in sebaceous glands causing aberrant keratinization of sebocytes [25]. However, this is often related to occupational exposure to pesticides by chemical workers and its hallmark histopathologic feature is absence of sebaceous glands [25].

Although benign, milia can be unsightly and frustrating to patients, leading them to seek treatment recommendations. MEM presents an additional challenge given the number of milia and cutaneous surface area involved. Treatment options attempted in prior MEM cases included extraction, topical tretinoin creams, carbon dioxide laser ablation, topical antibiotics, oral azithromycin, oral doxycycline, and curettage and cautery (**Table 1**). Patients achieved a variety of outcomes, including complete resolution, minimal or no improvement, recurrence, or progression of the MEM. Unfortunately, there was no discernible effective regimen amongst the treatments. The singular case utilizing carbon dioxide laser ablation demonstrated complete resolution. However, this required multiple sessions [8]. Another isolated case showed a marked response to an oral azithromycin regimen [20]. Finally, there was documentation of an MEM case with a spontaneous decrease in the number of milia without any treatment or applications [6]. There were also mixed results despite similar treatment selections among patients. For example, an 18-year-old woman achieved complete clearance with tretinoin cream within 6 weeks, whereas others achieved minimal or no response after months of use [11,17].

Theoretically, patients with inflammatory biopsy findings may benefit from incorporation of anti-inflammatory medications into their regimen. There are multiple agents used frequently in dermatology for inflammatory skin conditions and some of these have been previously attempted for MEM cases as described above, albeit the cases were noninflammatory and yielded mixed clinical

outcomes. The retinoid tretinoin has been found to inhibit the release of cytokine interleukin 6 in an in vitro model studying keratinocytes [26]. Tetracyclines exhibit anti-inflammatory mechanisms and are approved by the US Food and Drug Association for the treatment of acne vulgaris and rosacea [27]. Topical metronidazole is also a treatment option for both aforementioned conditions [28,29]. Given the success of antibiotics in the treatment of other cutaneous inflammatory conditions, they may be useful in instances of known inflammation for multiple eruptive milia.

## Conclusion

We present a case of spontaneous multiple eruptive milia in an adult patient with a unique pattern of distribution and histopathological findings. It is important that physicians are aware of the heterogeneity of multiple eruptive milia to best identify it in the clinical setting. Additionally, the histopathological findings of lymphocytic infiltrate correspond to one other reported case, suggesting a small subset of patients may exhibit concomitant inflammation. In such patient populations, the use of anti-inflammatory agents may be a consideration in treatment selection.

## Potential conflicts of interest

The authors declare no conflicts of interest.

## References

- Gallardo Avila PP, Mendez MD. Milia, *StatPearls*. 2023. <https://www.ncbi.nlm.nih.gov/books/NBK560481/>. Accessed on January 14, 2024.
- Patsatsi A, Uy CDC, Murrell DF. Multiple milia formation in blistering diseases. *Int J Womens Dermatol*. 2020;6:199-202. [PMID: 32637544].
- Beutler BD, Cohen PR. Cryotherapy-induced milia en plaque: Case report and literature review. *Dermatol Online J*. 2014;21(2):13030/qt4dw7k4nk. Published 2014 Dec 12. [PMID: 25756481].
- Berk DR, Bayliss SJ. Milia: a review and classification. *J Am Acad Dermatol*. 2008;59:1050-1063. [PMID: 18819726].
- Kurashige Y, Nagatani T. Spontaneous multiple eruptive milia in a 91-year-old man. *J Dermatol*. 2013;40:290-291. [PMID: 23398003].
- Khaled A, Zeglaoui F, Hawilo A, et al. Multiple eruptive milia in a 26 month-old boy. *Tunis Med*. 2012;90:270-271. [PMID: 22481204].
- Diba VC, Handfield-Jones S, Rytina A. Multiple eruptive milia in a 9-year-old boy. *Pediatr Dermatol*. 2008;25:474-476. [PMID: 18789092].
- Pozo JD, Castiñeiras I, Fernández-Jorge B. Variants of milia successfully treated with co(2) laser vaporization. *J Cosmet Laser Ther*. 2010;12:191-194. [PMID: 20590368].
- Sharma R, Singal A, Sonthalia S. Multiple eruptive milia over both external ears. *Indian J Dermatol Venereol Leprol*. 2011;77:519-20. [PMID: 21727706].
- Cairns ML, Knable AL. Multiple eruptive milia in a 15-year-old boy. *Pediatr Dermatol*. 1999;16:108-110. [PMID: 10337672].
- Connelly T. Eruptive milia and rapid response to topical tretinoin. *Arch Dermatol*. 2008;144:816-817. [PMID: 18559787].
- Cho E, Cho SH, Lee JD. Idiopathic multiple eruptive milia occurred in unusual sites. *Ann Dermatol*. 2010;22:465-467. [PMID: 21165223].
- Zhang R, Zhu W, Zhou L. One case of multiple eruptive milia. *G Ital Dermatol Venereol*. 2013;148:308-310. [PMID: 23670069].
- Fett N, Nevas J. Multiple eruptive milia. *Cutis*. 2013;91:191-192. [PMID: 23763079].
- Gonul M, Benar H, Gokce A. Multiple eruptive milia on scalp. *J Eur Acad Dermatol Venereol*. 2016;30:170-172. [PMID: 26551833].
- Wolfe SF, Gurevitch AW. Eruptive milia. *Cutis*. 1997;60:183-184. [PMID: 9347230].
- Batra P, Tsou HC, Warycha M, Votava HJ, Stein J. Multiple eruptive milia. *Dermatol Online J*. 2009;15:20. [PMID: 19891928].
- Diba VC, Al-Izzi M, Green T. A case of eruptive milia. *Clin Exp Dermatol*. 2005;30:677-678. [PMID: 16197387].
- Yahya H. Idiopathic multiple eruptive milia: Report of a case in a Nigerian woman. *Niger J Clin Pract*. 2018;21:395-396. [PMID: 29519993].
- McCarley OE, Mehta A, Levy A, Frey J, Skinner R. Azithromycin therapy for multiple eruptive milia: a report of a case, new treatment option, and review of the literature. *Internet J Dermatol* 2009;7:1.
- Langley RG, Walsh NM, Ross JB. Multiple eruptive milia: Report of a case, review of the literature, and a classification. *J Am Acad Dermatol*. 1997;37:353-356. [PMID: 9270547].
- Terui H, Hashimoto A, Yamasaki K, Aiba S. Milia en plaque as a distinct follicular hamartoma with cystic trichoepitheliomatous features. *Am J Dermatopathol*. 2016;38:212-7. [PMID: 26381115].
- Aranow C, Diamond B, Mackay M. Systemic lupus erythematosus. In: *Clinical immunology sixth edition*. Rich R, Fleisher T, Schroeder HW, Weyand CM, Corry DB, Puck JM, editors. Elsevier; 2023. p. 657-77.
- Schwartz C, Goodman MB. Lichen nitidus, *StatPearls*. 2024. <https://www.ncbi.nlm.nih.gov/books/NBK551709/>. Accessed on March 2, 2024.
- Schlessinger DI, Robinson CA, Schlessinger J. Chloracne, *StatPearls*. 2022. <https://www.ncbi.nlm.nih.gov/books/NBK459189/>.
- Wauben-Pennis PJ, Cerneus DP, van den Hoven WE, et al. Immunomodulatory effects of tretinoin in combination with clindamycin. *J Eur Acad Dermatol Venereol*. 1998;11:S2-S7. [PMID: 9891902].
- Henehan M, Montuno M, Benedetto AD. Doxycycline as an anti-inflammatory agent: Updates in dermatology. *J Eur Acad Dermatol Venereol*. 2017;31:1800-1808. [PMID: 28516469].

28. Khodaeiani E, Fouladi RF, Yousefi N, et al. Efficacy of 2% metronidazole gel in moderate acne vulgaris. *Indian J Dermatol.* 2012;57:279-81. [PMID: 22837561].
29. Schmadel LK, McEvoy GK. Topical metronidazole: A new therapy for rosacea. *Clin Pharm.*1990;9:94-101. [PMID: 2137747].

**Table 1.** Multiple Eruptive Milia Patient Demographics and Histopathological Findings

Patient Age	Sex	Anatomical Location of Milia	Biopsy Obtained	Lymphohistiocytic/ Inflammatory component?	Treatment	Treatment Response	Reference
2	M	Face, Trunk, Hands	Yes	No	No treatment provided	Spontaneous decrease in number	6
9	M	Nose, Cheeks, Shoulder	Yes	Yes, chronic inflammatory infiltrate	Curettage, Cautery	Recurrence	7
12	M	Inner Canthus, Ears	Yes	No	Topical Isotretinoin 0.05%, Erythromycin 2% gel  CO2 laser ablation	No improvement  Resolution with 12 sessions	8
13	F	Ears	Yes	No	Not described	Not described	9
15	M	Eyelid, Nasal bridge	Yes	No	Topical Tretinoin 0.025%	No improvement	10
18	F	Chest	Yes	No	Unspecified oral and topical antibiotics  Topical steroid creams  Tretinoin 0.1% Cream	No improvement  No improvement  Clearance in 6 weeks	11
19	F	Axillae, Abdomen	Yes	No	No treatment provided	No treatment provided	12

34	F	Cheeks, Forehead, Superior neck, Preauricular, Postauricular	Yes	Yes, lymphohistiocytic infiltrate	Glycolic facial peels Topical tretinoin 0.025% Oral Doxycycline 100 mg daily with topical metronidazole 0.75%	No improvement No improvement Response not yet evaluated	This Patient
36	F	Forehead, Infraorbital	Yes	No	Adapalene gel 0.1%	Partial Response	13
40	M	Nose, Cheeks, Periorbital	Yes	No	Tretinoin 0.1% Cream	Flattening of the lesions with 3 months use	14
47	F	Scalp	Yes	No	Oral doxycycline 100 mg daily Ketoconazole shampoo	No improvement	15
48	F	Neck, Back	Yes	No	Not described	Not described	16
61	M	Face, Chest, Back, Arms	Yes	No	Oral doxycycline and Topical Clindamycin Solution Topical tretinoin cream, extraction, intralesional injections of triamcinolone acetonide	Minimal change Minimal change and development of new lesions	17
68	F	Scalp, Chin, Chest	Yes	No	Electrolysis treatments, Point cautery	Partial response	18
70	F	Forehead, Glabella, Cheeks	Yes	No	Tretinoin 0.05% Cream	Not described	19



70	F	Axillae, Chest, Neck	Yes	No	Azithromycin 500 mg day one, 250 mg days two to five on first and third week of the month for three months	Notable improvement in 8 months	20
71	M	Trunk, Shoulders, Arms	Yes	No	Not described	Not described	21
96	M	Neck	Yes	No	No treatment provided	No treatment provided	5

\*The information in this table was adapted from Kurashige et al and Gonul et al. [5, 15]