

**UCLA**

**Proceedings of UCLA Health**

**Title**

A Case of Lichen Nitidus Mimicking Papular Sarcoidosis

**Permalink**

<https://escholarship.org/uc/item/77w43849>

**Journal**

Proceedings of UCLA Health, 21(1)

**Authors**

Rabi, Sina

Pouldar, Delila

Hisaw, Lisa

et al.

**Publication Date**

2017-03-09

## CLINICAL VIGNETTE

# A Case of Lichen Nitidus Mimicking Papular Sarcoidosis

Sina Rabi, BA, Delila Pouldar, BS, Lisa Hisaw, M.D., Daniel Neill, M.D., and Lorraine Young, M.D.

### Case Synopsis

A 45-year-old female with biopsy-proven sarcoidosis presented for evaluation of a pruritic papular rash for four months. Her rash first developed on her right upper chest with intermittent pruritus. At the time of presentation, the patient's sarcoidosis was stable on infliximab, methotrexate, and prednisone. The patient reported that she felt her rash may have flared with her most recent infliximab infusion and coincided with a change in celecoxib from brand name to generic.

Since her initial presentation, her rash spread to involve her upper back, right neck, and bilateral upper extremities. Of note, patient was previously seen two years ago for a papular rash on her chest and shoulders. Biopsy at that time demonstrated focal lichenoid dermatitis flanked by claw-like epidermal extension, consistent with lichen nitidus (Figure 1A). Patient had rapid resolution of her prior rash with topical fluocinonide gel.

Examination of her new rash revealed multiple flesh-colored pinpoint papules along the patient's chest, upper back, right neck, and bilateral upper extremities (Figure 2A & 2B). The differential diagnosis included lichen nitidus, papular sarcoidosis, and drug eruption. Infliximab and celecoxib were discontinued. Two punch biopsies were performed.

Initial biopsy demonstrated patchy interface change, superficial and mid-dermal, perivascular inflammation with a rare eosinophil. No granulomas were present. Subsequent biopsy demonstrated a claw-like configuration with thin, deep extensions of epithelium into the dermis on either side of a prominent discreet focus of dermal inflammatory infiltrate (Figure 1B).

Her rash has since persisted and progressed, despite discontinuation of infliximab and celecoxib. Given her clinical presentation and histopathological findings, the presumptive diagnosis of lichen nitidus was made. Patient has tried multiple topical steroids including desoximetasone and topical pimecrolimus without improvement of her rash. Her pruritus has modestly responded to oral antihistamines. Patient will begin narrowband-UVB therapy with response still pending.

### Discussion

Lichen nitidus is a rare, benign dermatosis of unknown origin, usually seen in children and young adults. It typically presents as multiple pinhead-sized flesh-colored papules with a shiny surface.<sup>1</sup> Linear distributions may be observed due to Köbner phenomenon.<sup>2</sup> Lesions are typically localized on the trunk,

abdomen, extremities, or genitalia. Generalized involvement is rare.<sup>3</sup>

Diagnosis of lichen nitidus can occasionally be made with clinical presentation alone in more obvious cases. Histopathological findings include focal parakeratosis with a thinned overlying epidermis and vacuolar alteration of the basal layer. Characteristic findings include a "ball in claw"-like configuration of elongated thinned rete ridges surrounding a focal inflammatory infiltrate, typically composed of lymphocytes and histiocytes.<sup>4</sup>

Our patient had biopsy-proven sarcoidosis with multi-organ involvement, including mediastinal lymphadenopathy, panuveitis, and inflammatory polyarthritis. Sarcoidosis is a systemic granulomatous disorder of unknown etiology, most commonly involving the lungs, lymph nodes, and skin.<sup>5</sup> About 20% of patients with sarcoidosis have skin disease, and there are numerous clinical presentations described, thus known as the "great imitator." Papular sarcoidosis is a very common specific manifestation of cutaneous sarcoidosis.<sup>5</sup> Histopathology demonstrates non-caseating granulomas.

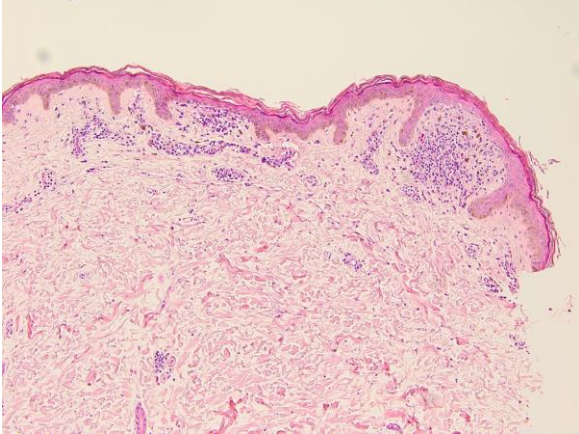
Given the onset of our patient's skin lesions in the setting of sarcoidosis, papular variant of cutaneous sarcoidosis was a major consideration, as well as lichen nitidus and drug eruption. Histopathological findings however demonstrated an absence of granulomas and showed a claw-like configuration of thinned epidermis surrounding a focal inflammatory infiltrate, consistent with lichen nitidus. In 1985, Okamoto and colleagues described a case of micropapular sarcoidosis mimicking lichen nitidus.<sup>6</sup> To the best of our knowledge, we are the first to report a case of lichen nitidus mimicking papular sarcoidosis in a patient with biopsy-proven sarcoidosis.

Lichen nitidus usually follows a self-limiting course and is typically asymptomatic. Treatment is usually reserved for symptomatic patients, and common treatment modalities described in the literature include topical corticosteroids, topical calcineurin inhibitors, oral antihistamines, and ultraviolet light therapy.<sup>1</sup>

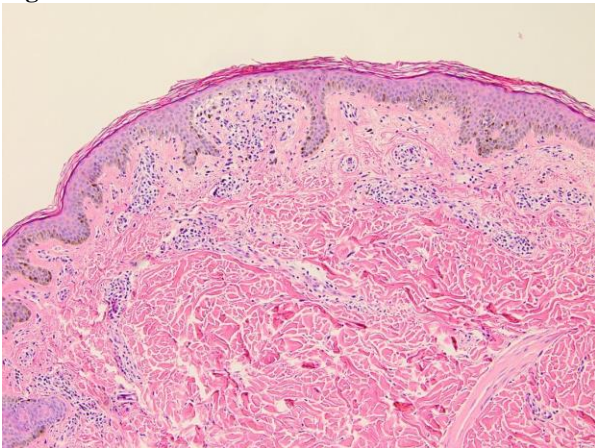
## Figures

**Figure 1A and 1B.** These sections demonstrate the characteristic "ball in claw" histological finding, with relatively deep, thin extensions of epithelium into the dermis on either side of a prominent, discreet focus of dermal inflammatory infiltrate. Pigment incontinence and a non-specific perivascular lymphocytic infiltrate are also present. Figure 1A is from 2014, while Figure 1B is from 2016. (H&E, original magnification x100).

**Figure 1A.**

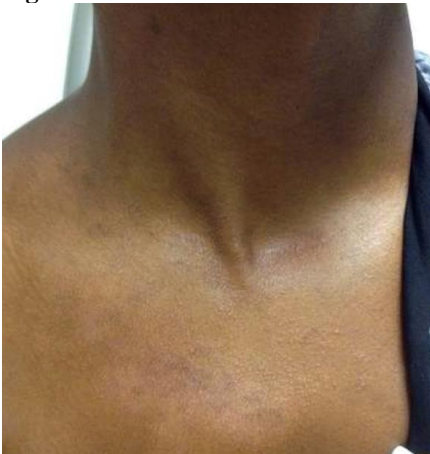

**Figure 1B.**

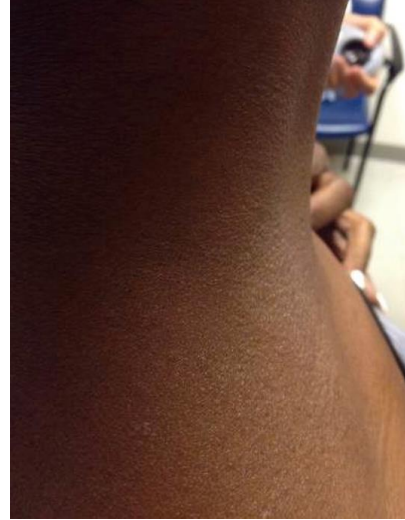


**Figure 2A and 2B.** Multiple pinhead flesh-colored papules observed on the patient's chest and right upper neck.

**Figure 2A.**



**Figure 2B.**



## REFERENCES

1. **Chu J, Lam JM.** Lichen nitidus. *CMAJ.* 2014 Dec 9;186(18):E688. doi:10.1503/cmaj.140434. PubMed PMID: 25349001; PubMed Central PMCID: PMC4259797.
2. **Pinkus H, Shair HM.** Koebner phenomenon in lichen nitidus; report of two cases. *AMA Arch Derm Syphilol.* 1952 Jan;65(1):82-7. PubMed PMID: 14877293.
3. **Rallis E, Verros C, Moussatou V, Sambaziotis D, Papadakis P.** Generalized purpuric lichen nitidus. Report of a case and review of the literature. *Dermatol Online J.* 2007 May 1;13(2):5. Review. PubMed PMID: 17498424.
4. **Shockman S, Lountzis N.** Lichen nitidus. *Cutis.* 2013 Dec;92(6):288, 297-8. PubMed PMID: 24416748.
5. **Haimovic A, Sanchez M, Judson MA, Prystowsky S.** Sarcoidosis: a comprehensive review and update for the dermatologist: part I. Cutaneous disease. *J Am Acad Dermatol.* 2012 May;66(5):699.e1-18; quiz 717-8. doi: 10.1016/j.jaad.2011.11.965. Review. PubMed PMID: 22507585.
6. **Okamoto H, Horio T, Izumi T.** Micropapular sarcoidosis simulating lichen nitidus. *Dermatologica.* 1985;170(5):253-5. PubMed PMID: 4007221.

Submitted March 9, 2017