

UC Irvine

Journal of Education and Teaching in Emergency Medicine

Title

Use of Bedside Compression Ultrasonography for Diagnosis of Deep Venous Thrombosis

Permalink

<https://escholarship.org/uc/item/77f8k6k8>

Journal

Journal of Education and Teaching in Emergency Medicine, 2(3)

Authors

Moussa, Mohamad
Abdo, Maher

Publication Date

2017

DOI

10.5070/M523035686

Copyright Information

Copyright 2017 by the author(s). This work is made available under the terms of a Creative Commons Attribution License, available at <https://creativecommons.org/licenses/by/4.0/>

Peer reviewed

Use of Bedside Compression Ultrasonography for Diagnosis of Deep Venous Thrombosis

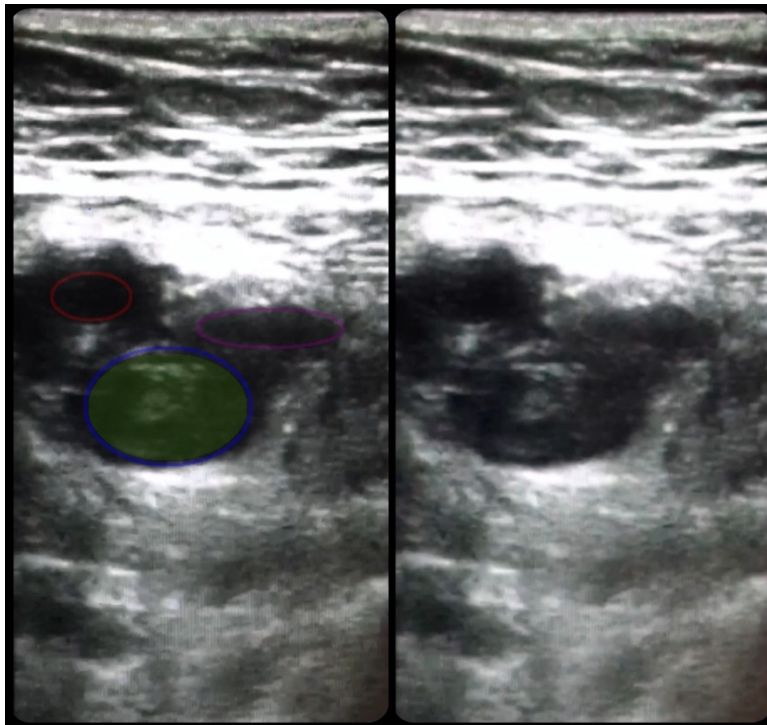
Mohamad Moussa, MD* and Maher Abdo, BS*

*University of Toledo Medical Center, Department of Emergency Medicine, Toledo, OH

Correspondence should be addressed to Mohamad Moussa, MD at Mohamad.Moussa@UToledo.edu

Submitted: May 17, 2017; Accepted: July 3, 2017; Electronically Published: July 14, 2017; <https://doi.org/10.21980/J81G94>

Copyright: © 2017 Moussa et al. This is an open access article distributed in accordance with the terms of the Creative Commons Attribution (CC BY 4.0) License. See: <http://creativecommons.org/licenses/by/4.0/>



Video Link: <https://youtu.be/lzioQeaAtBA>

History of present illness: A 70-year-old female with a history of breast cancer and smoking for 50 years presented to the emergency department with left-lower extremity pain and swelling for two days. The patient denied recent long-distance travel, history of hypercoagulable disorder, or recent surgery. Physical examination revealed a warm, erythematous, 3+ edematous left-lower extremity with mild tenderness extending into the proximal thigh. Her D-dimer level was 2307 ng/mL and vital signs were significant for a heart rate of 110/minute, oxygen saturation of 90% on 2 liters of oxygen, and blood pressure of 153/102 mmHg.

Significant findings: As shown in the still image of the performed ultrasound, a transverse view of the proximal-thigh revealed a visible thrombus (green shading) occluding the lumen of the left common femoral vein (blue ring), which was non-compressible when direct pressure was applied to the probe. Also visible is a patent and compressible branch of the common femoral vein (purple ring) and the femoral artery (red ring), highlighted by its thick vessel wall and pulsatile motion.

Discussion: Deep venous thrombosis (DVT) affects 1 per 1,000 individuals each year and may lead to complications such as recurrent DVT, pulmonary embolism, and death.¹ The utilization of bedside compression ultrasonography allows for rapid diagnosis of DVT and has virtually replaced other diagnostic methods due to its non-invasive and inexpensive nature.

When performing compression ultrasonography, the patient should be positioned to maximize distention of the leg veins. The extremity in question should be flexed at the knee and externally rotated at the hip (this fully exposes of the common, superficial, and deep femoral veins as well as the popliteal fossa) and the head of the bed elevated at a 30-45 degree angle.²

In patients with an elevated D-dimer and low-to-moderate clinical probability, negative compression imaging of a single proximal location of the femoral vein rules out DVT.³ However, those with high clinical probability and negative imaging require additional studies such as complete extremity ultrasound imaging or serial ultrasound surveillance.³ In this case, computed tomography angiography (CTA) was negative for pulmonary embolism (PE); however, bedside ultrasound of the left-lower extremity demonstrated deep venous thrombosis (DVT). The patient was started on enoxaparin and admitted due to the large size of the thrombus and history of poor outpatient follow-up.

Topics: Ultrasound, US, POCUS, DVT, deep venous thrombosis.

References:

1. Kim DJ, Byyny RL, Rice CA, Faragher JP, Nordenholz KE, Haukoos JS, et al. Test characteristics of emergency physician-performed limited compression ultrasound for lower-extremity deep vein thrombosis. *J Emerg Med.* 2016;51(6):684-690. doi: 10.1016/j.jemermed.2016.07.013
2. Del Rios M, Lewiss, RE, Saul T. Focus on: emergency ultrasound for deep vein thrombosis. ACEP clinical & practice management. <https://www.acep.org/Clinical---Practice-Management/Focus-On--Emergency-Ultrasound-For-Deep-Vein-Thrombosis/>. Published March 2009. Accessed July 12, 2017.
3. Bates SM, Jaeschke R, Stevens SM, Goodacre S, Wells PS, Stevenson MD, et al. Diagnosis of DVT. Antithrombotic therapy and prevention of thrombosis. *Chest.* 2012;141(2 Suppl):e351S-e418S. doi: 10.1378/chest.11-2299