

UCLA

UCLA Previously Published Works

Title

Assessment of Intermediate Severity Coronary Lesions in the Catheterization Laboratory

Permalink

<https://escholarship.org/uc/item/76r207j4>

Journal

Journal of the American College of Cardiology, 49(8)

ISSN

0735-1097

Authors

Tobis, Jonathan
Azarbal, Babak
Slavin, Leo

Publication Date

2007-02-01

DOI

10.1016/j.jacc.2006.10.055

Copyright Information

This work is made available under the terms of a Creative Commons Attribution License, available at <https://creativecommons.org/licenses/by/4.0/>

Peer reviewed

STATE-OF-THE-ART PAPER

Assessment of Intermediate Severity Coronary Lesions in the Catheterization Laboratory

Jonathan Tobis, MD, Babak Azarbal, MD, Leo Slavin, MD

Los Angeles, California

The management of intermediate coronary lesions, defined by a diameter stenosis of 40% to 70%, continues to be a therapeutic dilemma for cardiologists. The 2-dimensional representation of the arterial lesion provided by angiography is limited in distinguishing intermediate lesions that require stenting from those that simply need appropriate medical therapy. In the era of drug-eluting stents, some might propose that stenting all intermediate coronary lesions is an appropriate solution. However, the possibility of procedural complications such as coronary dissection, no reflow phenomenon, in-stent restenosis, and stent thrombosis requires accurate stratification of patients with intermediate coronary lesions to appropriate therapy. Intravascular ultrasound (IVUS) and fractional flow reserve index (FFR) provide anatomic and functional information that can be used in the catheterization laboratory to designate patients to the most appropriate therapy. The purpose of this review is to discuss the critical information obtained from IVUS and FFR in guiding treatment of patients with intermediate coronary lesions. In addition, the importance of IVUS and FFR in the management of patients with serial stenosis, bifurcation lesions, left main disease, saphenous vein graft disease, and acute coronary syndrome will be discussed. (J Am Coll Cardiol 2007;49:839–48) © 2007 by the American College of Cardiology Foundation

An intermediate coronary lesion on angiography is defined as a luminal narrowing with a diameter stenosis $\geq 40\%$ but $\leq 70\%$. Assessment of a coronary lesion with intermediate severity continues to be a challenge for cardiologists. In the current era of drug-eluting stents (DES), when percutaneous coronary revascularization is achieved with high success, a low complication rate, and excellent long-term patency (1,2), it might be tempting to treat all suspect lesions with implantation of a DES. However, there are still procedural complications associated with angioplasty, the inherent risk of restenosis, and late stent thrombosis.

Although it is preferable to have objective evidence of myocardial ischemia before proceeding with percutaneous coronary revascularization, this is not always feasible or completely reliable. Selective coronary angiography is accepted as the standard for determining the presence and extent of epicardial coronary artery disease (CAD). All measures of noninvasive assessment of myocardial ischemia are compared with the presence on angiography of a focal stenosis $>50\%$ diameter. This cutoff is based on animal studies and human clinical correlations that demonstrate functional significance (the induction of ischemia) with the anatomic presence of a 50% diameter stenosis (3). However, there is significant interobserver and intra-observer variability in interpretation of the severity of stenoses on coronary angiography (4–6). In addition, cross-sectional anatomic

imaging obtained from histopathological specimens (7–11) and intravascular ultrasound (IVUS) (12–15) have highlighted limitations of coronary angiography. Owing to the increased sensitivity of IVUS in identifying disease and its close correlation with pathology, IVUS has become the more accurate standard for defining the anatomy of atherosclerosis in vivo.

There are 2 methods available in the cardiac catheterization laboratory to determine the physiologic significance of a coronary stenosis that are distinct from the anatomic visualization provided by IVUS. These methods rely on the decrease in intra-arterial pressure or flow induced by a functionally significant stenosis to determine whether an intermediate lesion is producing ischemia. At the current time, coronary pressure wire-derived fractional flow reserve (FFR) has supplanted Doppler wire-derived coronary flow reserve (CFR) as the preferred method to assess the physiologic significance of a coronary stenosis.

This review will discuss the challenges involved in the assessment and management of a patient with an intermediate lesion. It will focus on the 2 most commonly used methods for assessment of intermediate coronary lesions: IVUS and FFR (Table 1).

Limitations of Angiography

Histopathological studies have demonstrated that angiographic evidence of stenosis is usually not detected until the cross-sectional area of plaque approaches 40% to 50% of the total cross-sectional area of the vessel (16–18). The outer wall of the artery, encompassed by the external

From the David Geffen School of Medicine at UCLA, Department of Medicine (Division of Cardiology), Los Angeles, California.

Manuscript received June 19, 2006; revised manuscript received September 7, 2006, accepted October 16, 2006.

**Abbreviations
and Acronyms**

ACS = acute coronary syndrome
AMI = acute myocardial infarction
CAD = coronary artery disease
CFR = coronary flow reserve
DES = drug-eluting stent
EEM = external elastic membrane
FFR = fractional flow reserve
IVUS = intravascular ultrasound
MACE = major adverse cardiovascular event
PCI = percutaneous coronary intervention
SPECT = single-photon emission computed tomography
SVG = saphenous vein graft

elastic membrane (EEM), enlarges to accommodate the growing plaque. This process of compensatory dilatation seems to be limited. When the plaque area exceeds 40% to 50% of the EEM area, the plaque begins to encroach upon the lumen. It is only then that an angiogram might reveal minimal luminal narrowing (19,20). A minority of angiographic stenoses might develop by a process of narrowing of the EEM without the presence of a large amount of plaque, a process called negative remodeling (21,22).

Similar to a low power histologic cross section, IVUS can identify the presence and extent of plaque and the area of the EEM in vivo, thereby making it more sensitive than angiography (7–12,14,15,17,23). In addition, angiography provides only limited information regarding the composition of the coronary plaque or the degree of calcification (17,24–26).

Similar to a flashlight projection of a tube in 3-dimensional space, an angiogram is a 2-dimensional X-ray projection of the arterial lumen along the length of the vessel. Stenoses might be incorrectly assessed owing to tortuosity or angulation of the

vessels, artery overlap, a short “napkin-ring stenosis,” X-ray beam angulation that is not perpendicular to the stenosis, or contrast streaming or separation as it enters an ectatic area. The extent of stenosis is judged by comparison with a reference segment that theoretically is free of disease. However, the reference segment itself often has significant disease as demonstrated by histopathology or IVUS (26). In addition, significant intra- and inter-observer variability exists in the assessment of coronary stenoses (27). Although the advent of quantitative coronary angiography (QCA) has reduced inter-observer variability, it has not improved the accuracy of coronary angiography to determine the severity of coronary lesions.

IVUS

Intravascular ultrasound is a catheter-based technique that provides tomographic images perpendicular to the length of the coronary arteries. High-resolution cross-sectional images of the coronary lumen and the coronary arterial wall can be visualized in real time, and computer-generated reconstruction allows for longitudinal and 3-dimensional visualization of the coronary artery (Fig. 1). Intravascular ultrasound is simple to perform, and its use is associated with very low complication rates (28), even in the setting of acute myocardial infarction (AMI) (29).

Intravascular ultrasound can segregate lesions according to whether they appear stable versus unstable on the basis of the ultrasound grayscale reflectance of the tissue (30). Stable plaques have more fibrous tissue or calcification, whereas an unstable plaque has mobile echoes consistent with thrombus or necrotic material and usually is associated with large atheroma (30). The presence of a plaque with an echolucent central core and a thin fibrous capsule, the so-called “vulnerable plaque,” can also be identified by IVUS. Whether these lesions should be treated by percutaneous coronary intervention (PCI) versus medical therapy has not been elucidated by clinical trials.

The advent of radiofrequency signal analysis and elastography techniques might in the future provide incremental clinical information regarding the exact histologic composition of atherosclerotic plaques and possibly their vulnerability to rupture (31); however, there is no convincing evidence that so-called “virtual histology” adds any information beyond the traditional IVUS grayscale image, and it could be misleading.

Despite the elaborate anatomic information provided by IVUS, there are some technical limitations, including the inability to deliver the catheter to the region of interest in tortuous vessels, through high-grade or calcified stenoses, and in smaller epicardial arteries. Other limitations include non-uniform rotational distortion (NURD) with mechanical IVUS transducers and distortion of the cross-sectional image if the IVUS catheter image plane is not perpendicular to the long axis of the vessel (32). Unlike 2-dimensional transthoracic echocardiography, there is no phased array IVUS device. The closest approximation

Table 1 Comparison of IVUS With FFR in Specific Lesion Subsets

	IVUS	FFR
Native CAD	MLD ≥ 1.8 mm MLA ≥ 4.0 mm ²	≥ 0.75 –0.8
Left main	MLD ≥ 2.8 mm MLA ≥ 5.9 mm ²	≥ 0.75
Serial lesions	Assesses anatomic severity along the length of the artery	Relative contribution of each stenosis on pullback method
SVG	Identifies severe lesion and tissue characteristics. Helps identify when to use distal protection device	No data for FFR in SVG; data correlating rCFR with SPECT available
Ostial lesions	Helps locate ostial-aorta juncture and correct stent position	≥ 0.75
Acute MI	Demonstrates plaque burden	Limited data
Bifurcation lesions	Assesses size of main and side branch, adequacy of results	≥ 0.75

CAD = coronary artery disease; FFR = fractional flow reserve; IVUS = intravascular ultrasound; MI = myocardial infarction; MLA = minimum lumen area; MLD = minimum lumen diameter; rCFR = relative coronary flow reserve; SPECT = single-photon emission computed tomography; SVG = saphenous vein graft.

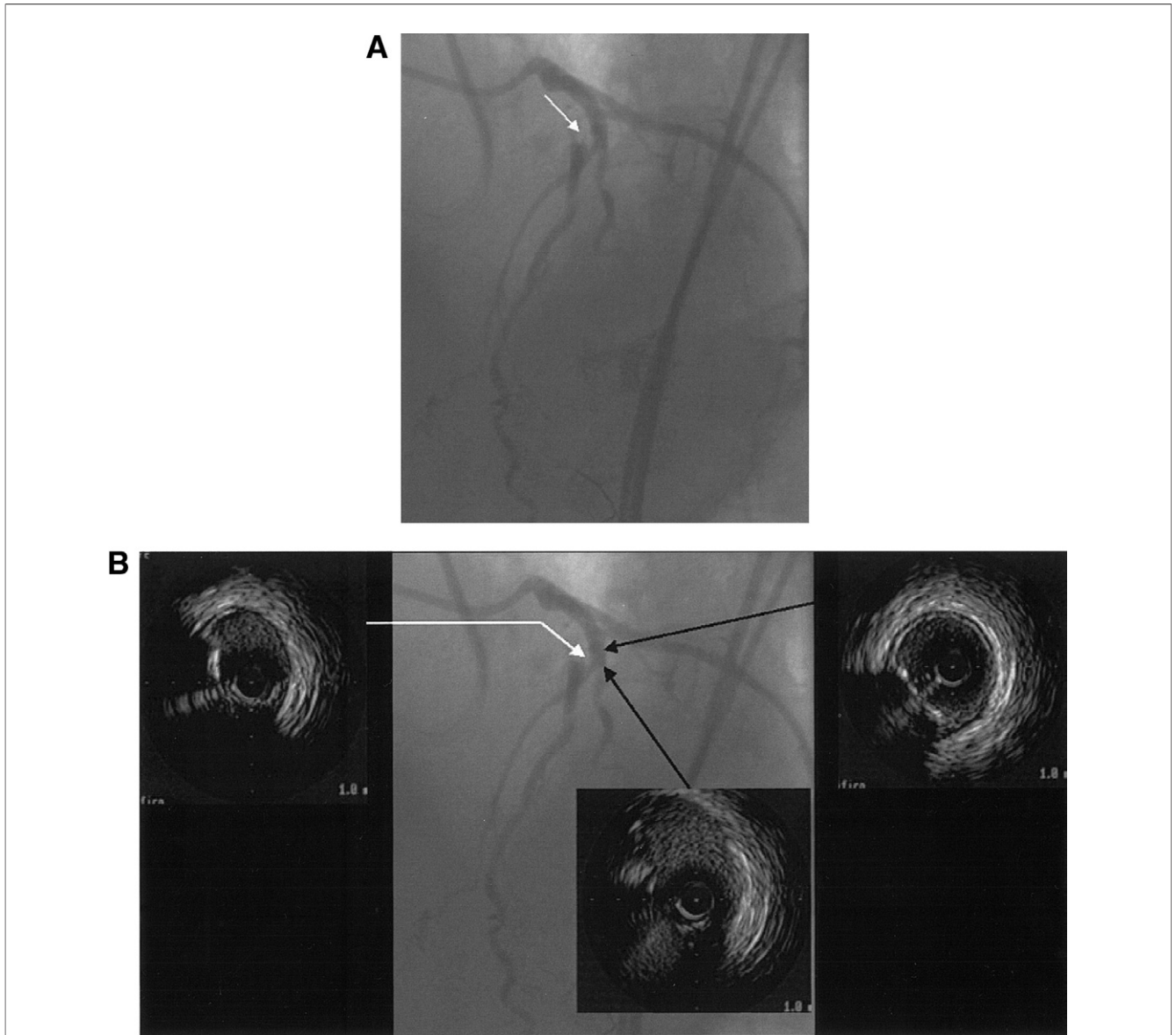


Figure 1 Intermediate Lesion That According to an Expert Panel Requires an Intervention on the Basis of the Images Attained From Coronary Angiography

(A) A coronary angiogram that shows an intermediate lesion in the mid-left anterior descending artery (LAD) just distal to the bifurcation with the diagonal branch. This case was presented during an international live case presentation conference with a panel of 8 renowned interventional cardiologists. There was no accord among the cardiologists whether this angiogram represented a significant stenosis. There were conflicting recommendations whether to perform coronary angioplasty in the LAD. (B) Intravascular ultrasound (IVUS) imaging was performed. Representative cross-sectional IVUS images are shown. (Left) At the greatest area of stenosis, the smallest dimension of the lumen was 4.7 mm^2 . (Right) The IVUS image proximal to the bifurcation. (Middle) The IVUS cross-sectional image of the mid-LAD at the level of the bifurcation with the diagonal branch. Fractional flow reserve (FFR) was also performed and was measured at 0.85. Contrary to the panel's suggestions based on the angiogram, on the basis of the IVUS images and FFR, no intervention was performed.

is the synthetic aperture device that has the transducer and multiplex transistors at the catheter tip. Because there is no mechanically rotating device shaft, the synthetic aperture ultrasound catheter passes over the wire through a central lumen. This facilitates maneuvering the catheter through more torturous anatomy. However, this benefit of ease of use comes with a consequence of lower power and inferior image quality.

CFR

Blood flow as volume/time cannot be measured directly in humans in the catheterization laboratory. The concept of CFR was introduced in the 1970s and is based on the principle that blood velocity is proportional to volume flow if the lumen area remains constant. The CFR is defined as the ratio of hyperemic mean blood velocity to resting blood velocity for a given

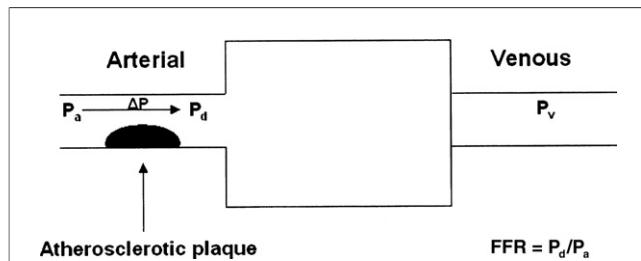


Figure 2 Fractional Flow Reserve

A schematic cartoon demonstrating the concept and derivation of fractional flow reserve (FFR). $FFR = (P_d - P_v)/(P_a - P_v)$. The central venous pressure approaches 0; therefore, P_v is negligible and $FFR = P_d/P_a$. P_a = mean proximal coronary artery pressure; P_d = mean coronary artery pressure distal to the lesion; P_v = mean central venous pressure.

coronary artery (3,33). The CFR decreases with increased lesion severity (34). Doppler-derived CFR measurements have been validated in the assessment of lesion severity, and a CFR value of ≤ 2.0 has been found to identify a hemodynamically significant stenosis (35–39).

Unfortunately, the CFR value is affected by both epicardial and microvascular resistance. Conditions such as diabetes, ventricular hypertrophy, and age can all affect CFR independent of the degree of epicardial coronary artery stenosis (40–43). The concept of relative CFR has been introduced to overcome some of the limitations associated with CFR in assessment of epicardial coronary artery stenosis. Relative CFR is obtained by dividing the CFR of the reference vessel by the CFR obtained in an adjacent “normal” coronary vessel. This requires interrogation of an additional coronary vessel (44).

Because of the limitations in interpretation of CFR and relative CFR, neither of these modalities has gained widespread acceptance, and these techniques have been supplanted by the use of FFR.

FFR

One method of overcoming the limitations of coronary angiography is the use of invasive physiologic testing by the FFR technique to assess the functional significance of a coronary stenosis. The FFR is defined as the ratio of maximal blood flow achievable in a stenotic coronary artery relative to the maximal flow in the same vessel if it were normal (45–47) (Fig. 2). A 0.014-inch pressure sensor-tipped coronary angioplasty guide wire is advanced across a stenosis, and the absolute distal pressure is recorded at rest and at maximal hyperemia induced with intracoronary or intravenous infusion of adenosine. Unlike CFR, FFR is independent of changes in heart rate, blood pressure, or prior infarction, and takes into account the contribution of collateral blood flow (46,48).

An FFR value of <0.75 correlates with ischemia on non-invasive stress tests (46,47,49,50). Several studies have demonstrated that in patients with an intermediate coronary lesion

and an $FFR \geq 0.75$, PCI can safely be deferred (47,51,52). Cardiac event rates are extremely low in this cohort of patients and even lower than that predicted if a PCI with a bare metal stent had been performed owing to the lack of restenosis in the deferred treatment group (52,53). The FFR is lesion specific and can be performed in patients with both single- or multi-vessel CAD (54). Once a PCI is performed, adequacy of the PCI result can be assessed by FFR with established criteria for a successful balloon angioplasty ($FFR \geq 0.90$) and stent placement ($FFR \geq 0.94$) (55). Significant abnormal distal coronary pressure values after stenting predict adverse events at follow-up (56,57).

Attaining maximum vasodilation is critical for the accuracy of FFR measurement. The lack of a maximum hyperemic response produces a lower pressure gradient across the lesion and therefore underestimates its severity (58). There are various pharmacological agents that include adenosine, adenosine 5'-triphosphate (ATP), papaverine, and dobutamine that could be administered intravenously (IV) or intracoronary (IC) (59–64). Owing to the low cost and high safety profile, IC adenosine is used in the majority of FFR assessments. However, the assessment of long lesions with diffuse disease or multiple lesions require a steady state induced by either IV adenosine or ATP or IC papaverine for the pressure pull-back maneuver (62,63).

Studies have shown that occlusion of an epicardial coronary artery leads to perivascular edema and capillary leukocyte plugging that prevents full restoration of myocardial perfusion (65). The FFR is limited in the presence of this microvascular dysfunction observed in AMI. In these patients the FFR is overestimated, given that the ratio is measured in reference to maximum hyperemia at the level of the epicardial coronary artery with the assumption that the microvasculature is intact.

Lesion Assessment in Specific Lesion Subsets

Left main coronary artery stenosis. Left main coronary artery stenosis, as defined by a diameter stenosis on coronary angiography of $\geq 50\%$, is found in 5% of diagnostic coronary angiograms (66). Assessment of left main CAD can be one of the most challenging lesion subsets for angiographers. In the CASS (the Coronary Artery Surgery Study) trial, when one observer reported $\geq 50\%$ left main coronary artery stenosis, a second angiographer reported no stenosis 19% of the time (27).

The FFR has been evaluated in a subset of patients with left main coronary artery stenosis. In 1 study, an $FFR > 0.75$ was associated with excellent 3-year survival and freedom from major adverse cardiovascular events (MACE) (67). Similarly, a study of 122 patients by Abizaid et al. (68) demonstrated that patients with a left main minimum lumen diameter (MLD) >3.0 mm determined by IVUS had a very low 1-year event rate of 3%. Two recent studies of ambiguous left main coronary artery stenosis have shown a good correlation between IVUS and FFR in detection

of hemodynamically significant CAD of the left main coronary artery (69,70). A cutoff value of 5.9 mm² was found to correlate best with an FFR of ≥ 0.75 (70).

If angioplasty of the left main artery is being considered, we prefer using IVUS beforehand to assess the anatomy, the size of the vessels, and determine whether both left anterior descending and circumflex ostia are involved. The IVUS also reveals the extent of calcification and can be useful in deciding whether the lesion should be prepared with rotational atherectomy to facilitate placement of the stent.

Assessment of serial stenoses within a single coronary artery. Patients with CAD often have multiple stenoses within a single coronary artery, 1 or more of which might be an intermediate coronary lesion. Both IVUS and FFR can assist in the determination of the clinical significance of each lesion as well as the optimal treatment strategy.

One study has demonstrated that FFR can accurately determine the hemodynamic significance of serial coronary lesions when performed via a slow “pull back method” during continuous intravenous infusion of adenosine. The findings of the pullback method were validated in the same study when PCI of 1 of the 2 lesions (the more hemodynamically significant lesion) was performed. The information provided could lead to avoidance of unnecessary procedures that increase the restenosis risk without providing a hemodynamic benefit (71).

Intravascular ultrasound also assists in the assessment of serial stenosis within a single coronary artery. During a continuous mechanical pullback of the IVUS catheter, the images provide detailed anatomical information on the extent and characteristics of each arterial cross section. Intravascular ultrasound helps determine which lesions along the length of the artery are anatomically significant and therefore what length of artery needs to be treated with a stent. However, the hemodynamic status along the length of the artery in question cannot be determined by IVUS pullback alone.

Coronary bypass grafts. By 5 years after coronary artery bypass graft surgery, vein graft disease affects 48% of grafts and 81% at 15 years (72). However, treatment of degenerated saphenous vein grafts (SVGs) by PCI is associated with a lower procedural success rate, a higher periprocedural complication rate, and a higher restenosis rate (73–76).

Saphenous vein grafts have a different ultrasonographic appearance compared with native coronary arteries. There are no side branches, and veins do not have an EEM; nevertheless, the extent of plaque can be easily identified by IVUS. Perhaps of greater importance, IVUS can characterize the quality of the tissue present and determine whether there is soft mobile material or thrombus in the graft. However, some SVG lesions, even in old grafts, might be fibrotic and are less likely to embolize when treated with PCI (74). The pathogenesis of vein graft disease has been elucidated by IVUS (77,78). Early changes of wall thickening and adaptive remodeling predispose patients to subsequent atherosclerosis with occlusive plaque and constrictive

or expansive remodeling (21,77–79). These findings correlate with histopathologic studies and in the future might establish windows for potential interventions. Currently, there are no clinical trials that evaluate the effectiveness of IVUS-guided PCI in patients with SVG disease (78).

Provided the native vessel is occluded proximal to the anastomosis of the bypass graft, FFR across a bypass graft stenosis might provide an accurate reflection of the coronary flow at maximal hyperemia to the distal myocardial bed supplied by the bypass graft. There is a relative paucity of published reports that assesses the physiological significance of bypass graft stenoses. Currently, there are no clinical trials that evaluate the role of FFR in assessing the need for PCI in patients with SVG disease. However, 1 study evaluated Doppler flow velocity and myocardial perfusion single-photon emission computed tomography (SPECT) compared with angiography in assessment of SVG stenoses. Although there was a poor correlation between angiography and either SPECT or CFR, the latter 2 had an excellent correlation in the detection of ischemia (83%, kappa = 0.61) (80).

Bifurcation lesions. Assessment of severity of coronary stenosis in bifurcation lesions as well as the performance of PCI in bifurcation lesions remains challenging (81–85). Despite the emergence of DES, bifurcation lesions have a higher restenosis rate especially at the ostium of the side branch in comparison with simple lesions (85,86). Angiographic assessment of the severity of bifurcation lesions is hampered by the inherent limitations of angiography, especially overlap of adjacent vessels, angulation, and foreshortening of the origin of the side branch (86).

Intravascular ultrasound can be useful in the assessment of bifurcation lesions in determining the need for PCI (87). Intravascular ultrasound can also assist in equipment selection and planning the PCI approach on the basis of the size of the vessels and the location of the plaque. It has been demonstrated that when the “crush technique” is used for bifurcation stenting, the smallest minimum stent area is typically at the ostium of the side branch, which might in part explain the higher restenosis rate observed at these locations (84).

Physiologic determination of the hemodynamic significance of bifurcation lesions can also be reliably addressed with FFR. Separate FFR analysis of each branch can be performed to assess the hemodynamic significance of each stenosis and provides functional information that corresponds with morphological analysis (86). Koo *et al.* (88) evaluated the feasibility and safety of physiological assessment of jailed side branches with FFR in 97 patients. The study demonstrated that no lesion with <75% stenosis by quantitative coronary angiography (QCA) had FFR <0.75 and among 73 lesions with >75% stenosis only 20 were functionally significant (88). Thus, most of the lesions involving the jailed side branch might not have functional significance and do not require revascularization. Ziaee *et al.* (86) showed that 80% of patients with >70% stenosis of the

side branch had FFR >0.75 in their cohort. The use of FFR in the assessment of bifurcation lesions might prevent unnecessary interventions in lesions that are not functionally restrictive. The need for revascularization of the side branch in bifurcation lesions can be guided by hemodynamic parameters as determined by FFR.

Acute coronary syndromes (ACS). Although FFR provides critical physiological assessment of coronary artery stenosis in patients with stable CAD, limited data are available on the utility of FFR in lesion assessment in patients with ACS. Fractional flow reserve should not be used in the acute phase of an AMI due to severe microvascular impairment (58). However, FFR still has a critical role in the assessment of the non-infarct-related arteries. Pressure readings are only useful after the culprit artery has been stabilized. Recently, Tamita et al. (89) assessed the utility and anatomic correlation of FFR in 33 patients with AMI that underwent successful coronary stenting in comparison with 15 patients with stable angina. The study demonstrated no significant correlation between FFR and IVUS in AMI patients with Thrombolysis In Myocardial Infarction (TIMI) flow grades 2 or 3. An FFR >0.94 was observed in all TIMI flow grade 2 cases independent of residual stenosis, and there was a significant increase in FFR in the TIMI flow grade 2 group in comparison with stable CAD or TIMI flow grade 3 patients ($p = 0.02$). The authors concluded that severe microvascular dysfunction that occurs in AMI causes FFR to greatly underestimate the pressure gradient across a potential flow-limiting lesion. Muramatsu (90) used FFR <0.94 in 40 patients with AMI to determine the effectiveness of FFR-guided stenting. The results showed no significant difference in the reocclusion rates or long-term survival in FFR-guided versus the direct stenting group. There was a significant decrease in the number of balloons used and total cost of hospital stay in the FFR-guided group versus the direct stenting controls.

The FFR is still useful in lesion assessment in patients with previous MI. Claeys et al. (91) showed that FFR is falsely increased by approximately 5% in patients with microvascular dysfunction. De Bruyne et al. (92) determined that FFR assessments are valid in detecting ischemia in patients 6 days after an MI. Usui et al. (93) demonstrated that FFR assessment of coronary stenosis in patients with previous MI had a sensitivity and specificity of 79% in comparison with thallium-201 imaging. A recent study by Potvin et al. (94) evaluated the safety of FFR ≥ 0.75 in deferring PCI in 124 patients with unstable angina, non-ST-segment elevation myocardial infarction, or recent ST-segment elevation myocardial infarction. At mean follow-up of 11 months, event-free survival was 89% in the ACS group. There was no significant difference in MACE in patients with stable CAD and ACS that did not undergo revascularization on the basis of FFR ≥ 0.75 . These results were similar to data presented by Legalery et al. (95) that found a 10% event rate in a group of 75 patients with ACS treated medically on the basis of FFR ≥ 0.80 . Leesar et al.

(50) randomized 70 patients with ACS and moderate stenosis on angiography to decisions based on FFR versus myocardial scintigraphy and found that there was no significant difference between the 2 modalities in the frequency of event rates at 1-year. Another 2 observational studies that included a total of 42 patients with unstable angina or MI showed an 11% event rate at 1-year (96,97). These studies demonstrated the utility of FFR in deferring PCI in non-flow-limiting lesions in patients with ACS and avoiding unnecessary interventions that have a higher complication rate in these patients. Although there are no large randomized, controlled trials that have established the efficacy of FFR in patients with ACS, observational data described previously demonstrate that FFR provides complementary functional information that could be used in clinical decision-making in patients with ACS.

Intravascular ultrasound can also be performed safely in the setting of AMI (29). Intravascular ultrasound can identify anatomically significant lesions, delineate extent of plaque burden, identify ulcerated or ruptured plaque, assess for presence and extent of intracoronary thrombus, distinguish arterial dissection from thrombosis, and assist in selection and sizing of equipment for performance of coronary intervention. Another important potential application of IVUS is identification of atheroma at risk for rupture on the basis of the echolucency, lipid-laden plaque, and expansive remodeling observed in ACS (32). Hasegawa et al. (98) evaluated 73 patients with AMI with preintervention IVUS to further delineate the properties of unstable plaque. The group found that 55% of patients demonstrated expansive remodeling and 25% showed constrictive remodeling. A previous study by von Birgelen et al. (99) also revealed a predominance of expansive remodeling and soft plaque in patients with ACS. Although IVUS has expanded the clinical understanding of the pathogenesis of atherosclerosis in stable and unstable plaque, a limited number of studies have evaluated the role of IVUS in directing interventions in patients with AMI. One study demonstrated that conservative treatment in 17 patients with AMI and nonsignificant lesions by IVUS despite evidence of plaque rupture was associated with a very low incidence of MACE at 1 year (100). Rioufol et al. (101) evaluated 14 patients diagnosed with ACS that were found to have a total of 28 ruptured plaques without critical stenoses in a nonculprit coronary artery on IVUS. The patients were treated medically and followed for a mean of 22 months. There were no significant cardiovascular events related to the lesion at follow-up, and 14 of 28 ruptured plaques healed with medical therapy. Another study conducted a subset analysis of 42 patients with unstable angina, showing that the presence of plaque ruptures on IVUS corresponded to elevated levels of creatine kinase (CK)-MB and increased rates of MACE (cardiac death, Q-wave MI, and target lesion revascularization) at 1-year follow-up (102). Intravascular ultrasound provides critical information regarding the pathogenesis of atherosclerosis, plaque remodeling, and has

demonstrated benefit in guiding therapy in small trials in patients with ACS.

The no-reflow phenomenon, defined by the acute reduction in coronary flow in the setting of a patent epicardial coronary artery is an uncommon complication of PCI (0.6% to 2.0%) (103). More frequently, it occurs during rotational atherectomy, interventions involving SVGs, and AMI (103). Up to 30% of PCIs performed in the setting of AMI are complicated by the “no-reflow” phenomenon where no blood flow proceeds distally despite a successful balloon dilatation or stent insertion (104,105). Although, the precise pathophysiology of no-reflow is still uncertain, various mechanisms, including microvascular spasms, distal embolization of thrombus or atherosclerotic debris, oxygen-free radical-mediated endothelial injury, or capillary inflammatory injury have been proposed (103). Intravascular ultrasound can predict lesions at higher risk for “no-reflow” after PCI, owing to the plaque mass and loose tissue components of the plaque (105). In addition, IVUS can rule out other causes of poor flow after PCI such as coronary dissection or residual stenosis (106).

Ostial lesions. Analogous to assessment of lesion severity in bifurcation stenoses, assessment of ostial lesion severity is confounded by vessel overlap with the aorta, angulation, and deep seating of the catheter beyond the ostial lesion (107). In a study of 46 patients where 55 ostial lesions were evaluated, 20 of 25 patients (80%) determined to have stenosis severity of 70% or greater had an FFR ≥ 0.75 (86). Although sensitivity of angiography in this study was 100%, the specificity was only 55%; there was an excellent correlation between presence of ischemia by noninvasive stress imaging studies and FFR.

Intravascular ultrasound is also helpful for diagnosing and treating ostial lesions. Intravascular ultrasound can delineate the extent of stenosis as well as the plaque burden at the ostial location, although heavy calcification limits the penetration of the ultrasound images. Precise placement of the stent at the aorta-ostial juncture is often challenging when using fluoroscopic guidance. The corresponding position of the IVUS catheter on the fluoroscopic image at the cross section where the ostium is observed on the ultrasound image can be very useful in ensuring correct stent placement. Without moving the image intensifier, the stent is placed in the same position as the IVUS catheter was when the aorta-ostial juncture was seen by ultrasound. After PCI, IVUS is helpful to confirm that the entire ostium has been covered by the stent, which will decrease the chance of restenosis.

Comparison of IVUS and FFR

Although IVUS does not provide direct estimation of the hemodynamic severity of a coronary lesion, several studies have demonstrated a strong correlation between anatomic data obtained from IVUS and ischemia by myocardial perfusion SPECT imaging (108), CFR (109), and FFR

(110,111). Briguori *et al.* (111) evaluated 53 lesions in 43 patients with both IVUS and FFR. Receiver operating characteristic curve analysis demonstrated that the following IVUS parameters correlated with an abnormal FFR value (≤ 0.75) (in order of decreasing sensitivity and specificity): $>70\%$ area stenosis, minimal lumen diameter ≤ 1.8 mm, minimal lumen cross-sectional area ≤ 4.0 mm², and lesion length >10 mm. Another study by Takagi *et al.* (110) evaluated 51 lesions in 42 patients with both FFR and IVUS. Intravascular ultrasound parameters that best correlated with an FFR value ≤ 0.75 were $>60\%$ area stenosis and a minimal lumen cross-sectional area <3.0 mm². By providing precise information on vessel size, extent of the atherosclerosis, and plaque characteristics, IVUS images help guide PCI strategy, equipment selection, and assessment of the adequacy of the results.

Fractional flow reserve provides important physiologic information on the hemodynamic severity of a coronary lesion and is helpful in the cardiac catheterization laboratory to determine whether PCI should be performed without stopping the procedure and sending the patient for a noninvasive stress test. Fractional flow reserve is easy to perform and provides an accurate and lesion-specific index of functional severity of coronary stenosis that correlates with noninvasive tests of myocardial ischemia in patients with intermediate lesions (112). Fractional flow reserve has been compared with IVUS as a measurement for optimal stent deployment. One retrospective analysis showed that FFR ≥ 0.94 after stent deployment had a concordance rate of 91% with IVUS and displayed accuracy in guiding stent deployment (55). However, another study revealed that FFR ≥ 0.96 did not reliably predict an optimum stent result (113). The correlation between adverse outcomes after angioplasty and stenting and the FFR index has been evaluated. Bech *et al.* (114), in 60 patients, showed excellent clinical outcomes at 2 years in patients with diameter stenosis $\leq 35\%$, and FFR ≥ 0.90 . Pijls *et al.* (56) showed that a post-stent FFR ≥ 0.90 was associated with low incidence of the composite end point of death, MI, or total vessel revascularization at 6 months.

The heterogeneity of the patients studied in the multiple registries and differences in methodology between studies create difficulty in evaluating the efficacy of IVUS and FFR in specific clinical settings. There are no randomized, controlled trials to demonstrate the superiority of FFR versus IVUS in providing improved clinical outcomes in comparison with angiography alone. However, the issue of superiority might be irrelevant, because IVUS and FFR are complementary techniques that are used in the catheterization laboratory to provide critical anatomic and functional data that permit more accurate decisions in the management of the patient. In our laboratory, both methods are used: FFR is preferred to identify whether an intermediate lesion is functionally significant, and IVUS is preferred when assessing the anatomy of a lesion for sizing, position of plaque, and adequacy of stent deployment.

Conclusions

Both FFR and IVUS imaging add important functional and anatomic information to augment the luminal images provided by coronary angiography. Fractional flow reserve and IVUS help identify intermediate lesions that require intervention and reduce unnecessary procedures with potential complications. Although FFR and IVUS have eloquent proponents for either technique, both procedures are valuable in the cardiac catheterization laboratory and provide critical information that supplements the foundation of high-quality angiography.

Reprint requests and correspondence: Dr. Jonathan M. Tobis, David Geffen School of Medicine at UCLA, Adult Cardiac Catheterization Laboratory, BL-394 Center for Health Sciences, Box 171715, 10833 Le Conte Avenue, Los Angeles, California 90095-1717. E-mail: jtobis@mednet.ucla.edu.

REFERENCES

1. Stone GW, Ellis SG, Cox DA, et al. One-year clinical results with the slow-release, polymer-based, paclitaxel-eluting TAXUS stent: the TAXUS-IV trial. *Circulation* 2004;109:1942–7.
2. Moses JW, Leon MB, Popma JJ, et al. Sirolimus-eluting stents versus standard stents in patients with stenosis in a native coronary artery. *N Engl J Med* 2003;349:1315–23.
3. Gould KL, Lipscomb K, Hamilton GW. Physiologic basis for assessing critical coronary stenosis. Instantaneous flow response and regional distribution during coronary hyperemia as measures of coronary flow reserve. *Am J Cardiol* 1974;33:87–94.
4. DeRouen TA, Murray JA, Owen W. Variability in the analysis of coronary arteriograms. *Circulation* 1977;55:324–8.
5. Goldberg RK, Kleiman NS, Minor ST, Abukhalil J, Raizner AE. Comparison of quantitative coronary angiography to visual estimates of lesion severity pre and post PTCA. *Am Heart J* 1990;119:178–84.
6. Zir LM. Observer variability in coronary angiography. *Int J Cardiol* 1983;3:171–3.
7. Vlodaver Z, Frech R, Van Tassel RA, Edwards JE. Correlation of the antemortem coronary arteriogram and the postmortem specimen. *Circulation* 1973;47:162–9.
8. Grondin CM, Dyrda I, Pasternac A, Campeau L, Bourassa MG, Lesperance J. Discrepancies between cineangiographic and postmortem findings in patients with coronary artery disease and recent myocardial revascularization. *Circulation* 1974;49:703–8.
9. Hutchins GM, Bulkley BH, Ridolfi RL, Griffith LS, Lohr FT, Piasio MA. Correlation of coronary arteriograms and left ventriculograms with postmortem studies. *Circulation* 1977;56:32–7.
10. Arnett EN, Isner JM, Redwood DR, et al. Coronary artery narrowing in coronary heart disease: comparison of cineangiographic and necropsy findings. *Ann Intern Med* 1979;91:350–6.
11. Blankenhorn DH, Curry PJ. The accuracy of arteriography and ultrasound imaging for atherosclerosis measurement. A review. *Arch Pathol Lab Med* 1982;106:483–9.
12. Nissen SE, Grines CL, Gurley JC, et al. Application of a new phased-array ultrasound imaging catheter in the assessment of vascular dimensions. In vivo comparison to cineangiography. *Circulation* 1990;81:660–6.
13. Tobis JM. Intravascular ultrasound. A fantastic voyage. *Circulation* 1991;84:2190–2.
14. Nissen SE, Gurley JC. Application of intravascular ultrasound for detection and quantitation of coronary atherosclerosis. *Int J Card Imaging* 1991;6:165–77.
15. Tobis JM, Mahon DJ, Goldberg SL, Nakamura S, Colombo A. Lessons from intravascular ultrasonography: observations during interventional angioplasty procedures. *J Clin Ultrasound* 1993;21:589–607.
16. Glagov S, Weisenberg E, Zarins CK, Stankunavicius R, Kolettis GJ. Compensatory enlargement of human atherosclerotic coronary arteries. *N Engl J Med* 1987;316:1371–5.
17. Tobis JM, Mallery J, Mahon D, et al. Intravascular ultrasound imaging of human coronary arteries in vivo. Analysis of tissue characterizations with comparison to in vitro histological specimens. *Circulation* 1991;83:913–26.
18. Hodgson JM, Reddy KG, Suneja R, Nair RN, Lesnefsky EJ, Sheehan HM. Intracoronary ultrasound imaging: correlation of plaque morphology with angiography, clinical syndrome and procedural results in patients undergoing coronary angioplasty. *J Am Coll Cardiol* 1993;21:35–44.
19. Hausmann D, Lundkvist AJ, Friedrich G, Sudhir K, Fitzgerald PJ, Yock PG. Lumen and plaque shape in atherosclerotic coronary arteries assessed by in vivo intracoronary ultrasound. *Am J Cardiol* 1994;74:857–63.
20. Mintz GS, Popma JJ, Pichard AD, et al. Limitations of angiography in the assessment of plaque distribution in coronary artery disease: a systematic study of target lesion eccentricity in 1446 lesions. *Circulation* 1996;93:924–31.
21. Nishioka T, Luo H, Eigler NL, Berglund H, Kim CJ, Siegel RJ. Contribution of inadequate compensatory enlargement to development of human coronary artery stenosis: an in vivo intravascular ultrasound study. *J Am Coll Cardiol* 1996;27:1571–6.
22. Mintz GS, Kent KM, Pichard AD, Satler LF, Popma JJ, Leon MB. Contribution of inadequate arterial remodeling to the development of focal coronary artery stenoses. An intravascular ultrasound study. *Circulation* 1997;95:1791–8.
23. Waller BF, Roberts WC. Amount of narrowing by atherosclerotic plaque in 44 nonbypassed and 52 bypassed major epicardial coronary arteries in 32 necropsy patients who died within 1 month of aortocoronary bypass grafting. *Am J Cardiol* 1980;46:956–62.
24. Keren G, Leon MB. Characterization of atherosclerotic lesions by intravascular ultrasound: possible role in unstable coronary syndromes and in interventional therapeutic procedures. *Am J Cardiol* 1991;68:85B–91B.
25. Mintz GS, Douek P, Pichard AD, et al. Target lesion calcification in coronary artery disease: an intravascular ultrasound study. *J Am Coll Cardiol* 1992;20:1149–55.
26. Mintz GS, Painter JA, Pichard AD, et al. Atherosclerosis in angiographically “normal” coronary artery reference segments: an intravascular ultrasound study with clinical correlations. *J Am Coll Cardiol* 1995;25:1479–85.
27. Fisher LD, Judkins MP, Lesperance J, et al. Reproducibility of coronary arteriographic reading in the Coronary Artery Surgery Study (CASS). *Cathet Cardiovasc Diagn* 1982;8:565–75.
28. Hausmann D, Erbel R, Alibelli-Chemarin MJ, et al. The safety of intracoronary ultrasound. A multicenter survey of 2207 examinations. *Circulation* 1995;91:623–30.
29. Bocksch W, Schartl M, Beckmann S, Dreyse S, Fleck E. Safety of intracoronary ultrasound imaging in patients with acute myocardial infarction. *Am J Cardiol* 1998;81:641–3.
30. Schaar JA, van der Steen AF, Mastik F. Intravascular palpography for vulnerable plaque assessment. *J Am Coll Cardiol* 2006;47 Suppl: C86–91.
31. Sipahi I, Nicholls SJ, Tuzcu EM. Recent trends in coronary intravascular ultrasound: tracking atherosclerosis, pursuit of vulnerable plaques, and beyond. *J Nucl Cardiol* 2006;13:91–6.
32. Nissen SE, Yock P. Intravascular ultrasound: novel pathophysiological insights and current clinical applications. *Circulation* 2001;103:602–16.
33. Dimitrow PP, Galderisi M, Rigo F. The non-invasive documentation of coronary microcirculation impairment: role of transthoracic echocardiography. *Cardiovasc Ultrasound* 2005;3:18–26.
34. Gould KL, Kirkeeide RL, Buchi M. Coronary flow reserve as a physiologic measure of stenosis severity. *J Am Coll Cardiol* 1990;15:459–74.
35. Doucette JW, Corl PD, Payne HM, et al. Validation of a Doppler guide wire for intravascular measurement of coronary artery flow velocity. *Circulation* 1992;85:1899–911.
36. Labovitz AJ, Anthonis DM, Cravens TL, Kern MJ. Validation of volumetric flow measurements by means of a Doppler-tipped coronary angioplasty guide wire. *Am Heart J* 1993;126:1456–61.

37. Miller DD, Donohue TJ, Younis LT, et al. Correlation of pharmacological 99mTc-sestamibi myocardial perfusion imaging with post-stenotic coronary flow reserve in patients with angiographically intermediate coronary artery stenoses. *Circulation* 1994;89:2150-60.
38. McGinn AL, White CW, Wilson RF. Interstudy variability of coronary flow reserve. Influence of heart rate, arterial pressure, and ventricular preload. *Circulation* 1990;81:1319-30.
39. Heller LI, Cates C, Popma J, et al. Intracoronary Doppler assessment of moderate coronary artery disease: comparison with 201Tl imaging and coronary angiography. FACTS Study Group. *Circulation* 1997;96:484-90.
40. Lorenzoni R, Gistri R, Cecchi F, et al. Coronary vasodilator reserve is impaired in patients with hypertrophic cardiomyopathy and left ventricular dysfunction. *Am Heart J* 1998;136:972-81.
41. Czernin J, Muller P, Chan S, et al. Influence of age and hemodynamics on myocardial blood flow and flow reserve. *Circulation* 1993;88:62-9.
42. Akasaka T, Yoshida K, Hozumi T, et al. Retinopathy identifies marked restriction of coronary flow reserve in patients with diabetes mellitus. *J Am Coll Cardiol* 1997;30:935-41.
43. Schafer S, Kelm M, Mingers S, Strauer BE. Left ventricular remodeling impairs coronary flow reserve in hypertensive patients. *J Hypertens* 2002;30:31-7.
44. Voudris V, Avramides D, Koutelou M, et al. Relative coronary flow velocity reserve improves correlation with stress myocardial perfusion imaging in assessment of coronary artery stenoses. *Chest* 2003;124:1266-74.
45. Pijls NH, van Son JA, Kirkeeide RL, De Bruyne B, Gould KL. Experimental basis of determining maximum coronary, myocardial, and collateral blood flow by pressure measurements for assessing functional stenosis severity before and after percutaneous transluminal coronary angioplasty. *Circulation* 1993;87:1354-67.
46. Kern MJ, De Bruyne B, Pijls NH. From research to clinical practice: current role of intracoronary physiologically based decision making in the cardiac catheterization laboratory. *J Am Coll Cardiol* 1997;30:613-20.
47. Pijls NH, De Bruyne B, Peels K, et al. Measurement of fractional flow reserve to assess the functional severity of coronary-artery stenoses. *N Engl J Med* 1996;334:1703-8.
48. De Bruyne B, Bartunek J, Sys SU, Pijls NH, Heyndrickx GR, Wijns W. Simultaneous coronary pressure and flow velocity measurements in humans. Feasibility, reproducibility, and hemodynamic dependence of coronary flow velocity reserve, hyperemic flow versus pressure slope index, and fractional flow reserve. *Circulation* 1996;94:1842-9.
49. Caymaz O, Fak AS, Tezcan H, et al. Correlation of myocardial fractional flow reserve with thallium-201 SPECT imaging in intermediate-severity coronary artery lesions. *J Invasive Cardiol* 2000;12:345-50.
50. Leesar MA, Abdul-Baki T, Akkus NI, Sharma A, Kannan T, Bolli R. Use of fractional flow reserve versus stress perfusion scintigraphy after unstable angina. Effect on duration of hospitalization, cost, procedural characteristics, and clinical outcome. *J Am Coll Cardiol* 2003;41:1115-21.
51. Kern MJ, Donohue TJ, Aguirre FV, et al. Clinical outcome of deferring angioplasty in patients with normal translational pressure-flow velocity measurements. *J Am Coll Cardiol* 1995;25:178-87.
52. Bech GJ, De Bruyne B, Bonnier HJ, et al. Long-term follow-up after deferral of percutaneous transluminal coronary angioplasty of intermediate stenosis on the basis of coronary pressure measurement. *J Am Coll Cardiol* 1998;31:841-7.
53. Bech GJ, De Bruyne B, Pijls NH, et al. Fractional flow reserve to determine the appropriateness of angioplasty in moderate coronary stenosis: a randomized trial. *Circulation* 2001;103:2928-34.
54. Chamuleau SA, Meuwissen M, Koch KT, et al. Usefulness of fractional flow reserve for risk stratification of patients with multivessel coronary artery disease and an intermediate stenosis. *Am J Cardiol* 2002;89:377-80.
55. Hanekamp CEE, Koolen JJ, Pijls N, et al. Comparison of quantitative coronary angiography, intravascular ultrasound, and coronary pressure measurement to assess optimum stent deployment. *Circulation* 1999;99:1015-21.
56. Pijls NH, Klauss V, Siebert U, et al. Coronary pressure measurement after stenting predicts adverse events at follow-up: a multicenter registry. *Circulation* 2002;105:2950-4.
57. Rieber J, Schiele TM, Erdin P, et al. Fractional flow reserve predicts major adverse cardiac events after coronary stent implantation. *Z Kardiol* 2002;91 Suppl 3:132-6.
58. Hau WK. Fractional flow reserve and complex coronary pathologic conditions. *Eur Heart J* 2004;25:723-7.
59. Di Segni E, Higano ST, Rihal CS, et al. Incremental doses of intracoronary adenosine for the assessment of coronary velocity reserve for clinical decision making. *Cathet Cardiovasc Intervent* 2001;54:34-40.
60. Yamada H, Azuma A, Hirasaki S, et al. Intracoronary adenosine 5'-triphosphate as an alternative to papaverine for measuring coronary flow reserve. *Am J Cardiol* 1994;74:940-1.
61. Sonoda S, Takeuchi M, Nakashima Y, et al. Safety and optimal dose of intracoronary adenosine 5'-triphosphate for the measurement of coronary flow reserve. *Am Heart J* 1998;135:621-7.
62. Jeremias A, Filardo SD, Whitbourn RJ, et al. Effects of intravenous and intracoronary 5'-triphosphate as compared with adenosine on coronary flow and pressure dynamics. *Circulation* 2000;101:318-23.
63. Wilson RF, White CW. Intracoronary papaverine: an ideal coronary vasodilator for studies of the coronary circulation in conscious humans. *Circulation* 1986;73:444-51.
64. Bartunek J, Wijns W, Heyndrickx GR, et al. Effects of dobutamine on coronary stenosis physiology and morphology: comparison with intracoronary adenosine. *Circulation* 1999;100:243-9.
65. Engler RL, Schmid SG, Pavelec RS. Leukocyte capillary plugging in myocardial ischemia and reperfusion in the dog. *Am J Pathol* 1983;111:98-111.
66. Lenzen MJ, Boersma E, Bertrand ME, et al. Management and outcome of patients with established coronary artery disease: the Euro Heart Survey on coronary revascularization. *Eur Heart J* 2005;26:1169-79.
67. Bech GJ, Droste H, Pijls NH, et al. Value of fractional flow reserve in making decisions about bypass surgery for equivocal left main coronary artery disease. *Heart* 2001;86:547-52.
68. Abizaid AS, Mintz GS, Abizaid A, et al. One-year follow-up after intravascular ultrasound assessment of moderate left main coronary artery disease in patients with ambiguous angiograms. *J Am Coll Cardiol* 1999;34:707-15.
69. Leesar MA, Masden R, Jasti V. Physiological and intravascular ultrasound assessment of an ambiguous left main coronary artery stenosis. *Catheter Cardiovasc Interv* 2004;62:349-57.
70. Jasti V, Ivan E, Yalamanchili V, Wongpraparut N, Leesar MA. Correlations between fractional flow reserve and intravascular ultrasound in patients with an ambiguous left main coronary artery stenosis. *Circulation* 2004;110:2831-6.
71. Pijls NH, De Bruyne B, Bech GJ, et al. Coronary pressure measurement to assess the hemodynamic significance of serial stenoses within one coronary artery: validation in humans. *Circulation* 2000;102:2371-7.
72. Fitzgibbon GM, Kafka HP, Leach AJ, Keon WJ, Hooper GD, Burton JR. Coronary bypass graft fate and patient outcome: angiographic follow-up of 5,065 grafts related to survival and reoperation in 1,388 patients during 25 years. *J Am Coll Cardiol* 1996;28:616-26.
73. Reeves F, Bonan R, Cote G, et al. Long-term angiographic follow-up after angioplasty of venous coronary bypass grafts. *Am Heart J* 1991;122:620-7.
74. Murphy GJ, Angelini GD. Insights into the pathogenesis of vein graft disease: lessons from intravascular ultrasound. *Cardiovasc Ultrasound* 2004;2:8.
75. Wong SC, Baim DS, Schatz RA, et al. Immediate results and late outcomes after stent implantation in saphenous vein graft lesions: the multicenter U.S. Palmaz-Schatz stent experience. The Palmaz-Schatz Stent Study Group. *J Am Coll Cardiol* 1995;26:704-12.
76. Choussat R, Black AJ, Bossi I, Joseph T, Fajadet J, Marco J. Long-term clinical outcome after endoluminal reconstruction of diffusely degenerated saphenous vein grafts with less-shortening wallstents. *J Am Coll Cardiol* 2000;36:387-94.
77. Mendelsohn FO, Foster GP, Palacios IF, et al. In vivo assessment by intravascular ultrasound of enlargement in saphenous vein bypass graft. *Am J Cardiol* 1995;76:1066-9.

78. Murphy GJ, Angelini GD. Insights into the pathogenesis of vein graft disease: lessons from intravascular ultrasound. *Cardiovasc Ultrasound* 2004;2:8–13.
79. Hong M, Mintz GS, Hong MK, et al. Intravascular ultrasound assessment of the presence of vascular remodeling in diseased human saphenous bypass grafts. *Am J Cardiol* 1999;84:992–8.
80. Salm LP, Bax JJ, Jukema JW, et al. Hemodynamic evaluation of saphenous vein coronary artery bypass grafts: relative merits of Doppler flow velocity and SPECT perfusion imaging. *J Nucl Cardiol* 2005;12:545–52.
81. George BS, Myler RK, Stertz SH, et al. Balloon angioplasty of coronary bifurcation lesions: the kissing balloon technique. *Cathet Cardiovasc Diagn* 1986;12:124–38.
82. Yamashita T, Nishida T, Adamian MG, et al. Bifurcation lesions: two stents versus one stent—immediate and follow-up results. *J Am Coll Cardiol* 2000;35:1145–51.
83. Al Suwaidi J, Berger PB, Rihal CS, et al. Immediate and long-term outcome of intracoronary stent implantation for true bifurcation lesions. *J Am Coll Cardiol* 2000;35:929–36.
84. Costa RA, Mintz GS, Carlier SG, et al. Bifurcation coronary lesions treated with the “crush” technique: an intravascular ultrasound analysis. *J Am Coll Cardiol* 2005;46:599–605.
85. Colombo A, Moses JW, Morice MC, et al. Randomized study to evaluate sirolimus-eluting stents implanted at coronary bifurcation lesions. *Circulation* 2004;109:1244–9.
86. Ziaee A, Parham WA, Herrmann SC, Stewart RE, Lim MJ, Kern MJ. Lack of relation between imaging and physiology in ostial coronary artery narrowings. *Am J Cardiol* 2004;93:1404–7.
87. Brueck M, Heidt M, Kramer W, Ludwig J. Comparison of interventional versus conservative treatment of isolated ostial lesions of coronary diagonal branch arteries. *Am J Cardiol* 2004;93:1162–4.
88. Koo BK, Kang HJ, Youn TJ, et al. Physiologic assessment of jailed side branch lesions using fractional flow reserve. *J Am Coll Cardiol* 2005;46:633–7.
89. Tamita K, Akasaka T, Takagi T, et al. Effects of microvascular dysfunction on myocardial fractional flow reserve after percutaneous coronary intervention in patients with acute myocardial infarction. *Catheter Cardiovasc Interv* 2002;57:452–9.
90. Muramatsu T, Tsukahara R, Ho M, et al. Usefulness of fractional flow reserve guidance for PCI in acute myocardial infarction. *J Invasive Cardiol* 2002;14:657–62.
91. Claeys MJ, Bosmans JM, Hendrix J, et al. Reliability of fractional flow reserve measurements in patients with associated microvascular dysfunction: importance of flow on translesional pressure gradient. *Catheter Cardiovasc Interv* 2001;54:427–34.
92. De Bruyne B, Pijls NHJ, Bartunek J, et al. Fractional flow reserve in patients with prior myocardial infarction. *Circulation* 2001;104:157–62.
93. Usui Y, Chikamori T, Yanagisawa H, et al. Reliability of pressure-derived myocardial fractional flow reserve in assessing coronary artery stenosis in patients with previous myocardial infarction. *Am J Cardiol* 2003;92:699–702.
94. Potvin JM, Rodes-Cabau J, Bertrand OF, et al. Usefulness of fractional flow reserve measurements to defer revascularization in patients with stable or unstable angina pectoris, non-ST-elevation and ST-elevation acute myocardial infarction, or atypical chest pain. *Am J Cardiol* 2006;98:289–97.
95. Legalery P, Schiele F, Seronde MF, et al. One-year outcome of patients submitted to routine fractional flow reserve assessment to determine the need for angioplasty. *Eur Heart J* 2005;26:2623–9.
96. Hernandez-Garcia MJ, Alonso-Briales JH, Jimenez-Navarro M, et al. Clinical management of patients with coronary syndromes and negative fractional flow reserve findings. *J Interv Cardiol* 2001;14:505–9.
97. Lopez-Palop R, Pinar E, Lozano I, et al. Utility of the fractional flow reserve in the evaluation of angiographically moderate in-stent restenosis. *Eur Heart J* 2004;25:2040–7.
98. Hasegawa T, Ehara S, Kobayashi Y, et al. Acute myocardial infarction: clinical characteristics and plaque morphology between expansive remodeling and constrictive remodeling by intravascular ultrasound. *Am Heart J* 2006;151:332–7.
99. von Birgelen C, Klinkhart W, Mintz GS, et al. Plaque distribution and vascular remodeling of ruptured and nonruptured coronary plaques in the same vessel: an intravascular ultrasound study in vivo. *J Am Coll Cardiol* 2001;37:1864–70.
100. Ohlmann P, Kim SW, Mintz GS, et al. Cardiovascular events in patients with coronary plaque rupture and nonsignificant stenosis. *Am J Cardiol* 2005;96:1631–5.
101. Rioufol G, Gilard M, Finet G, et al. Evolution of spontaneous atherosclerotic plaque rupture with medical therapy: long-term follow-up with intravascular ultrasound. *Circulation* 2004;110:2875–80.
102. Fujii K, Carlier SG, Mintz GS, et al. Creatine kinase-MB enzyme elevation and long-term clinical events after successful coronary stenting in lesions with ruptured plaque. *Am J Cardiol* 2005;95:355–9.
103. Klein LW, Kern MJ, Berger P, et al. Society of Cardiac Angiography and Interventions: suggested management of the no-reflow phenomenon in the cardiac catheterization laboratory. *Catheter Cardiovasc Interv* 2003;60:194–201.
104. Ito H, Okamura A, Iwakura K, et al. Myocardial perfusion patterns related to thrombolysis in myocardial infarction perfusion grades after coronary angioplasty in patients with acute anterior wall myocardial infarction. *Circulation* 1996;93:1993–9.
105. Tanaka A, Kawarabayashi T, Nishibori Y, et al. No-reflow phenomenon and lesion morphology in patients with acute myocardial infarction. *Circulation* 2002;105:2148–52.
106. Iijima R, Shinji H, Ikeda N, et al. Comparison of coronary arterial finding by intravascular ultrasound in patients with “transient no-reflow” versus “reflow” during percutaneous coronary intervention in acute coronary syndrome. *Am J Cardiol* 2006;97:29–33.
107. Lim MJ, Kern MJ. Utility of coronary physiologic hemodynamics for bifurcation, aorto-ostial, and ostial branch stenoses to guide treatment decisions. *Catheter Cardiovasc Interv* 2005;65:461–8.
108. Nishioka T, Amanullah AM, Luo H, et al. Clinical validation of intravascular ultrasound imaging for assessment of coronary stenosis severity: comparison with stress myocardial perfusion imaging. *J Am Coll Cardiol* 1999;33:1870–8.
109. Abizaid A, Mintz GS, Pichard AD, et al. Clinical, intravascular ultrasound, and quantitative angiographic determinants of the coronary flow reserve before and after percutaneous transluminal coronary angioplasty. *Am J Cardiol* 1998;82:423–8.
110. Takagi A, Tsurumi Y, Ishii Y, Suzuki K, Kawana M, Kasanuki H. Clinical potential of intravascular ultrasound for physiological assessment of coronary stenosis: relationship between quantitative ultrasound tomography and pressure-derived fractional flow reserve. *Circulation* 1999;100:250–5.
111. Briguori C, Anzuini A, Airoidi F, et al. Intravascular ultrasound criteria for the assessment of the functional significance of intermediate coronary artery stenoses and comparison with fractional flow reserve. *Am J Cardiol* 2001;87:136–41.
112. Orford JL, Lerman A, Holmes DR. Routine intravascular ultrasound guidance of percutaneous coronary intervention. *J Am Coll Cardiol* 2004;43:1335–42.
113. Fearon WF, Luna J, Samady H, et al. Fractional flow reserve compared with intravascular ultrasound guidance for optimizing stent deployment. *Circulation* 2001;104:1917–22.
114. Bech GJ, Pijls NH, de Bruyne B, et al. Usefulness of fractional flow reserve to predict clinical outcome after balloon angioplasty. *Circulation* 1999;99:883–8.