

UCLA

Proceedings of UCLA Health

Title

Sclerosing Mesenteritis

Permalink

<https://escholarship.org/uc/item/76r1d7d0>

Journal

Proceedings of UCLA Health, 21(1)

Author

Albertson, Michael J.

Publication Date

2017-11-14

CLINICAL VIGNETTE

Sclerosing Mesenteritis

Michael J. Albertson, M.D.

Case 1

The patient is a 73-year-old white male who was seen initially for complaints of GERD symptoms. He had increased regurgitation and had only a partial response to PPI therapy. Endoscopy did not reveal evidence for esophagitis, and his biopsies were negative for H. Pylori. Because of continued symptoms and non-responsiveness to PPI therapy, he was referred for a Bravo study in February 2016 with a DeMeester score of 22.2. High resolution esophageal motility revealed normal peristalsis and a lax lower esophageal sphincter. He underwent a LINX procedure in May 2016. At surgery, he was noted to have “extensive adhesions to the left upper abdominal wall, hemidiaphragm and stomach from some prior inflammatory process.” His past surgical history included an appendectomy and TURP x 3. At the time of his LINX procedure, he had associated lysis of adhesions. He did well post operatively until January 2017 when he was admitted to a community hospital for small bowel obstruction, which was treated conservatively with NG suction and IV fluids. He had two more episodes of partial bowel obstruction and was finally admitted to the UCLA Medical Center. CT enterography done elsewhere revealed “small bowel filled with voluminous contrast material with tethering of the small bowel in the left abdomen around irregular heterogeneous desmoplastic appearing mesentery.”

He was taken to the operating room and found to have “Matted mesentery in the left middle abdomen completely sucking in 60 cm of jejunum, matting this together and creating an obstructive process. This additionally tethered down the fourth portion of the duodenum and the first portion of the jejunum, sucking this into this desmoplastic reaction. No discrete mass was noted, but a very firm root of the mesentery was identified, suspicious for mesenteric sclerosis. The stomach was otherwise normal in appearance. The colon was normal in appearance.” The mesentery was completely transected below the mesenteric mass and involved small bowel was resected.

Pathology on the resected specimen revealed a normal fourth portion of the duodenum adjacent to the resected mesenteric mass, 37.5 cm of resected Small bowel and mesentery demonstrated mesenteric fibrosis with very little inflammation. There were 14 benign lymph nodes.

Case 2

The patient is a 65-year-old white male who presented initially in 2009 for a screening colonoscopy. The exam revealed a large polyp in the hepatic flexure that was felt to be too large to remove via standard colonoscopy. He was scheduled for a laparoscopic assisted polyp resection in August 2009 at which time the polyp was successfully removed. It was a tubulovillous adenoma without dysplasia. The peritoneal cavity appeared normal and the patient recovered uneventfully.

In 2013, he was seen in GI clinic with upper abdominal pain and some minor heartburn. Because of persistent abdominal pain despite empiric treatment for diverticulitis, the patient had a CT scan demonstrating dense mesenteric fat stranding and prominent sub-centimeter lymph nodes involving the left mesentery. This was felt to be consistent with sclerosing mesenteritis. The patient had intermittent pain over the next year. Repeat CT scan in November 2014 described hazy stranding involving the central small bowel mesentery with scattered sub-centimeter lymph nodes. He was seen again in 2015 with persistent abdominal pain. Exam revealed no abdominal masses and he was given PPI therapy.

Sclerosing mesenteritis has been described under many names including mesenteric panniculitis, mesenteric lipodystrophy, Retractable mesenteritis, Mesenteric Weber-Christian Disease, Xanthogranulomatous mesenteritis, Liposclerotic mesenteritis, inflammatory Pseudotumor, Isolated Lipodystrophy, and Retroperitoneal Xanthogranulomatoma.

It was described by Weber as Relapsing Nonsuppurative Nodular Panniculitis in 1925.¹ In 1959 Ogden, Bradburn and Rives described Panniculitis of the Mesentery in six men and one woman.² Symptoms were characterized by recurring episodes of moderate to severe abdominal pain with intermittent nausea and low grade fever. There were palpable tender abdominal masses in four out of the seven.

Pathologically, the mesentery was markedly thickened with adherent peritoneum to the mesenteric mass. There was moderate infiltration of the fat by macrophages. There was a pathologic similarity to the findings in Weber-Christian Disease.³

In 1964 the same group published an additional 17 cases with the same presenting symptoms and the same pathologic

findings.⁴ They noted that in two of the original seven patients lymphoma developed.

In 1997, Emory et al⁵ presented 84 cases reviewed with various names attached to them but all had similar pathologic features of fibrosis, inflammation, fat necrosis, and diffuse mesenteric thickening. They felt that all of these cases represented the same entity under the umbrella of mesenteric sclerosis.

Akram et al⁶ presented a retrospective and prospective study to describe the clinical characteristics, therapy, and outcome of cases of sclerosing mesenteritis at the Mayo Clinic, Rochester from 1982-2005.

The epidemiology of Sclerosing Mesenteritis is unknown. The autopsy prevalence is about 0.6%. Most patients are men in their 60's. Possible inciting factors include previous abdominal surgery or trauma, 41% and 5% respectively, and most commonly cholecystectomy, appendectomy, hysterectomy, and colectomy. It has also been reported in association with autoimmune conditions such as Thyroiditis, primary sclerosing cholangitis, retroperitoneal fibrosis, and orbital pseudotumor. It may exist as part of a paraneoplastic syndrome in lymphoma, breast cancer, melanoma, lung cancer, renal cell CA, HCC, prostate cancer, ovarian and endometrial carcinoma, and GI carcinomas.

Physical examination may reveal a mass. Lab findings may be normal.

CT scan is the most sensitive test for diagnosis. The most common finding is a soft tissue mass in the small bowel mesentery. Specifically the "fat ring sign" and a "tumor pseudocapsule" can be diagnostic. Vascular displacement, encasement or thrombosis may be present. Calcifications from fat necrosis is seen in 20% of lesions.

Most of the time sclerosing mesenteritis will present a benign, stable, or slowly progressive course although complications such as bowel obstruction and late development of malignancy have been described.

Treatment of mechanical bowel obstruction is surgery. Medical treatment has not had an extensive experience. A course of Prednisone 40 mg/day coupled with Tamoxifen 10 mg/day for six months has shown some promise with steroid taper after three months. Tamoxifen may be effective as an inhibitor of fibroblast TGF-beta 1 production. This may reduce inflammation and might have a growth-modulating effect on neighboring cells. The optimal duration of Tamoxifen therapy in Sclerosing Mesenteritis is not known. The median duration of therapy was 20 months. Other medications that have been tried include Colchicine, Cyclophosphamide and Thalidomide. More studies need to be done to determine the ideal treatment regimen in symptomatic patients.

These two cases represent the extremes in progression of Sclerosing Mesenteritis. In many cases, the symptoms abate and the patient remains asymptomatic or has recurrent episodes of minor abdominal pain. In the other extreme, the syndrome

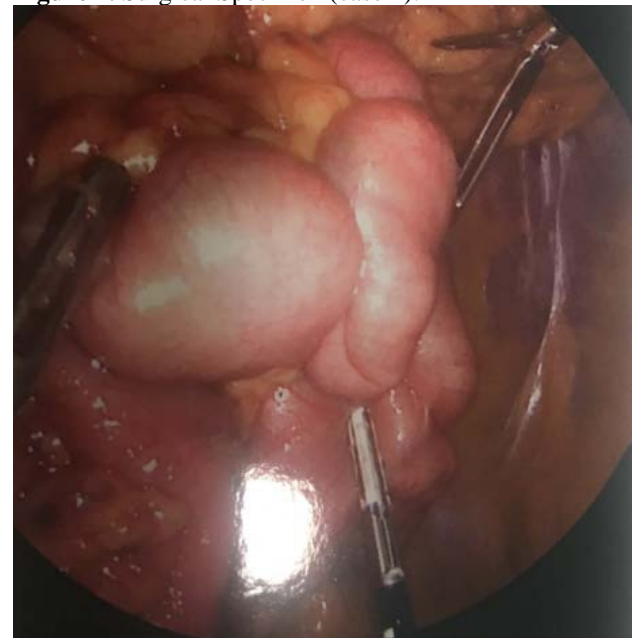
may result in obstruction necessitating surgery. Medical therapy has shown some promising results but further trials are necessary

Figures

Figure 1. Tethering of the small bowel (case 1).

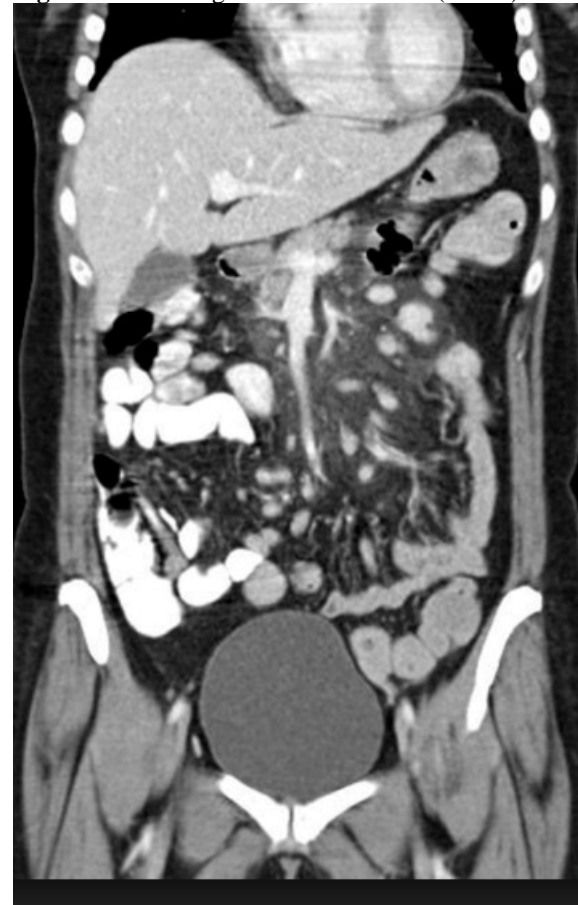

Figure 2. Surgical Specimen (case 1).



REFERENCES

1. **Weber FP.** A case of relapsing nonsuppurative nodular panniculitis, showing phagocytosis of subcutaneous fat cells by macrophages. *Brit J Dermat* 1925; 37:301-311.
2. **Ogden WW 2nd, Bradburn DM, Rives JD.** Panniculitis of the mesentery. *Ann Surg.* 1960 May;151:659-68. PubMed PMID: 14428409; PubMed Central PMCID: PMC1613701.
3. **Christian HA.** Relapsing febrile nodular nonsuppurative panniculitis. *Arch Int Med* 1928; 42:338-351.
4. **Ogden WW 2nd, Bradburn DM, Rives JD.** Mesenteric panniculitis: Review of 27 cases. *Ann Surg.* 1965 Jun;161:864-75. PubMed PMID: 14295938; PubMed Central PMCID: PMC1409094.
5. **Emory TS, Monihan JM, Carr NJ, Sobin LH.** Sclerosing mesenteritis, mesenteric panniculitis and mesenteric lipodystrophy: a single entity? *Am J Surg Pathol.* 1997 Apr;21(4):392-8. PubMed PMID: 9130985.
6. **Akram S, Pardi DS, Schaffner JA, Smyrk TC.** Sclerosing mesenteritis: clinical features, treatment, and outcome in ninety-two patients. *Clin Gastroenterol Hepatol.* 2007 May;5(5):589-96; quiz 523-4. PubMed PMID: 17478346.

Submitted November 14, 2017