

UCLA

UCLA Previously Published Works

Title

Magnetic Resonance Imaging of the Shoulder

Permalink

<https://escholarship.org/uc/item/76q3p1qf>

Journal

Rheumatic Disease Clinics of North America, 17(3)

ISSN

0889-857X

Authors

Seeger, Leanne L
Gambhir, Sangeeta
Bassett, Lawrence W

Publication Date

1991-08-01

DOI

10.1016/s0889-857x(21)00113-7

Peer reviewed

Magnetic Resonance Imaging of the Shoulder

Leanne L. Seeger, MD,* Sangeeta Gambhir, MD,† and
Lawrence W. Bassett, MD‡

Partly because of the popularity of physical fitness and sports activities, disorders of the shoulder joint are encountered more frequently in general and subspecialty medical practices. In fact, a painful shoulder is now the third most common general medical complaint.⁵ Magnetic resonance imaging (MRI) is proving to be an effective means of evaluating two major categories of shoulder derangements: shoulder impingement and glenohumeral instability. In this article, we describe the role of MRI in assessing these conditions, as well as the current status of its delineation of synovial pathology.

TECHNICAL CONSIDERATIONS

Several technical difficulties are encountered in MR imaging of the shoulder. Magnetic resonance evaluation of most shoulder disorders requires the imaging of relatively small soft-tissue structures. Moreover, the shoulder lies in the periphery of the magnetic field in which the signal-to-noise ratio is inherently low. This results in unsharp or blurry images. Simply magnifying images obtained with the magnet's built-in "body" coil gives bigger pictures but does not increase signal-to-noise ratio. Magnetic resonance examinations capable of demonstrating small soft-tissue structures in the shoulder require high-resolution scanning techniques and the use of a surface coil. Surface coils are small radiofrequency receivers that are wrapped around or placed on the shoulder. Surface coils increase image resolution by excluding signals from tissues outside the region of the shoulder coil.

Magnetic resonance scanning should not be performed within 2 weeks of

From the Department of Radiological Sciences, UCLA School of Medicine, Los Angeles, California

* Assistant Professor and Chief, Musculoskeletal Radiology

† Research Assistant

‡ Professor

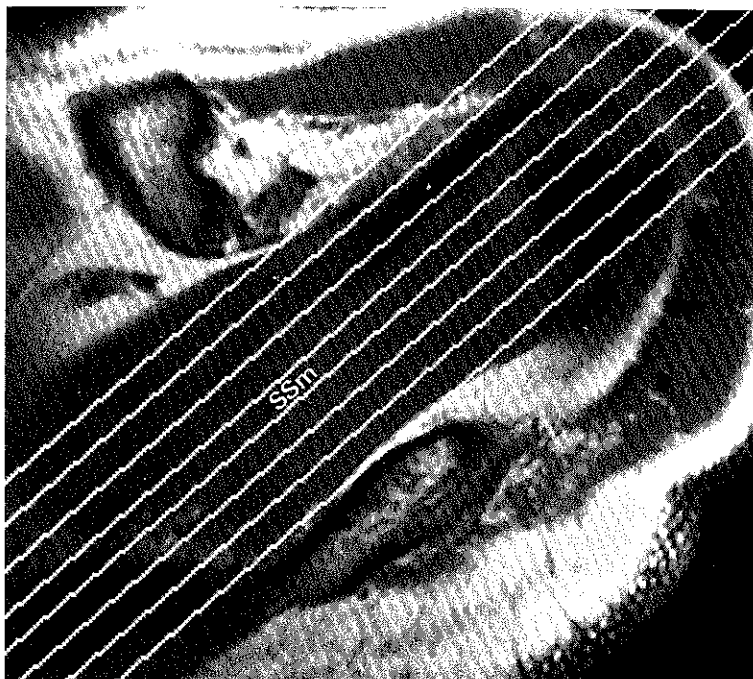


Figure 1. High axial image at the level of supraspinatus muscle (SSm). SE 600/18. Anterior is at the top of the image, and lateral is to the right. Cursors are aligned for frontal oblique imaging.

arthrography or corticosteroid injections. These invasive procedures may produce soft-tissue changes to which MRI is extremely sensitive. The resulting altered signal characteristics have the potential of leading to false-positive diagnoses.

Because MRI is insensitive to small foci of soft-tissue calcification, calcific tendinitis and calcific bursitis may not be evident in MR images. Radiographs remain the best imaging technique for these disorders. Whenever radiographs are available, the radiologist responsible for supervising the MR image acquisition and its interpretation should have access to them. This is especially true when soft-tissue calcification is known to be present or is suspected.

SHOULDER IMPINGEMENT SYNDROME/ROTATOR CUFF TEARS

Classic shoulder impingement syndrome refers to entrapment of the supraspinatus tendon and subacromial bursa between the humeral head and the structures of the coracoacromial arc (the distal clavicle, acromioclavicular joint, anterior acromion, and coracoacromial ligament).^{8,13,14,16} Clinically, impingement is characterized by severe pain during abduction and external rotation or during elevation and internal rotation of the arm. This disorder is most often caused by repetitive trauma related to vigorous overhead occupational or athletic endeavors or to degenerative osteophytes.^{6,13,14,16} Predisposing factors may include

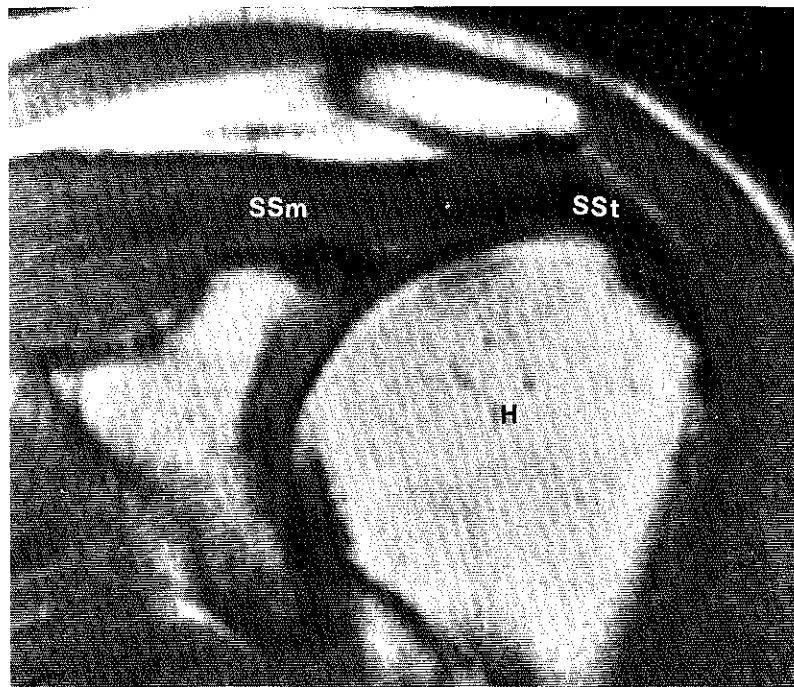


Figure 2. Normal shoulder, frontal oblique plane. SE 500/30. The subacromial bursa is not evident. H = humeral head. SSm = supraspinatus muscle. SSt = supraspinatus tendon.

acromioclavicular joint capsule hypertrophy, bony spurs arising from the acromioclavicular joint or the inferior aspect of the anterior acromion, or a low-lying or large anterior acromion.^{2,13,14} Any of these structures can encroach on the anatomic space in which the supraspinatus tendon and subacromial bursa function.

Magnetic resonance imaging provides the first noninvasive means for evaluating all soft-tissue abnormalities associated with impingement syndrome.^{10,11,20} Frontal oblique imaging is the preferred view for evaluating impingement because it provides visualization of the supraspinatus muscle and tendon in continuity and readily demonstrates the relation of the subacromial bursa and supraspinatus tendon to the osseous structures directly above. Alignment for frontal-oblique scanning is determined from a high axial image that shows the supraspinatus muscle (Fig. 1).²¹ Cursors aligned along the long axis of this muscle yield images that are oblique along a coronal-to-sagittal plane (Fig. 2).

On T1-weighted images, the normal supraspinatus tendon is a low-signal intensity structure (black). With the arm in internal rotation, the musculotendinous junction is located beneath the acromioclavicular joint. The subacromial bursa is parallel and superior to the supraspinatus musculotendinous unit. Because the bursa is thin, it may not be seen in MR images of a normal shoulder. If visible, it is imaged as a very thin band of high-signal intensity in both T1- and T2-weighted images. The high signal is felt to represent fat, corresponding to the adipose or areolar tissue found within and beneath the synovium.^{3,7,12,23}

When impingement is present, MRI usually can provide information regarding the offending structures above the bursa and tendon. This can assist in

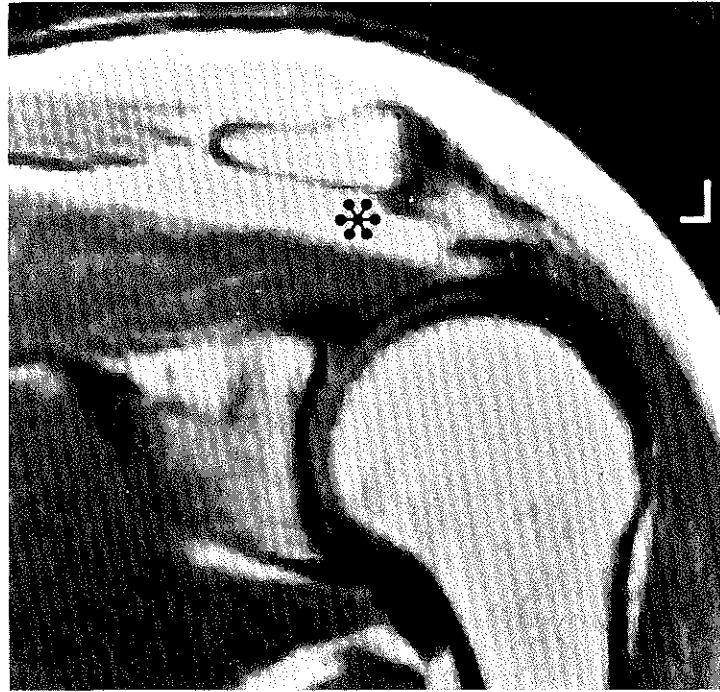


Figure 3. Subacromial bursitis. SE 800/30. There is marked thickening of the subacromial bursal fat (asterisk). This represents a hypertrophic synovitis.

surgical and therapeutic planning. Small spurs off the anterior acromion or acromioclavicular joint are imaged as regions of signal void. Larger spurs, which generally contain marrow, are seen as extensions of the high-signal intensity from the parent bone surrounded by a cortical signal void. Hypertrophy of the acromioclavicular joint capsule appears as a rounded mass of intermediate-signal intensity surrounding the joint. In T2-weighted images, fluid within the acromioclavicular joint appears as a focus of high-intensity signal. Degenerative changes of the acromioclavicular joint lead to irregularity of the normally sharp, smooth margins of the opposing cortical surfaces, with an intervening band of intermediate-signal intensity.

Shoulder impingement encompasses a spectrum of clinical entities: subacromial bursitis, supraspinatus tendinitis and fibrosis, and rotator cuff tears.⁴ Although these soft-tissue abnormalities are seen commonly in clinical practice, it is unclear whether they represent a spectrum of disease or if they are independent processes. Differentiating among these entities becomes important when determining the need for surgical or conservative therapy.

Subacromial bursitis manifests in MR images as focal or generalized thickening of the high-intensity signal of the bursa (Fig. 3). Because this process represents a hypertrophic synovitis (increased fat), the high-signal intensity generally is present in both T1- and T2-weighted images. At the level of impingement, the bursa may be depressed. Uncommonly, excessive fluid may be present within the subacromial-subdeltoid bursa. If present, bursal fluid displays low- to interme-

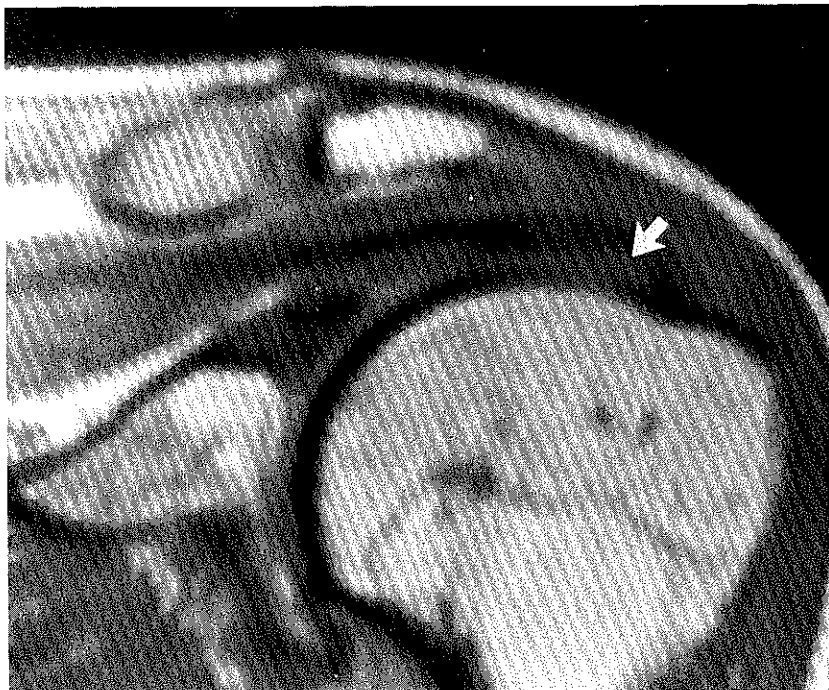

Figure 4. Supraspinatus tendinitis. SE 600/20. There is abnormal intermediate signal intensity in the normally black tendon (*arrow*).

diate-signal intensity in T1-weighted images and very high signal intensity (white) with T2 weighting.

With supraspinatus tendinitis, intermediate-signal intensity replaces the normal void of the supraspinatus tendon in T1-weighted images (Fig. 4). The increase in signal is thought to represent increased water within the tendon from edema, hemorrhage, or inflammation. With T2-weighted imaging, the signal either remains intermediate or decreases in intensity. The supraspinatus musculotendinous junction retains its normal position beneath acromioclavicular joint, and the bulk and signal intensity of the supraspinatus muscle remain normal.

Small- or medium-sized tears of the supraspinatus tendon usually cannot be differentiated from tendinitis in T1-weighted images. With T2-weighted imaging, however, a tear will appear as a well-defined focus of high-signal intensity fluid within the tendon (Fig. 5). In cases of small- to moderate-sized tears, no retraction of the musculotendinous junction occurs. Because these small tears often are within the distal portion of the tendon near its insertion on the greater tuberosity, they usually are best seen in extreme anterior images in the frontal-oblique plane.

With a massive rotator cuff tear, the supraspinatus muscle retracts medially, and fluid replaces the space normally occupied by the tendon. In cases of extensive and long-standing rotator cuff disruption, muscular atrophy may be evident. The presence of severe atrophy may assist in determining whether surgical intervention is warranted. Atrophy manifests by high-signal intensity within the muscle in T1-weighted images, indicating fatty replacement of muscle fibers. The

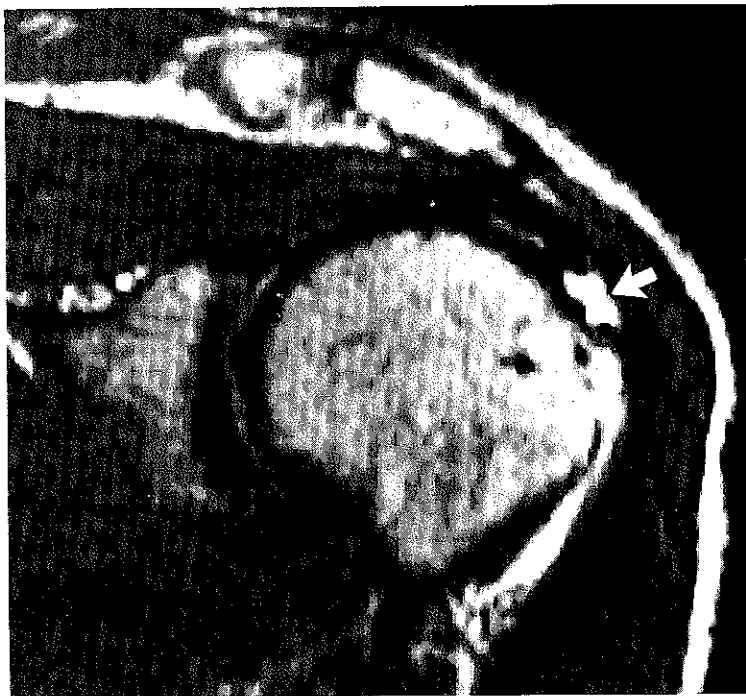


Figure 5. Supraspinatus tendon tear. T2-weighted image (SE 2000/80). The high signal intensity at the tendon insertion represents fluid (arrow).

overall mass of the muscle also is diminished in cases of atrophy. Both findings must be evaluated in light of the overall muscular development of each patient.

With chronic tears of the supraspinatus tendon, the subacromial bursa and supraspinatus tendon may be replaced gradually by fibrovascular granulation tissue. Eventually, even this tissue will be obliterated by the superiorly migrating humeral head. In this setting, the MRI will show marked narrowing of the acromiohumeral space. This finding may not be evident in routine shoulder radiographs, because they often are obtained with the patient in an upright position, with gravity displacing the humeral head inferiorly.

Magnetic resonance imaging has shown tears of the rotator cuff that later were confirmed surgically in patients who had negative arthrograms.¹¹ Theoretically, this situation could represent cases in which bursa or fibrotic tissue covers or fills the tear, preventing the contrast media injected into the joint from entering the tear in the tendon.

SHOULDER INSTABILITY

The glenohumeral joint is the most mobile joint in the body.¹⁷ This is partly because only a small portion of the humeral head is in contact with the bony glenoid at any given time. Unfortunately, this extreme mobility also leads to inherent instability in the glenohumeral joint. Shoulder instability, in the form of subluxation or dislocation, is a common cause of chronic pain and disability.

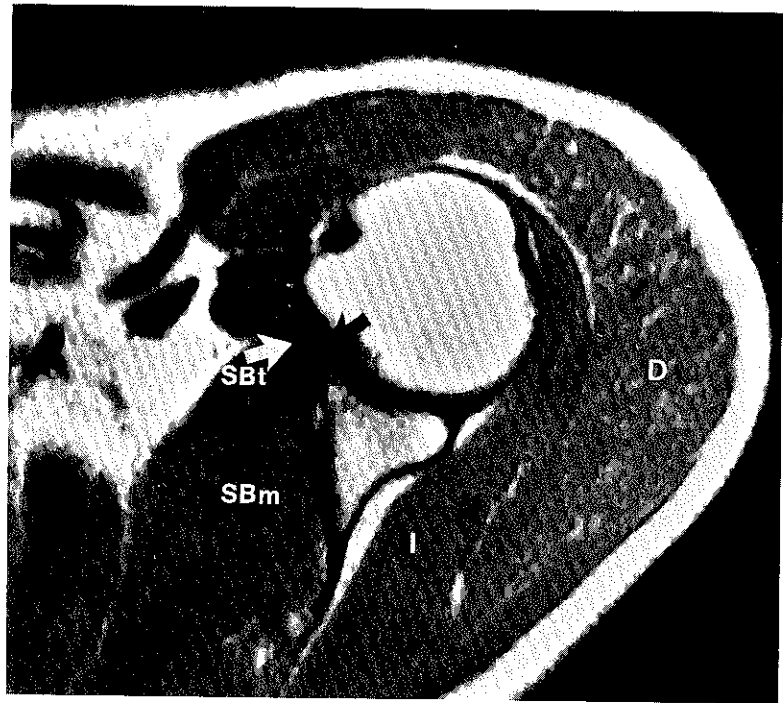


Figure 6. Normal axial image, mid humeral head. SE 500/30. The anterior labrum is evident as a homogenous black triangle (*black arrow*). SBt = subscapularis tendon; SBm = subscapularis muscle; D = deltoid muscle; I = infraspinatus muscle.

Because of the inherent ability of MRI to depict the soft tissues without the injection of intraarticular contrast material, it is well suited to the evaluation of abnormalities secondary to glenohumeral dislocation or subluxation.^{9,19}

Although persistent glenohumeral instability may follow a traumatic dislocation, many patients who have instability cannot recall a specific traumatic episode. In patients who have subclinical instability or an injury that cannot be attributed to trauma, the initial complaints may be vague. Nonspecific symptoms such as arm numbness, decreased range of motion, and nonspecific pain often make the diagnosis challenging.¹⁸ There also are patients in whom subluxation is multidirectional.¹⁵ If only the anterior lesion is repaired, these patients will experience continuing pain and disability because of what will have become a fixed, unidirectional posterior instability.

The cause of nontraumatic instability has long been debated, but it is thought to be related to a deficiency in the soft-tissue support of the joint.¹² Normally, the so-called "capsular mechanism" is believed to provide the major stability. The capsular mechanism consists of the anterior and posterior rotator cuff muscles and tendons, the joint capsule and synovial membrane, the glenohumeral ligaments, and the fibrous glenoid labrum.

Several soft-tissue abnormalities are associated with an unstable shoulder. For example, the glenoid labrum may become torn or detached from the bony glenoid. In recurrent subluxation or dislocation, the labrum may become severely attenuated. In traumatic dislocations, the joint capsule may be separated

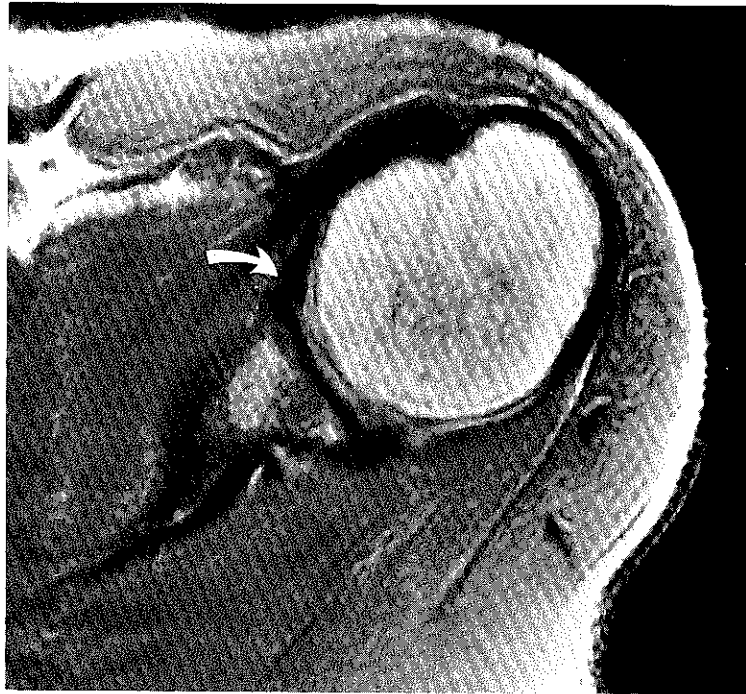


Figure 7. Anterior labrum tear. SE 2000/20. The band of intermediate signal crossing the labrum indicates a tear (arrow).

from the scapula. There also may be trauma to the rotator cuff muscles or tendons. Fractures associated with dislocation include the Hill-Sachs deformity (depressed fracture of the posterolateral humeral head) and Bankart fractures (fractures of the rim of the bony glenoid).

The anterior and posterior glenoid labra are believed to represent redundant folds of the fibrous joint capsule¹² and therefore are normally imaged as a signal void (Fig. 6). Because the labrum is pliable, its shape is determined by the position of the humeral head.¹² With the arm rotated internally, the larger anterior labrum becomes pointed, and the smaller posterior labrum is more rounded. A thin rim of intermediate- to high-signal intensity separates the labrum from the surrounding cuff tendons and joint capsule. This probably represents redundant fat-laden folds of synovium. This redundant synovium is necessary for the extreme mobility of the shoulder.^{3,4,23}

A labral tear is evident as increased signal intensity within the normal signal void of the labrum (Fig. 7). Labral abnormalities may be seen anteriorly as well as posteriorly in images of patients who have multidirectional instability. In instances of capsular tear, fluid will be seen dissecting along the anterior border of the scapula or into the subscapularis musculotendinous unit. Patients who have significant trauma to the subscapularis tendon may show medial retraction of the subscapularis musculotendinous junction, indicating tendon rupture. Disproportionate atrophy of the subscapularis muscle compared to the adjacent muscles often indicates remote or chronic instability (Fig. 8).

It should be kept in mind that the presence of a labral tear does not imply

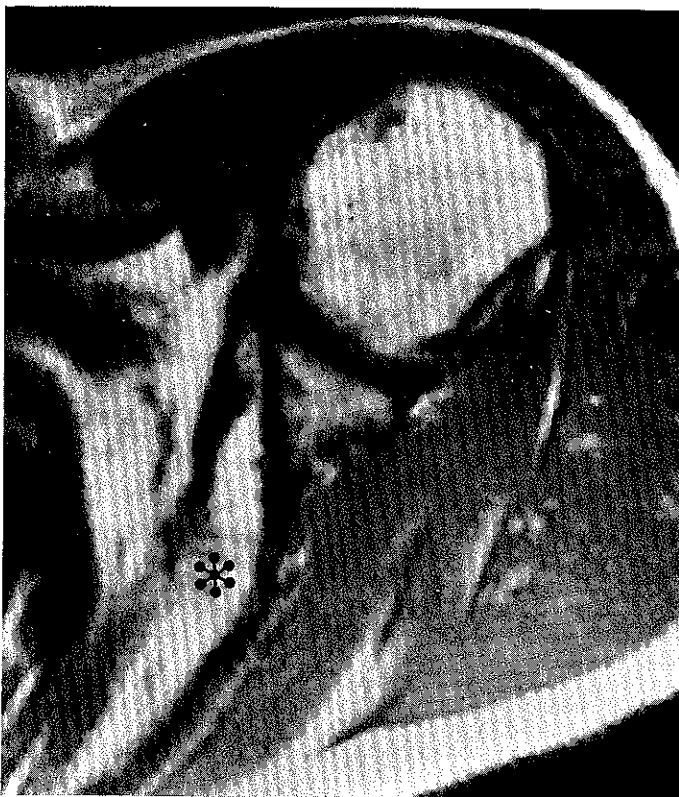


Figure 8. Remote subscapularis tendon tear. SE 1800/20. The subscapularis muscle is completely replaced with high signal intensity (*asterisk*), representing fatty atrophy. There was a history of traumatic anterior dislocation several years previously.

that the patient has an unstable shoulder. This finding should raise the suspicion, however, of an underlying structural or mechanical problem.

Bony trauma, including frank fractures, are identified easily in MR images. Trabecular disruption, marrow edema, and bleeding associated with trauma appear as regions of abnormal intermediate-signal intensity within the normally high-signal intensity bone marrow. In the acute period, this becomes very high signal intensity with T2-weighted imaging. Poorly defined foci that remain low-signal intensity in T2-weighted images usually are associated with remote trauma.

Hill-Sachs lesions are depicted on MR images as focal depressions in the contour of the humeral head at or above the level of the coracoid process. Care must be taken not to mistake the normal posterolateral flattening of the more inferior humeral head for a Hill-Sachs deformity. Bankart fractures are evidenced by areas of abnormal signal intensity within the bone marrow of the glenoid rim.

SYNOVIAL PATHOLOGY

Little has been mentioned in the literature about the use of MRI in evaluating synovial pathology, especially in the shoulder. The early work that has been reported mostly concerns rheumatoid arthritis (RA).^{1,22,24}

Roentgenographic manifestations of RA include bone erosions, joint space narrowing, and osteoporosis. Magnetic resonance imaging has been found to be more sensitive than radiographs for the early detection of bone erosions, the detection of minimal joint effusions, and evaluation of the extent of hyaline and fibrous cartilage damage. Magnetic resonance imaging is expensive, however, and time consuming. If this procedure has a future role in the evaluation of patients who have RA, then it probably will be for the assessment of response to therapy. Currently, the diagnosis of RA is accomplished more efficiently and accurately by using laboratory and clinical parameters.

REFERENCES

1. Beltran J, Caudill JL, Herman LA, et al: Rheumatoid arthritis: MR imaging manifestations. *Radiology* 165:153, 1987
2. Bigliani LU, Morrison DS, April EW: The morphology of the acromion and its relationship to rotator cuff tears (abstract). *Orthop Trans* 10:216, 1986
3. Bloom W, Fawcett DW: *A Textbook of Histology*, ed 9. Philadelphia, Saunders, 1968, pp 255-260
4. Boileau Grant JC: Interarticular synovial folds. *Br J Surg* 18:636, 1931
5. Bonafede RP, Bennett RM: Shoulder pain: Guidelines to diagnosis and management. *Postgrad Med* 82:185, 1987
6. Cone RO, III, Resnick D, Danzig L: Shoulder impingement syndrome: Radiographic evaluation. *Radiology* 150:29, 1984
7. Ham AW, Cormack DH: *Histology*, ed 8. Philadelphia, J.B. Lippincott, 1979, pp 474-477
8. Hawkins RJ, Kennedy JC: Impingement syndrome in athletes. *Am J Sports Med* 8:151, 1980
9. Kieft CJ, Bloem JL, Rozing PM, et al: MR imaging of recurrent anterior dislocation of the shoulder: Comparison with CT arthrography. *AJR* 150:1083, 1988
10. Kieft CJ, Bloem JL, Rozing PM, et al: Rotator cuff impingement syndrome: MR imaging. *Radiology* 166:211, 1988
11. Kneeland JB, Middleton WD, Carrera GF, et al: MR imaging of the shoulder: Diagnosis of rotator cuff tears. *AJR* 149:333, 1987
12. Mosley HF, Overgaard B: The anterior capsular mechanism in recurrent anterior dislocation of the shoulder: Morphological and clinical studies with special reference to the glenoid labrum and the gleno-humeral ligaments. *J Bone Joint Surg* 44B:913, 1962
13. Neer CS II: Anterior acromioplasty for the chronic impingement syndrome in the shoulder. *J Bone Joint Surg* 54A:41, 1972
14. Neer CS II: Impingement lesions. *Clin Orthop* 173:70, 1983
15. Neer CS II, Foster CR: Inferior capsular shift for involuntary and multidirectional instability of the shoulder. *J Bone Joint Surg* 62A:897, 1980
16. Penny JN, Welsh MB: Shoulder impingement syndromes in athletes and their surgical management. *Am J Sports Med* 9:11, 1981
17. Rothman RH, Marvel JP Jr, Heppenstall RB: Recurrent anterior dislocation of the shoulder. *Orthop Clin North Am* 6:415, 1975
18. Rowe CR, Zarins B: Recurrent transient subluxation of the shoulder. *J Bone Joint Surg* 62A:863, 1981
19. Seeger LL, Gold RH, Bassett LW: MR imaging of shoulder instability. *Radiology* 168:695, 1988

20. Seeger LL, Gold RH, Bassett LW, et al: Shoulder impingement syndrome: MR findings in 53 shoulders. *AJR* 150:343, 1988
21. Seeger LL, Ruszkowski JT, Bassett LW, et al: MR imaging of the normal shoulder: Anatomic correlation. *AJR* 148:83, 1987
22. Senac MO Jr, Deutsch D, Bernstein BH, et al: MR imaging in juvenile rheumatoid arthritis. *AJR* 150:873, 1988
23. Williams PL, Warwick R (eds): *Gray's Anatomy*, ed 36. Philadelphia, Saunders, 1980, pp 425-428, 489
24. Yulish BS, Lieberman JM, Newman AJ, et al: Juvenile rheumatoid arthritis: Assessment with MR imaging. *Radiology* 165:149, 1987

Address reprint requests to

Leanne L. Seeger, MD
Department of Radiological Sciences
UCLA School of Medicine
200 UCLA Medical Plaza, Suite 165-59
Los Angeles, CA 90024-6952