

UCLA

Proceedings of UCLA Health

Title

Ultrasound Diagnosis of Achilles Tendon Rupture

Permalink

<https://escholarship.org/uc/item/75z1p81q>

Journal

Proceedings of UCLA Health, 22(1)

Authors

Basrai, Zahir

Celedon, Manuel

Publication Date

2018-07-23

CLINICAL VIGNETTE

Ultrasound Diagnosis of Achilles Tendon Rupture

Zahir Basrai, MD and Manuel Celedon, MD

History

A 28-year-old male with no past medical history presented to the emergency department with acute left ankle pain. The patient reported that he was playing basketball and while jumping he felt a “pop” in his left ankle. He reported significant pain over his left posterior ankle. After falling, he was unable to walk or bear weight on his left foot. His pain was reproducible with attempted weight bearing of his left lower extremity.

Physical Exam

His vital signs were unremarkable. On gross examination of the left lower extremity, there was a defect in the distal one-third of his Achilles tendon. There was no evidence of skin breaks, abrasions, erythema, or warmth. He was unable to plantarflex. A positive Thompson test was elicited. The neurovascular status of left lower extremity and remainder of examination was unremarkable.

Imaging

An x-ray of the left ankle was performed and was read as negative for fracture or dislocation.

A point-of-care ultrasound of the left Achilles tendon was performed using a 13-6 MHz linear array transducer. In the longitudinal view there was a disruption of the fibrillary appearance of the tendon which was suggestive of an Achilles tendon rupture (Figure 1).

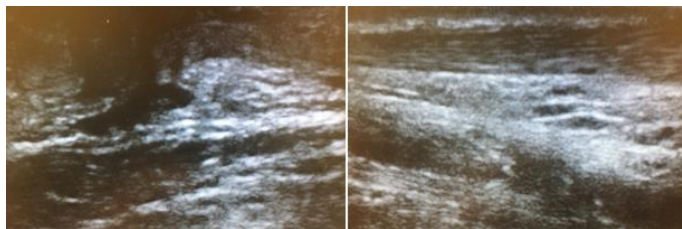


Figure 1: Left image: In the upper ¼ of the screen there is evidence of intact fibers consistent with a normal Achilles tendon. Right image: The fibers in the upper ¼ of the image are disrupted with an associated hypoechoic area. This is consistent with an Achilles tendon rupture with associated hematoma.

Given the history, physical, and ultrasound examination findings the patient was diagnosed with an Achilles tendon rupture.

He was placed in a short leg posterior splint with the ankle in slight plantar flexion. He was discharged home with urgent outpatient orthopedic surgery follow up.

Discussion

Achilles tendon ruptures represent 1/5 of all large tendon injuries.¹ Historically considered an injury of youth, we are now seeing a bimodal age distribution with a second peak in patients older than 60 years.² A surge in the active senior population accounts for the increase in the incidence of Achilles tendon ruptures in those over 60 years. Pathologic changes such as calcification, hypoxic degenerative tendinopathy, lipomatous or mucoid degeneration make the Achilles tendon susceptible to rupture during activities of daily living.³

The Achilles tendon is the strongest tendon in the body, emanating from the gastrocnemius and soleus muscles and inserting into the posterior aspect of the calcaneus.⁴ Achilles tendon rupture is a sport related or repetitive overuse injury frequently seen in athletes performing jumping or running activities that suddenly increase stress on the tendon.⁵ The mechanism of injury typically involves the violent or unexpected dorsiflexion of a plantar-flexed ankle. Pushing off on a weight-bearing foot with the knee extended is another common mechanism of rupture.⁶

The area 3-6cm proximal to where the Achilles tendon inserts into the calcaneal tuberosity is hypovascular and has a small cross-sectional area making it susceptible to tear when exposed to large eccentric forces.⁴ Patients will often describe feeling a popping sensation at the time of rupture and will usually report inability or difficulty bearing weight. On exam, plantarflexion will be weakened compared to the contralateral side. Special exam maneuvers include the Thompson test, which is performed by squeezing the calf and watching for plantarflexion of the foot. The Thompson test is considered positive when there is no plantarflexion of the foot during compression of the calf which suggests Achilles tendon rupture.

On initial assessment, the physical exam is often limited by pain and swelling leading to a missed diagnosis.⁶ Per the American Academy of Orthopedic Surgeons (AAOS) Clinical Practice Guidelines, the diagnosis of Achilles tendon rupture can be made with 2 or more of the following physical examination findings: positive Thompson test, decreased plantarflexion

strength, palpable defect roughly 2 to 6 cm proximal to the insertion, and increased passive ankle dorsiflexion.⁷

Ultrasound is increasingly utilized as a rapid non-invasive adjunct in the diagnosis of Achilles tendon rupture. Current literature suggests that ultrasound has a sensitivity of 96-100% and specificity of 83-100% for diagnosing Achilles tendon rupture.^{6,8} The scan is relatively simple and may be performed as a point-of-care bedside exam. Prior to scanning, the patient is placed in the prone position with the patient's feet suspended over the bed in order to ensure maximal comfort while keeping anatomical alignment. The Achilles tendon is a superficial structure; therefore, the high-frequency linear array transducer is utilized to provide higher resolution images. Both ankles should be scanned, starting with the uninjured Achilles tendon to provide a baseline frame of reference.

The ultrasound of a complete Achilles tendon rupture will reveal total disruption of the normal pattern of parallel fibers in the long axis. Other associated sonographic findings include a hypoechoic area suggestive of hematoma formation or a posterior acoustic shadow at the margins of the rupture.⁶

Partial tears may be differentiated from full thickness tears by using dynamic sonography. In a full thickness tear, one end of the tendon will move away from the opposite end of the tendon during plantar and dorsiflexion of the ankle. If there is continuous movement of the tendon during dynamic sonography, it is suggestive of a partial rupture with some intact fibers.⁴

According to the AAOS Clinical Practice Guidelines, both non-operative and operative treatments are acceptable options for patients with an acute Achilles tendon rupture.⁷ Operative management of the tendon rupture may result in a stronger tendon with improved endurance during sport activities. Operative management is recommended for athletes of all levels in an attempt to maximally restore the patient's prior level of activity.⁹ Non-operative management of Achilles tendon ruptures consist of non-weight-bearing cast immobilization at a plantarflexion angle of 28 degrees for 4 weeks followed by another 4 weeks of a weight-bearing cast at neutral position. Surgical management involves reattachment of the tendon via open, limited-open, or percutaneous repair. The complications of surgical repair include sural nerve injury, wound healing issues, and deep space infections.

REFERENCES

1. **Gillies H, Chalmers J.** The management of fresh ruptures of the tendo achillis. *J Bone Joint Surg Am.* 1970 Mar;52(2):337-43. PubMed PMID: 5440011.
2. **Makhdom AM, Cota A, Saran N, Chaytor R.** Incidence of symptomatic deep venous thrombosis after Achilles tendon rupture. *J Foot Ankle Surg.* 2013 Sep-Oct;52(5):584-7. doi: 10.1053/j.jfas.2013.03.001. Epub 2013 Apr 24. PubMed PMID: 23623625.

3. **Kannus P, Józsa L.** Histopathological changes preceding spontaneous rupture of a tendon. A controlled study of 891 patients. *J Bone Joint Surg Am.* 1991 Dec;73(10):1507-25. PubMed PMID: 1748700.
4. **Adhikari S, Marx J, Crum T.** Point-of-care ultrasound diagnosis of acute Achilles tendon rupture in the ED. *Am J Emerg Med.* 2012 May;30(4):634.e3-4. doi: 10.1016/j.ajem.2011.01.029. Epub 2011 Mar 15. PubMed PMID: 21406322.
5. **Järvinen TA, Kannus P, Paavola M, Järvinen TL, Józsa L, Järvinen M.** Achilles tendon injuries. *Curr Opin Rheumatol.* 2001 Mar;13(2):150-5. Review. PubMed PMID: 11224740.
6. **Hartgerink P, Fessell DP, Jacobson JA, van Holsbeeck MT.** Full- versus partial-thickness Achilles tendon tears: sonographic accuracy and characterization in 26 cases with surgical correlation. *Radiology.* 2001 Aug;220(2):406-12. PubMed PMID: 11477244.
7. **Chiodo CP, Glazebrook M, Bluman EM, Cohen BE, Femino JE, Giza E, Watters WC 3rd, Goldberg MJ, Keith M, Haralson RH 3rd, Turkelson CM, Wies JL, Raymond L, Anderson S, Boyer K, Sluka P; American Academy of Orthopaedic Surgeons.** Diagnosis and treatment of acute Achilles tendon rupture. *J Am Acad Orthop Surg.* 2010 Aug;18(8):503-10. PubMed PMID: 20675643.
8. **Paavola M, Paakkala T, Kannus P, Järvinen M.** Ultrasonography in the differential diagnosis of Achilles tendon injuries and related disorders. A comparison between pre-operative ultrasonography and surgical findings. *Acta Radiol.* 1998 Nov;39(6):612-9. PubMed PMID: 9817030.
9. **Maffulli N, Longo UG, Maffulli GD, Khanna A, Denaro V.** Achilles tendon ruptures in elite athletes. *Foot Ankle Int.* 2011 Jan;32(1):9-15. doi:10.3113/FAI.2011.0009. PubMed PMID: 21288429.

Submitted May 16, 2018