

**UC Davis**  
**Ophthalmology and Vision Science**

**Title**

Repeatability of Vascular Density Measurements of the Intermediate Retinal Plexus Layer using OCT Angiography

**Permalink**

<https://escholarship.org/uc/item/75k225gp>

**Authors**

Nguyen, Michael

Park, Susanna

**Publication Date**

2021

**Data Availability**

The data associated with this publication are not available for this reason: N/A



# Repeatability of Vascular Density Measurements of the Intermediate Retinal Plexus Layer using OCT Angiography



Michael Nguyen, Susanna Park, M.D., Ph.D.

## Background

OCTA is a non-invasive technique that can image blood flow in the retina and choroid in 3 dimensions. Commercially, the instrument automatically segments the vasculature into 2 separate layers, but histologically, there are 3 different layers of blood vessels. My summer project was focused on determining the reliability and repeatability of the vascular flow density in the intermediate capillary plexus (ICP) layer using OCTA in normal eyes and eyes with cystoid macular edema (CME) and retinal vasculopathy.

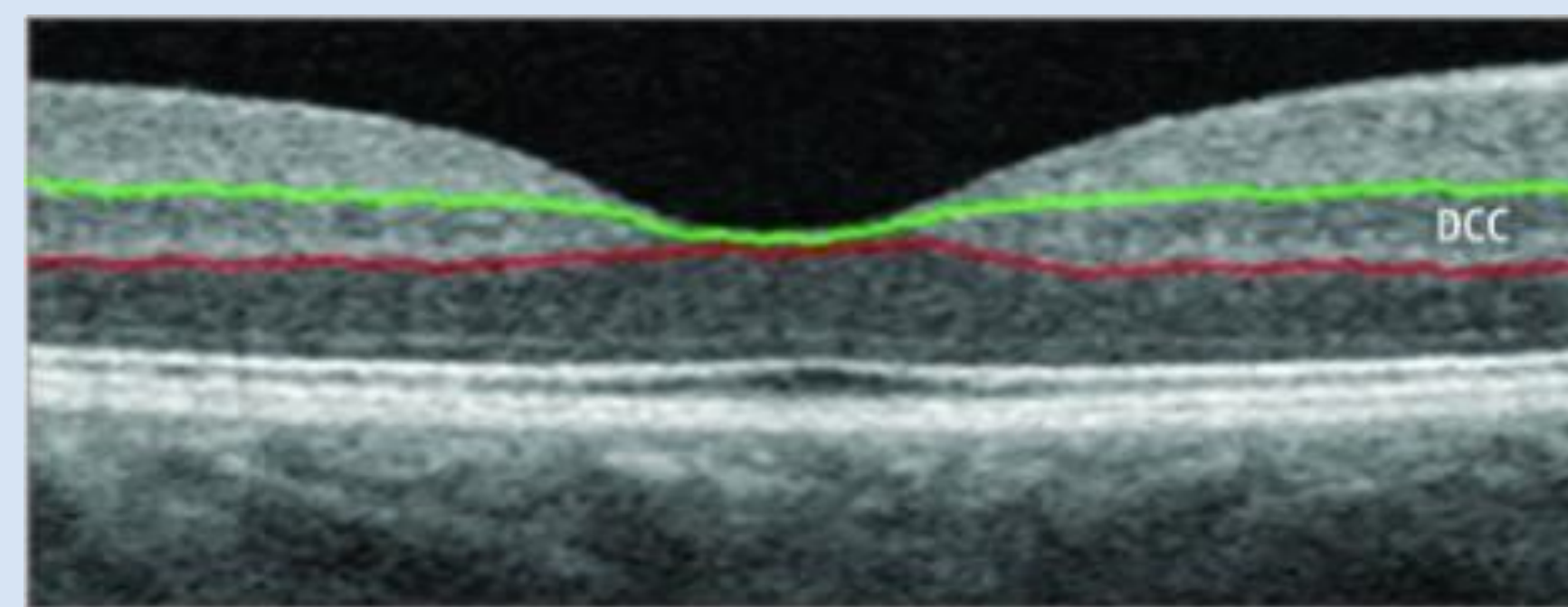
## Methods

86 eyes in 44 patients were imaged with OCTA. The images included a 3x3 mm and a 6x6 mm scan each performed twice by the same personnel using the same machine on the same day. The ICP was obtained through custom segmentation, with manual inputs for layer size and depth. The measurements were then compared to determine the repeatability, presented as the intraclass correlation coefficient (ICC).

## Results

### Automatic Segmentation

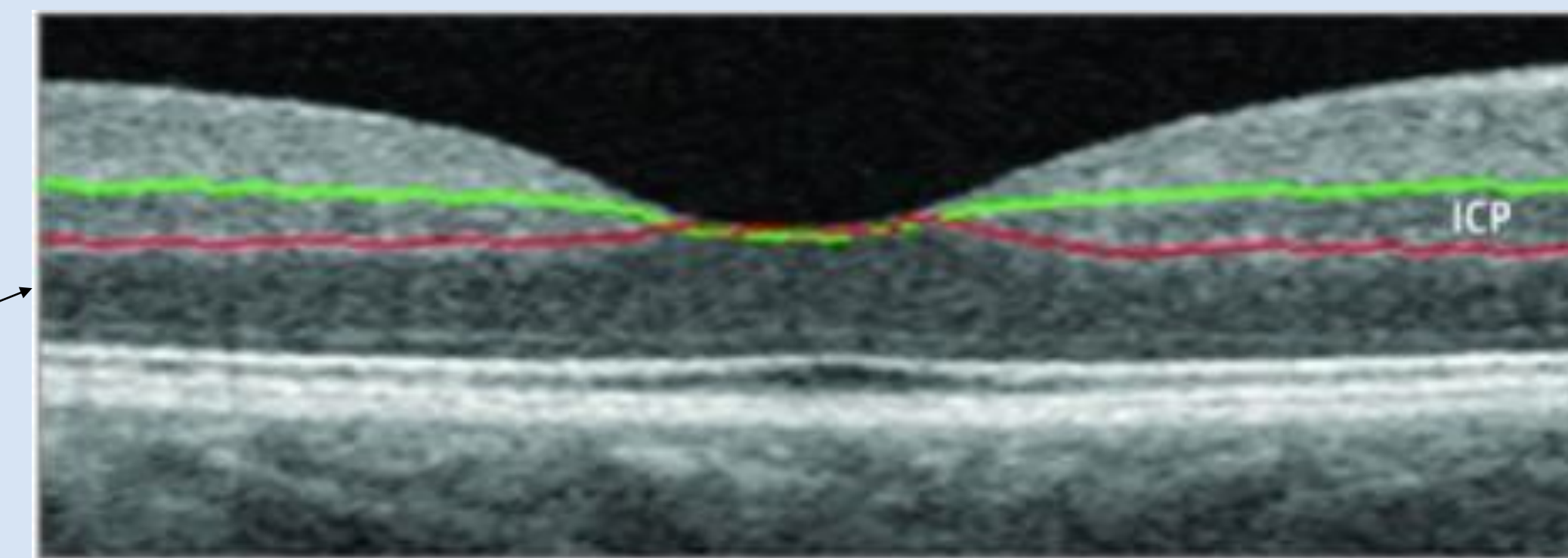
Deep Capillary Plexus



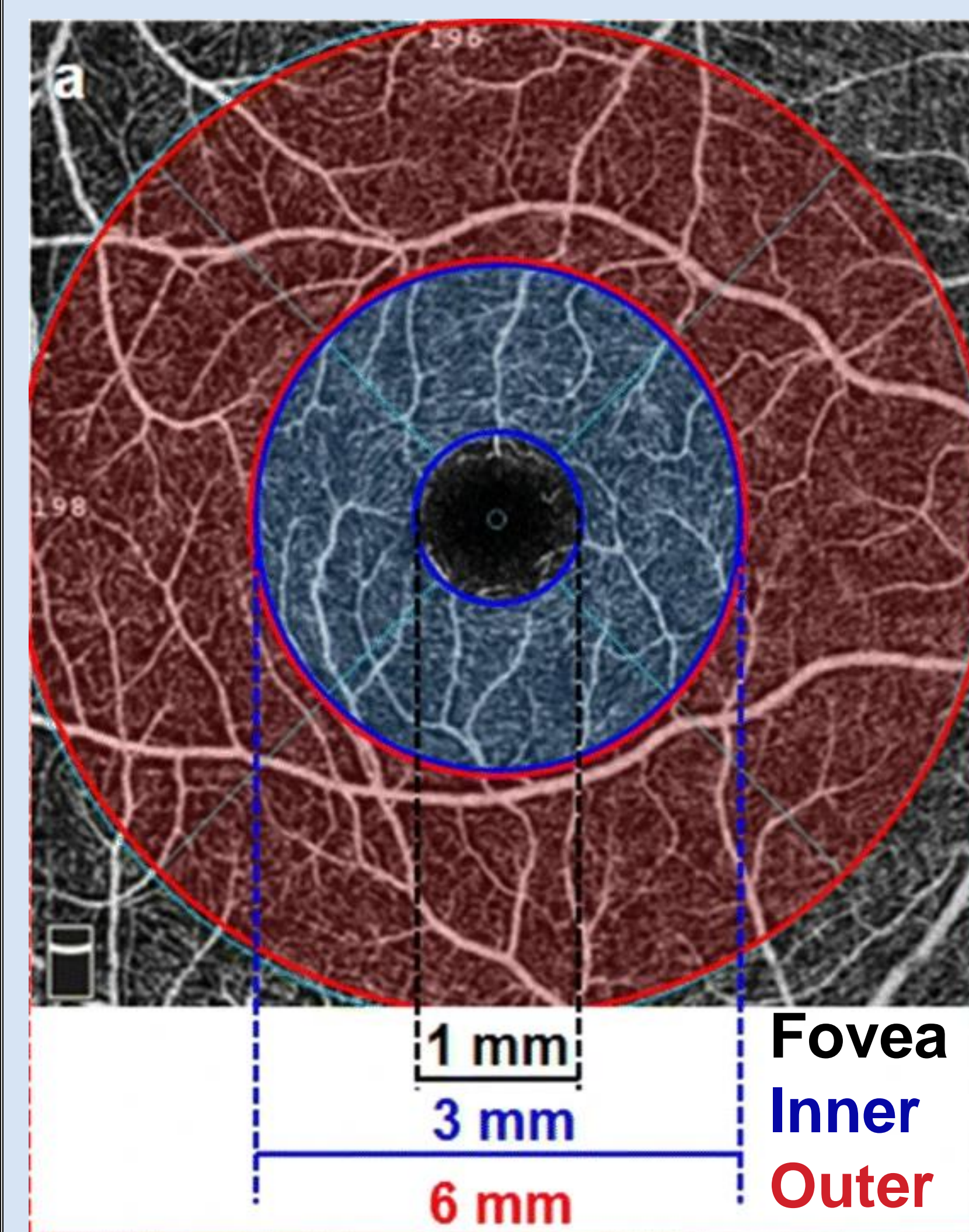
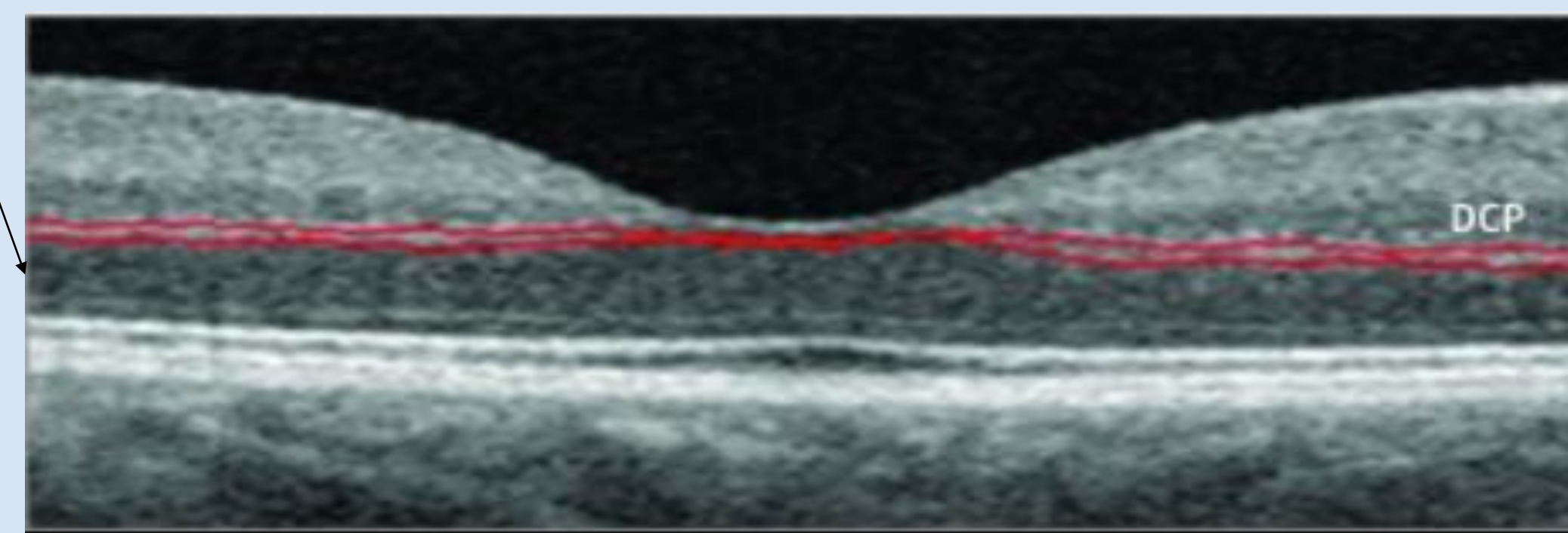
Region	cICP Repeatability	
	3x3mm (n=54)	6x6 mm (n=47)
ETDRS	Moderate	Moderate
Fovea	Good	Moderate
3mm inner ring	Good	Moderate
6mm outer ring	---	Moderate

### Manual Segmentation

(Custom) Intermediate Capillary Plexus



(Custom) Deep Capillary Plexus



3x3mm Pathology	cICP Repeatability		
	No CME	CME	Vasculopathy w/o CME
ETDRS	Good	Moderate	Good
Fovea	Good	Excellent	Good
3mm inner ring	Good	Moderate	Good

6x6mm Pathology	cICP Repeatability		
	No CME	CME	Vasculopathy w/o CME
ETDRS	Poor	Good	Poor
Fovea	Moderate	Poor	Poor
3mm inner ring	Moderate	Poor	Moderate
6mm outer ring	Poor	Good	Excellent

## Conclusions

The repeatability of the vascular density for the custom segmented thinner intermediate layers is reduced in eyes with CME and/or retinal vasculopathy using the larger 6x6 mm OCTA scans. This is likely attributed to the custom segmented ICP being thinner than the automatically segmented layers, thus being more susceptible to errors from morphologic changes seen in the retina associated with CME and retinal vasculopathy. From these findings, we can recommend that using a higher resolution with the smaller 3x3 mm scans yields more reliable results, especially when measuring the vascular density of the ICP in eyes with retinal vasculopathy and/or CME.

## Acknowledgments

Special thanks to Dr. Susanna Park, Dr. Park's team (Dr. Lekha Mukkamala, Dr. Melinda Chang), Mrs. Ann Kohl and the Kohl Scholarship, and the UC Davis Eye Center for the opportunity to conduct research in ophthalmology. This work is included in a paper in press in the journal *Clinical Ophthalmology*.