

# **UCLA**

## **Proceedings of UCLA Health**

### **Title**

TB or Not TB? That is the Question: Thalamic Tuberculoma Mimicking Malignancy

### **Permalink**

<https://escholarship.org/uc/item/7346728b>

### **Journal**

Proceedings of UCLA Health, 26(1)

### **Authors**

Gallardo Huizar, Oscar E.

Lautredou, Cassandra

Cheah, Jenice

et al.

### **Publication Date**

2022-09-15

## CLINICAL VIGNETTE

# TB or Not TB? That is the Question: Thalamic Tuberculoma Mimicking Malignancy

<sup>1</sup>Oscar E. Gallardo Huizar, MD, MSc, <sup>2</sup>Cassandra Lautredou, MD, <sup>3</sup>Jenice Cheah, MD and <sup>4</sup>Caitlin G. Reed, MD

<sup>1</sup>Internal Medicine Department, Olive View Medical Center - University of California Los Angeles, Sylmar, California, USA

<sup>2</sup>Infectious Diseases Division, University of California Los Angeles, California, USA

<sup>3</sup>Internal Medicine Department, University of California Los Angeles, California, USA

<sup>4</sup>Infectious Diseases Division, Olive View Medical Center - University of California Los Angeles, Sylmar, California, USA

### Introduction

Tuberculosis (TB) continues to be a prevalent infectious disease in the world and it affects approximately 10 million people annually, with an estimated 1.4 million TB-related deaths in 2021.<sup>1</sup> Pulmonary disease is usually the most common manifestation of tuberculosis; central nervous system (CNS) tuberculosis disease is rare, difficult to diagnose, and has a high mortality rate.<sup>2</sup> The most common complications of CNS tuberculosis are TB meningitis, tuberculoma, abscess, and spinal tuberculosis.<sup>2</sup> It is estimated that CNS tuberculosis occurs in 1-5% of all TB patients.<sup>3</sup> Risk factors for extrapulmonary TB include HIV/AIDS, immunosuppression, infancy, female sex, alcohol abuse, malignancy, diabetes, and vitamin D deficiency.<sup>4</sup> In the United States, it is estimated that CNS tuberculosis occurs in 4% of patients admitted to the hospital with extrapulmonary TB,<sup>5</sup> and some authors note that clinical CNS TB accounts for about 8% of all extrapulmonary cases.<sup>6</sup> The diagnosis of extrapulmonary tuberculosis is often challenging and regarded as a “medical chameleon”, requiring a high degree of suspicion.<sup>7</sup> We present an otherwise healthy male with neurological symptoms initially suspected to have a brain tumor, found to have a rare manifestation of TB diagnosed through AFB culture of tissue from a brain biopsy.

### Case

A 38-year-old previously healthy man presented with one week of headache, nausea, and vomiting. The patient worked as a cab driver and had moved from Uganda to the United States three years prior. He had no known history of immunosuppression, substance use, residence in a congregate facility, or any known tuberculosis contacts. He was found to have an irregular, lobulated mass within the left basal ganglia with extensive vasogenic edema, midline shift, and obstructive hydrocephalus on magnetic resonance imaging (MRI) (Figures 1 and 2). He was also found to have a small enhancing mass of the left parietal lobe. Further evaluation was notable for a 3mm pulmonary micronodule of the left upper lobe on computed tomography (CT) chest imaging, and lumbar puncture (LP) notable for elevated protein (80 mg/dL) and a glucose of 73 mg/dL, with unremarkable cerebrospinal fluid (CSF) infectious

studies, including negative meningoencephalitis PCR panel, coccidiomycosis, toxoplasmosis, west nile virus, varicella zoster virus, VDRL, acid fast bacilli (AFB), fungal, and bacterial cultures. Serology for HIV-1/2 was negative. The patient underwent a stereotactic brain biopsy with preliminary pathology suggestive of lymphoid tissue, with concern for possible malignancy. He was discharged on a dexamethasone taper with plans to follow up the final pathology review. The brain biopsy was not sent for cultures or PCR.

One month later, he was readmitted to another hospital where he underwent a second brain biopsy because the results of the first biopsy were nondiagnostic. Pathology showed lymphohistiocytic inflammation with granulomas and multinucleated giant cells, necrosis, and gliosis. Bacterial, AFB, and fungal cultures on the brain tissue were negative. TB PCR was not performed on the brain biopsy. Unfortunately, he was lost to follow up after discharge.

Two and a half weeks later, he was readmitted for evaluation after he was found on the floor at home with altered mental status. On exam, he was speaking in a soft, hoarse voice, had poor prospective memory, and could only answer simple questions. Repeat brain MRI demonstrated enlarging lesions and a third brain biopsy was recommended given that the first two biopsies did not establish a definitive diagnosis.

A week after admission, the patient had a fever (38.8 DegC) and elevated lactate (2.6 mmol/L). Infectious workup with urinalysis, blood cultures, and CT scans was only notable for bilateral lower lobe ground glass opacities and mediastinal lymphadenopathy on CT chest. The patient was unable to produce sputum for pulmonary TB evaluation. Repeat lumbar puncture again showed elevated protein (211 mg/dL) and a glucose of 53 mg/dL. Rheumatology and infectious diseases (ID) were consulted regarding the granulomatous inflammation noted on the second biopsy. Differential at the time was most concerning for TB versus CNS sarcoidosis. Given the patient's birth and decades of residence in a TB-endemic country conferring an epidemiologic risk factor for TB infection, and lack of other

findings suggestive of sarcoidosis, the decision was made to start the patient on empiric intensified CNS tuberculosis treatment with rifampin, isoniazid, pyrazinamide, levofloxacin, linezolid, and dexamethasone taper. PET-CT six days later did not demonstrate any lesions or mass concerning for sarcoidosis.

He remained hospitalized while receiving empiric TB treatment. His ability to engage in conversation gradually improved although he still had poor executive function and was unable to fully understand the extent of his medical diagnosis.

## Figures

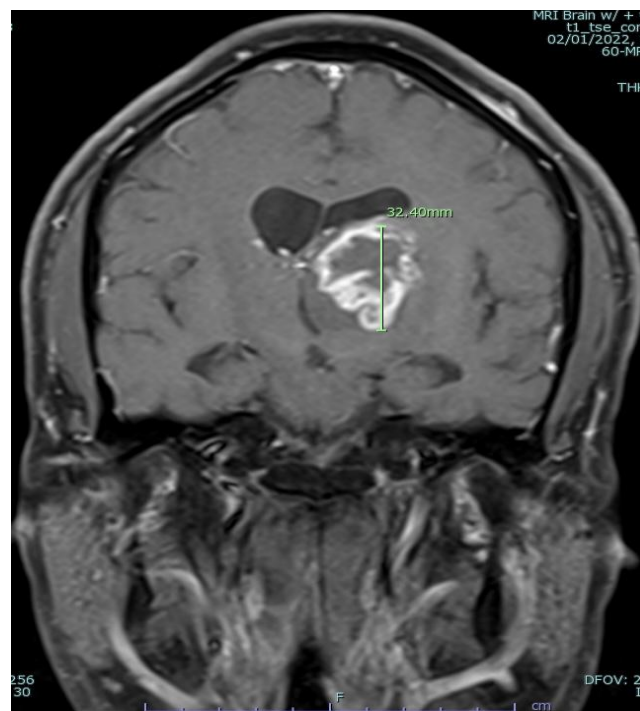
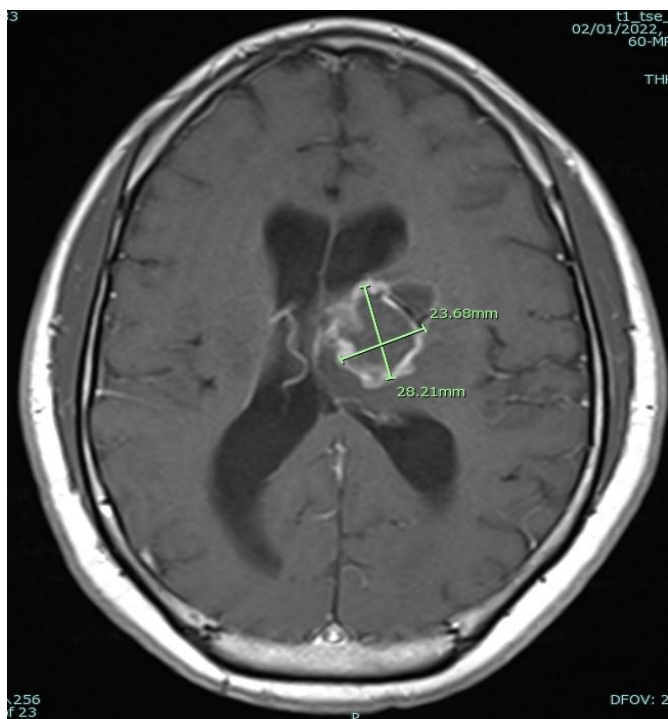


Figure A) (left) and Figure B) (Right) show a left thalamic mass measuring 3.2 cm with internal non-enhancement suggestive of central necrosis.

## Discussion

CNS TB usually begins with small caseous tubercles (also known as Rich Foci) which can form throughout the brain, spinal cord and meninges. These usually rupture and lead to TB meningitis. However, if the tubercles continue to enlarge without rupturing while the infection is contained by a granulomatous reaction, then tuberculomas arise.<sup>8</sup> These space occupying lesions may lead to a myriad of neurologic findings depending on their location. A tuberculous abscess appears similar to a pyogenic brain abscess on imaging, typically being larger than tuberculoma and characterized by cavity formation with central pus.<sup>9</sup> Differential diagnosis of CNS tuberculoma should include neoplasms, Primary Central Nervous System Lymphoma (PCNSL), pyogenic abscess, fungal infection, neurocysticercosis, toxoplasmosis and sarcoidosis.<sup>10</sup>

In this case, the CNS lesion affected the patient's executive function, memory processing, and ability to understand his diagnosis.

## Recommended Treatment

Conservative medical management for CNS TB is effective for most cases and might lead to superior functional recovery.<sup>6,11</sup> It includes a four drug, intensive-phase regimen consisting of isoniazid (INH), rifampin (RIF), pyrazinamide (PZA), and ethambutol (EMB). Surgery is reserved for cases with obstructive hydrocephalus or compression of the brain stem.<sup>12</sup> In general, corticosteroids are recommended in TB meningitis and where mass lesions with cerebral edema produce altered mental status or focal neurologic deficits.<sup>6</sup> After two months of

therapy, for susceptible strains, PZA and EMB can be discontinued. INH and RIF are continued for an additional 7 to 10 months.<sup>13</sup> Some experts substitute another drug for ethambutol because it does not cross the blood-brain barrier. In this case, levofloxacin was substituted for ethambutol and linezolid was added to intensify treatment pending drug susceptibility results.

## REFERENCES

1. Global tuberculosis report 2021. Geneva: World Health Organization; 2021. License: CC BY-NC-SA 3.0 IGO. [Internet] Available at: <https://www.who.int/publications/i/item/9789240037021>.
2. Schaller MA, Wicke F, Foerch C, Weidauer S. Central Nervous System Tuberculosis : Etiology, Clinical Manifestations and Neuroradiological Features. *Clin Neuroradiol*. 2019 Mar;29(1):3-18. doi: 10.1007/s00062-018-0726-9. Epub 2018 Sep 17. PMID: 30225516.
3. Bernaerts A, Vanhoenacker FM, Parizel PM, Van Goethem JW, Van Alena R, Laridon A, De Roeck J, Coeman V, De Schepper AM. Tuberculosis of the central nervous system: overview of neuroradiological findings. *Eur Radiol*. 2003 Aug;13(8):1876-90. doi: 10.1007/s00330-002-1608-7. Epub 2002 Aug 2. PMID: 12942288.
4. Pareek M, Innes J, Sridhar S, Grass L, Connell D, Woltmann G, Wiselka M, Martineau AR, Kon OM, Dedicoat M, Lalvani A. Vitamin D deficiency and TB disease phenotype. *Thorax*. 2015 Dec;70(12):1171-80. doi: 10.1136/thoraxjnl-2014-206617. Epub 2015 Sep 23. PMID: 26400877.
5. Banta JE, Ani C, Bvute KM, Lloren JIC, Darnell TA. Pulmonary vs. extra-pulmonary tuberculosis hospitalizations in the US [1998-2014]. *J Infect Public Health*. 2020 Jan;13(1):131-139. doi: 10.1016/j.jiph.2019.07.001. Epub 2019 Aug 14. PMID: 31422038.
6. Leonard JM. Central Nervous System Tuberculosis. *Microbiol Spectr*. 2017 Mar;5(2). doi: 10.1128/microbiolspec.TNMI7-0044-2017. PMID: 28281443.
7. Suárez I, Fünßer SM, Kröger S, Rademacher J, Fätkenheuer G, Rybníček J. The Diagnosis and Treatment of Tuberculosis. *Dtsch Arztebl Int*. 2019 Oct 25; 116(43):729-735. doi: 10.3238/arztebl.2019.0729. PMID: 31755407.
8. Rock RB, Olin M, Baker CA, Molitor TW, Peterson PK. Central nervous system tuberculosis: pathogenesis and clinical aspects. *Clin Microbiol Rev*. 2008 Apr;21(2):243-61, table of contents. doi: 10.1128/CMR.00042-07. PMID: 18400795; PMCID: PMC2292571.
9. Chakraborti S, Mahadevan A, Govindan A, Nagarathna S, Santosh V, Yasha TC, Devi BI, Chandramouli BA, Kovoov JM, Chandramuki A, Shankar SK. Clinicopathological study of tuberculous brain abscess. *Pathol Res Pract*. 2009;205(12):815-22. doi: 10.1016/j.prp.2009.05.012. Epub 2009 Jul 15. PMID: 19608350.
10. Luthra G, Parihar A, Nath K, Jaiswal S, Prasad KN, Husain N, Husain M, Singh S, Behari S, Gupta RK. Comparative evaluation of fungal, tubercular, and pyogenic brain abscesses with conventional and diffusion MR imaging and proton MR spectroscopy. *AJNR Am J Neuroradiol*. 2007 Aug;28(7):1332-8. doi: 10.3174/ajnr.A0548. PMID: 17698537; PMCID: PMC7977670.
11. Harder E, Al-Kawi MZ, Carney P. Intracranial tuberculoma: conservative management. *Am J Med*. 1983 Apr;74(4):570-6. doi: 10.1016/0002-9343(83)91011-2. PMID: 6837585.
12. Traub M, Colchester AC, Kingsley DP, Swash M. Tuberculosis of the central nervous system. *Q J Med*. 1984 Winter;53(209):81-100. PMID: 6709824.
13. Nahid P, Dorman SE, Alipanah N, Barry PM, Brozek JL, Cattamanchi A, Chaisson LH, Chaisson RE, Daley CL, Grzemska M, Higashi JM, Ho CS, Hopewell PC, Keshavjee SA, Lienhardt C, Menzies R, Merrifield C, Narita M, O'Brien R, Peloquin CA, Raftery A, Saukkonen J, Schaaf HS, Sotgiu G, Starke JR, Migliori GB, Vernon A. Official American Thoracic Society/ Centers for Disease Control and Prevention/Infectious Diseases Society of America Clinical Practice Guidelines: Treatment of Drug-Susceptible Tuberculosis. *Clin Infect Dis*. 2016 Oct 1;63(7):e147-e195. doi: 10.1093/cid/ciw376. Epub 2016 Aug 10. PMID: 27516382; PMCID: PMC6590850.