

# **UCLA**

## **Proceedings of UCLA Health**

### **Title**

Recurrent Pneumonia as a Complication of Coil Endobronchial Lung Volume Reduction for Treatment of Advanced Homogenous Emphysema

### **Permalink**

<https://escholarship.org/uc/item/7331g8tc>

### **Journal**

Proceedings of UCLA Health, 21(1)

### **Authors**

Sheth, Corinne T.

Lee, Elinor

Smith, Malcolm I.

et al.

### **Publication Date**

2017-03-13

## CLINICAL VIGNETTE

# Recurrent Pneumonia as a Complication of Coil Endobronchial Lung Volume Reduction for Treatment of Advanced Homogenous Emphysema

Corinne T. Sheth, M.D., Elinor Lee, M.D., Malcolm I. Smith, M.D., and Scott Oh, DO

### Introduction

Endobronchial lung volume reduction (ELVR) therapy is a novel treatment for severe emphysema. It has been shown to reduce hyperinflation, restore lung elastic recoil, and improve dyspnea and functional capacity and is currently under clinical investigation. We present a complication of PneumRx<sup>®</sup> coil ELVR.

### Case Presentation

An 80-year-old male with 40 pack-year smoking history and severe emphysema (FEV1 of 22% predicted, RV 287% predicted, DLCO 58% predicted) with frequent exacerbations and significant exertional dyspnea (GOLD Class D) underwent bilateral PneumRx<sup>®</sup> coil ELVR in France. He experienced early improvement in his exertional dyspnea and functional capacity but then presented with subjective fevers, productive cough, and hypoxemia.

Immediately on return from France one month after bilateral PneumRx<sup>®</sup> coil ELVR our patient presented with exacerbation of chronic obstructive pulmonary disease (COPD) and severe sepsis from coil associated lung abscess. He was afebrile with a blood pressure of 93/51, respiratory rate of 40 breaths per minute, and heart rate of 99 beats per minute. Physical exam was significant for diffusely decreased breath sounds and a prolonged expiratory phase. Chest computed tomography (CT) scan demonstrated severe centrilobular emphysema now with numerous endobronchial coils placed for volume reduction and several pseudocavitations, some with air fluid levels associated with the coils (Images 1 and 2). No other airspace consolidation was identified. Respiratory culture was positive for *Pseudomonas aeruginosa*. He underwent a 6-week course of antibiotics for endobronchial coil associated lung abscess. He had clinical and radiographic improvement. However, approximately every two months following, he developed a recurrent COPD exacerbation and *Pseudomonas aeruginosa* pneumonia though without further cavitation or abscess formation. These episodes often required hospitalization and varying courses of intravenous antibiotics, oral corticosteroid and supplemental oxygen. Over the following year, he had progressive respiratory and functional decline. He entered hospice care and died approximately 16 months after undergoing coil ELVR.

### Discussion

According to the Center for Disease Control, COPD was the third leading cause of death in the United States in 2014 with 6.4% of Americans report having been diagnosed with COPD and many more unaware that they have COPD.<sup>1</sup> Patients with advanced emphysema suffer from dyspnea due to static and dynamic hyperinflation from decreasing elastic recoil of the lungs, airway collapse, and increase in expiratory flow resistance. Despite medical management with bronchodilators, anti-inflammatory drugs, proper nutrition, rehabilitation, and supplemental oxygen, many patients still have symptomatic dyspnea and frequent exacerbations.<sup>2</sup> Further options of lung volume reduction surgery (LVRS) and lung transplantation are only available to a small subset of patients. Recent studies have investigated ELVR as an effective method to reduce hyperinflation, restore lung elastic recoil, and improve dyspnea and functional capacity that is available to a wider subset of patients.<sup>2,3</sup>

The goal of LVRS is to remove emphysematous lung to improve hyperinflation, diaphragm mobility, and expiratory flow. Indications for LVRS are based on the NETT trial.<sup>4</sup> Patient must be age less than 75 years, FEV1 20-45% predicted, DLCO >20% predicted, predominantly upper lung zone emphysema, and low post-rehabilitation exercise capacity. The NETT trial concluded that LVRS increases the chance of improved exercise capacity and yields a survival advantage over medical therapy for these patients. Patients outside of this cohort had increased mortality and negligible functional gain.<sup>4</sup>

Patients with end stage COPD should be evaluated for lung transplant candidacy if they are less than 65 years old with an FEV1 less than 25% of predicted with preference given to patients with elevated PaCO<sub>2</sub>, progressive deterioration, and requiring long term oxygen therapy.<sup>5</sup>

The availability and use of LVRS and lung transplant are very limited by a combination of strict patient selection criteria, associated morbidity and mortality, in addition to a shortage of donor organs. The operative mortality associated with LVRS in the NETT trial was estimated to be about 6%. Given the operative risk ELVR has been developed and studied as a minimally invasive procedure with reduced morbidity and mortality available to a wider subset of patients. There are many methods being studied including valves, biologic and synthetic

suspensions causing atelectasis, thermal vapor ablation, and coils.<sup>6</sup>

One way endobronchial valves have been the most widely investigated technique. However, successful therapy with endobronchial valves is limited to patients without interlobular collateral ventilation. Collateral ventilation is thought to occur to a greater extent in homogenous emphysema than in heterogenous disease and patients with upper lobe predominant disease tend to fare better with ELVR.<sup>6</sup>

Patients with advanced homogenous emphysema or presence of interlobular collateral ventilation have very limited treatment options. These include lung transplant if they meet the strict eligibility criteria or palliative support.<sup>7</sup>

Shape-memory nitinol coils are nonblocking devices bronchoscopically placed into subsegmental airways to induce regional parenchymal volume reduction, enhance lung recoil, and reestablish small airway tethering.<sup>8</sup> Endobronchial coils have been tested in patients with both heterogenous and homogenous emphysema with or without complete interlobular fissures. Many investigations are underway to determine if these are a valid option for this group of patients with very limited treatment options.

A prospective open label multicenter feasibility study included patients with COPD with upper or lower lobe predominant bilateral heterogeneous emphysema on chest CT scan with FEV<sub>1</sub> <45% of predicted and RV>175% of predicted. Sixty patients were bronchoscopically treated with coils with a median of ten coils per lobe. Complications within the first month were low but included COPD exacerbation (6.1%), pneumonia (5.2%), pneumothoraces (3.5%), and hemoptysis (0.9%). There were significant and sustained improvements over twelve months in relevant clinical and functional parameters of FEV<sub>1</sub>, RV, 6MWD and SGRQ.<sup>3</sup> Several small clinical trials report similar findings that coils may improve quality of life and exercise tolerance.<sup>2,3</sup>

More recently the larger RENEW randomized clinical trial was conducted to assess one-year effectiveness and safety of endobronchial coils. It again looked at a group of patients with advanced predominantly homogenous emphysema who have few treatment options. 157 patients underwent usual care alone including pulmonary rehabilitation and bronchodilators. 158 patients underwent usual care plus bilateral coil treatment. Mean between group differences were +21 meters in six-minute walk distance favoring the coil group, which is of uncertain clinical importance; +0.08L in expiratory flow rate favoring the coil group at 12 months, which is a less than clinically important difference; and -8.9 SGRQ score favoring coils, which is an overall clinically important improvement in quality of life. These modest improvements of uncertain clinical importance were also associated with a higher rate of pneumonia (20% coil vs 4.5% usual care) and pneumothorax (9.7% coil vs 0.6% usual care). In total, major complications including pneumonia requiring hospitalization and other potentially life threatening or fatal events occurred in 34.8% of coil participants vs 19.1% of usual care. The conclusion was that coils compared to usual care resulted in an improvement in median exercise tolerance that was modest and of uncertain clinical importance with a

higher likelihood of major complications and that follow-up is needed to assess long-term effects on health outcomes.<sup>7</sup> Additionally, the REVOLENS randomized clinical trial evaluated the cost effectiveness of coils in treatment of severe emphysema and concluded that coils vs usual care resulted in improved exercise capacity though with high short-term costs.<sup>8</sup>

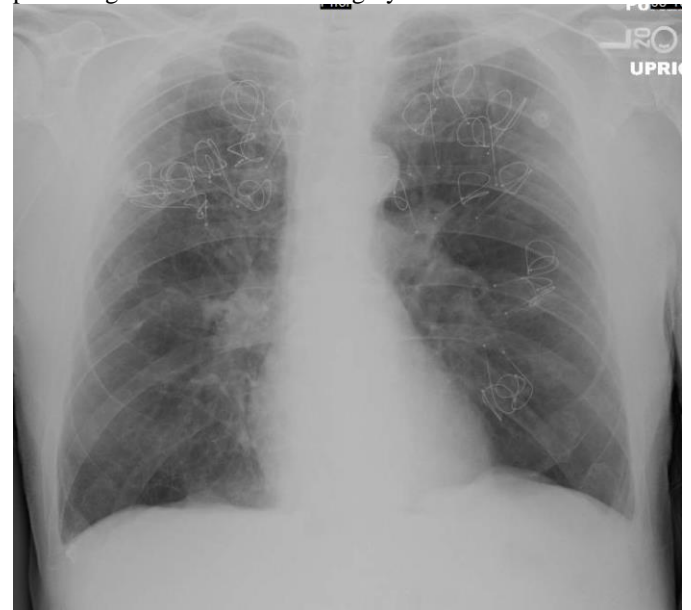Our patient certainly fell into this cohort of advanced homogenous emphysema with limited treatment options other than transitioning to palliative support. Following coil ELVR therapy, he subjectively reported that his quality of life and functional status did improve. He declined post-therapy objective measurements of lung function and six-minute walk testing. However, his case was associated with coil associated abscess, pneumonia, and COPD exacerbations. His initial coil associated *Pseudomonas aeruginosa* abscesses clinically and radiographically resolved with a prolonged six-week course of intravenous antibiotics. Although he did not have further evidence of associated lung abscesses, the *P. aeruginosa* was not eradicated; he went on to have recurrent *P. aeruginosa* pneumonias, COPD exacerbations, and eventual functional decline. Our patient did state that he felt like the coil ELVR therapy was a positive experience for him. In the periods not afflicted by pneumonia or COPD exacerbation, he often stated that he could feel his diaphragm moving again and felt his breathing was better.

## Conclusion

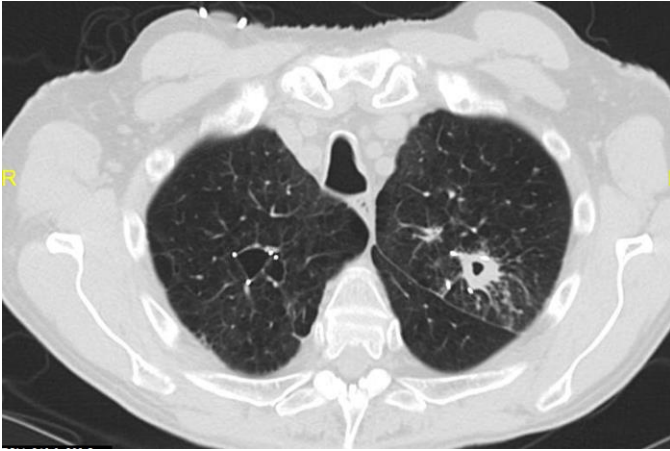
More research needs to be done in this group of patients with advanced homogenous emphysema with essentially only palliative support as a treatment option. While endobronchial coil therapy seems to have modest improvements in relative functional parameters, the high incidence of serious complications warrants further investigation into methods to mitigate risks and maximize benefits.

## Images


**Image 1.** Chest xray demonstrating bilateral emphysematous changes with numerous coils throughout the lungs related to prior lung volume reduction surgery.



**Image 2.** Chest CT scan demonstrating bilateral emphysematous changes with numerous endobronchial coils placed for volume reduction with several pseudocavitations.



**Image 3.** PneumRx® coil



## REFERENCES

1. CDC.gov/copd.
2. **Slebos DJ, Klooster K, Ernst A, Herth FJ, Kerstjens HA.** Bronchoscopic lung volume reduction coil treatment of patients with severe heterogeneous emphysema. *Chest*. 2012 Sep;142(3):574-82. PubMed PMID: 22116796.
3. **Deslee G, Klooster K, Hetzel M, Stanzel F, Kessler R, Marquette CH, Witt C, Blaas S, Gesierich W, Herth FJ, Hetzel J, van Rikxoort EM, Slebos DJ.** Lung volume reduction coil treatment for patients with severe emphysema: a European multicentre trial. *Thorax*. 2014 Nov;69(11):980-6. doi:10.1136/thoraxjnl-2014-205221. PubMed PMID: 24891327; PubMed Central PMCID:PMC4215297.
4. **Fishman A, Martinez F, Naunheim K, Piantadosi S, Wise R, Ries A, Weinmann G, Wood DE; National Emphysema Treatment Trial Research Group.** A randomized trial comparing lung-volume-reduction surgery with medical therapy for severe emphysema. *N Engl J Med*. 2003 May 22;348(21):2059-73. PubMed PMID: 12759479.
5. International guidelines for the selection of lung transplant candidates. The American Society for Transplant Physicians (ASTP)/American Thoracic Society(ATS)/European Respiratory Society(ERS)/International Society for Heart and Lung

Transplantation(ISHLT). *Am J Respir Crit Care Med*. 1998 Jul;158(1):335-9. PubMed PMID: 9655748.

6. **Lee HJ, Shojaee S, Sterman DH.** Endoscopic lung volume reduction. An American perspective. *Ann Am Thorac Soc*. 2013 Dec;10(6):667-79. doi: 10.1513/AnnalsATS.201306-145FR. Review. PubMed PMID: 24364771.
7. **Sciurba FC, Criner GJ, Strange C, Shah PL, Michaud G, Connolly TA, Deslée G, Tillis WP, Delage A, Marquette CH, Krishna G, Kalhan R, Ferguson JS, Jantz M, Maldonado F, McKenna R, Majid A, Rai N, Gay S, Dransfield MT, Angel L, Maxfield R, Herth FJ, Wahidi MM, Mehta A, Slebos DJ; RENEW Study Research Group.** Effect of Endobronchial Coils vs Usual Care on Exercise Tolerance in Patients With Severe Emphysema: The RENEW Randomized Clinical Trial. *JAMA*. 2016 May 24-31;315(20):2178-89. doi: 10.1001/jama.2016.6261. PubMed PMID: 27179849.
8. **Deslée G, Mal H, Dutau H, Bourdin A, Vergnon JM, Pison C, Kessler R, Jounieaux V, Thiberville L, Leroy S, Marceau A, Laroumagne S, Mallet JP, Dukic S, Barbe C, Bulsei J, Jolly D, Durand-Zaleski I, Marquette CH; REVOLENS Study Group.** Lung Volume Reduction Coil Treatment vs Usual Care in Patients With Severe Emphysema: The REVOLENS Randomized Clinical Trial. *JAMA*. 2016 Jan 12;315(2):175-84. doi:10.1001/jama.2015.17821. PubMed PMID: 26757466.

Submitted March 13, 2017